

Three-dimensional color Doppler ultrasonography of the kidney vasculature in normal dogs

Molazem, M.; Vajhi, A. *; Masoudifard, M. And Soroori, S.

Department of Clinical Sciences, Faculty of Veterinary Medicine, University of Tehran, Tehran, Iran.

Key Words:

three-dimensional; ultrasonography; color Doppler; kidney; dog.

Correspondence

Vajhi, A.,
Department of Clinical Sciences, Faculty of Veterinary Medicine, University of Tehran, P.O. Box: 14155-6453, Tehran, Iran.
Tel: +98(21)61117000
Fax: +98(21)66933222
E-mail: avajhi@ut.ac.ir

Received 26 January 2009,
Accepted 1 July 2009

Abstract

Three-dimensional color Doppler ultrasonography is a new technique to evaluate the pattern of blood vessels. This study was performed to assess the feasibility of this method in evaluation of kidney vasculature pattern in dogs. In this paper, visualization of the Renal, Interlobar, Arcuate, and interlobular arteries and veins using 3D color Doppler ultrasonography in dogs is shown and the technique is described. To our knowledge, this is the first clinical protocol in which 3D color Doppler ultrasonography was used for kidney in veterinary practice and seems to have the potential to provide greater detail of the vascularity associated with abnormal lesion.

Introduction

Conventional radiography merges three-dimensional (3D) data into two-dimensional (2D) summation images. Radiologists mentally reverse this process by forming 3D impressions of the underlying anatomy and disease. Tomographic data from ultrasonography (US) have made this mental reformatting process easier and more accurate. Recent advances in computer technology and display techniques promise to make medical imaging data even more accessible and clinically useful. Real-time 3D display, reformatting, and manipulation of US are now possible on desktop computers (Downey *et al.*, 2000). One of the 3D US forms of display is 3D color Doppler angiography which provides a novel tool to study blood flow to a whole tissue or organ and subjectively assess vessel pattern and distribution. The color Doppler signal may also be quantified to give objective information about blood flow. The basics of this technique are the same as that of the 2D color Doppler US; there are multiple sample volumes within a circumscribed region shown as a color box on the B-mode tomogram and by stacking up the acquired images, they can be displayed in 3D color flow information superimposed within the surrounding tissue. By convention, flow towards the transducer is red; flow away from the transducer is blue. Differentiation between slow and fast flow is also possible. A major advantage of 3D color Doppler US is that not only the flow in a selected vessel can be detected (like with angiography), but also the vessels' anatomic pattern and their relations to the abdominal organs and to other

vessels can be appreciated without any invasiveness.

Although there are a few studies on the potential applications in veterinary practice but it seems to be numerous in near future. Recent publications have shown its increasing usage in human medicine (Pairleitner *et al.*, 1999; Pan *et al.*, 2003; Cohen *et al.*, 2001; Kupesic *et al.*, 2000 and Ohishi *et al.*, 1998). In some diagnostic and treating indications such as kidney transplantation, kidney tumors, ischemic nephropathy, post traumatic examination, assessing potential invasion by mass lesions, analysis of vascular anatomy, the potential investigation of organ perfusion, and to determine involvement in thromboembolic disease, it would be necessary to provide detailed characterization of the renal vasculature (Nyland *et al.*, 2000; Hirai *et al.*, 1998; Ritchie *et al.*, 1996; Pickering, 1991; Parfrey *et al.*, 1989 and Huber *et al.*, 2003). Although contrast angiography remains the gold standard, because of its invasiveness and attendant risks, it is not an appropriate screening test for all patients thought to have renovascular problems (Mailloux *et al.*, 1994; Bech *et al.*, 1975).

The purpose of this study was to assess the feasibility of 3D color Doppler US in evaluation of kidney vasculature pattern in dogs as a safe technique in renal angiography.

Materials and Methods

A total of 12 clinically (examined by an expert internist) and paraclinically (underwent entire blood work) normal German shepherd dogs (6 male and 6 female), weighing 18-22 kg, underwent 3D color

Doppler US imaging of the kidney vasculature with a GE Voluson 730 Pro, (GE Kretz, Zipf, Austria) ultrasonography machine with a mechanical tilt scanning 5-12 MHz linear trapezoid array 3D transducer. The dogs were fasted for 12 hours prior to the starting of the study to avoid interference from overlying bowel gas. A protocol was established for the ultrasonographic examination of each kidney in the dog. The animal was placed in dorsal recumbency. All the abdominal hair was clipped ventral to the sublumbar muscle and over the last two intercostal spaces. The skin was prepared by cleaning and plenty of acoustic coupling gel. All the cases were induced to general anesthesia by using Acepromazine (0.01 mg/kg, IM) and Ketamin hydrochloride (10 mg/kg, IM) and then intubated to respiratory ventilator apparatus on 0.5–1% Isoflurane for maintenance to avoid respiratory motion by artificial apnea during 3D scanning (maximum 40 second during each scan).

The kidney was found longitudinally by 2D scan initially, lying superficially in each case just beneath the abdominal wall. To obtain good quality 3D color Doppler images, the PRF (Pulse-Repetition Frequency) was first adjusted by setting it sufficiently high to prevent an aliasing artifact and low to ensure that a slow flow would not be misinterpreted as absence of flow. However, it was inevitable that relatively small vessels would be missed. During the examination, color Doppler and gray scale images were alternatively obtained by regularly switching the color overlay on and off.

Image acquisition was then performed as a volume of data with nearly immediate reconstruction and simultaneous display of sectional anatomy in three orthogonal planes (sagittal plane, transverse, and coronal plane) or any arbitrary oblique plane and also finally a 360 degree rotating 3D plane (figure 1). The 3D color Doppler US image acquisition and reconstruction required less than three minutes and ultimately it could be performed in "Sectional Planes" which allows viewing and parallel movement through the image slices, the "Niche Mode" which allows the viewing of 3 orthogonal planes in a stereoscopic view, "360 degree 3D rotation cine", which is an animated rotation of the rendering of a static 3D volume around the x, y, or z axis or any other chosen angles, and "4D Real Time" which is created by the volumes captured, stored and exported during acquisition and contains a series of 3D volumes, one acquired after the other, and shown as a "movie".

Images were evaluated for gross anatomical visualization and character of the Renal, Interlobar, Arcuate, and Interlobular arteries (Aa) and veins (Vv).

Results

Satisfactory visualization of the Renal, Interlobar, Arcuate, and interlobular Aa and Vv using 3D color Doppler US could be achieved and reconstructed in one

volume sample in normal kidneys. By using the linear array trapezoid 3D transducer the following adjustments were almost optimal in all cases:

- **In 2D:** Frequency: Penetrate (3-10.5 MHz), Focus Depth: 3, Beta View: 0 degree, Power: 11, Gain: 8, Scan Filed: trapezoid, Quality: normal, Line Filter: low, Enhance: 5, Dynamic Control: 4, Persistence Filter: 3, Reject: 0.
- **In Color:** Quality: normal, Gain: 0.4, Frequency: middle, Wall Motion Filter: Low 2, Power: 0.6, PRF: 1.3, Line filter: 5, Baseline: 1, Ensemble: 18, Line density: 7, Smoothing rise: 3, Smoothing fall: 12, Dynamic set: 8, Balance: 55.
- **In 3D:** Visualization: 3D rendering, 3D Color flow mode (CFM) program: Glass body, Quality: high1, Volume angel: 29.

The best 3D color Doppler US scan of the kidney corresponding to the sagittal, dorsal, and transverse planes was found to be while the beta view angle was based on "longitudinal" section in dorsal recumbency as a starting point. The 3D color Doppler US images in the "Sectional Plane", the "Niche Mode", and "360 degree 3D rotation cine" are shown in figures 1-3.

By choosing 0.6 (kHz) for the PRF the 3D color Doppler US was not able to discriminate Interlobular and Arcuate Aa and Vv completely, but it was perfect for Renal and Interlobar ones (Fig. 4). In contrast using 0.3 (kHz) for the PRF was good for detecting the Interlobular and Arcuate Aa and Vv but Renal and Interlobar were missed or in aliasing artifact and the noises of the final image were increased (Fig. 5).

Discussion and Conclusion

An ideal noninvasive renal artery imaging study would be accurate enough to delineate renal vasculature anatomic pattern. Other attributes of the ideal imaging technique are minimal expense, good reproducibility, and low complication rate. Definitive diagnosis of renal artery pathology depends on visualization of renal artery anatomy with angiographic techniques (Bernheim *et al.*, 2005). Nowadays many technological advances have been established in evaluation of the renal vessels, including Magnetic Resonance Angiography, Duplex US, Helical (Spiral) Computed Tomography.

Two-dimensional color Doppler ultrasonography is one of these imaging modalities that has been most intensively investigated. It has been used in various studies for investigating renal haemodynamic physiology in medical science and in the dog (Abildgaard *et al.*, 1997; Brown *et al.*, 1997 and Reid *et al.*, 1980). Clinical uses of color Doppler include the evaluation of the haemodynamic effects of pharmacological agents, toxicity and renal failure in native kidneys, acute renal allograft rejection, evaluation of perfusion abnormalities, renal artery

Figure 1: "Sectional Planes" of the vessels in dog's kidney using 0.6 (kHz) for the PRF.

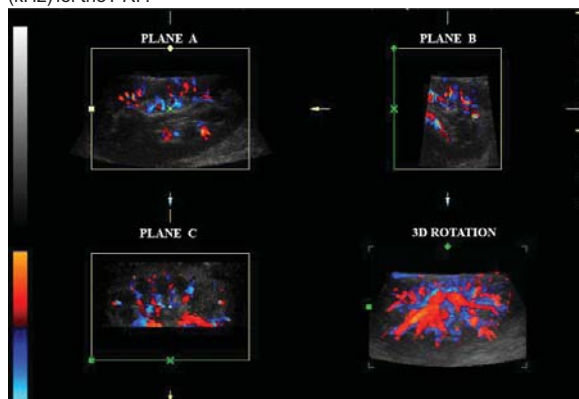


Figure 2: The "Niche Mode" of the vessels in dog's kidney using 0.6 (kHz) for the PRF [Note that the arterial flow is away from the transducer (blue colored) while venous flow is toward the transducer (red colored)].

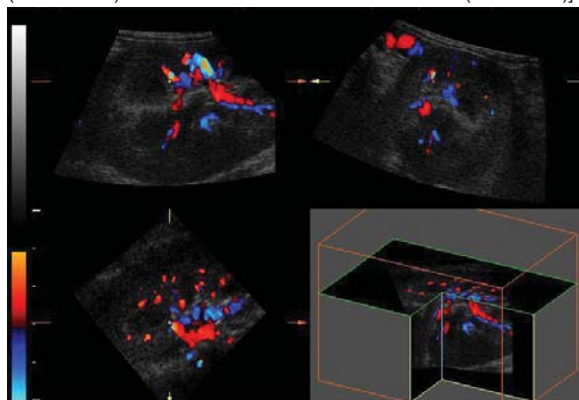
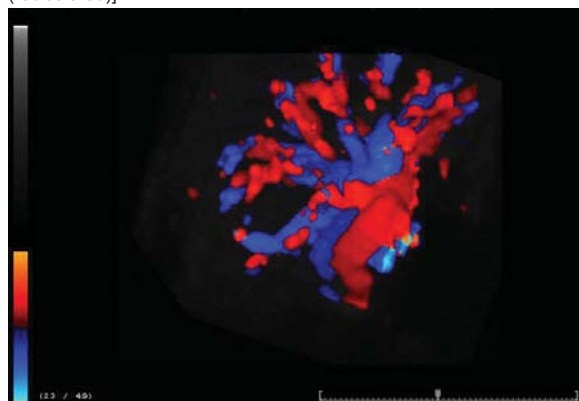


Figure 3: "360 degree 3D rotation cine", of the vessels in dog's kidney using 0.6 (kHz) for the PRF [Note that the arterial flow is away from the transducer (blue colored) while venous flow is toward the transducer (red colored)].



stenosis, renal vein thrombosis, pseudoaneurysms, and arteriovenous fistulas (Reid *et al.*, 1999; Sehgal *et al.*, 2001; Daley *et al.*, 1994 and Takahashi *et al.*, 1999). Color and power Doppler are also helpful in the

Figure 4: 3D color Doppler image of Renal and Interlobar Aa and Vv in dog's kidney using 0.6 (kHz) for the PRF [Note that the arterial flow is away from the transducer (blue colored) while venous flow is toward the transducer (red colored)].

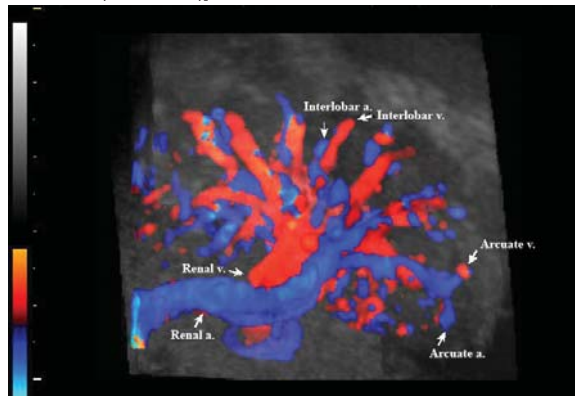
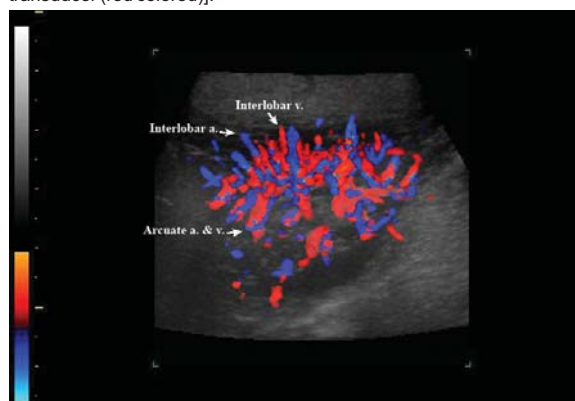

Figure 5: 3D color Doppler image of Interlobular and Arcuate Aa and Vv in dog's kidney using 0.3 (kHz) for the PRF [Note that arterial flow is away from the transducer (blue colored) while venous flow is toward the transducer (red colored)].



evaluation of the transplanted kidney and can suggest the presence of transplant rejection. Knowledge of these sonographic features will enable prompt diagnosis, thereby expediting patient care (Rivolta *et al.*, 1999; Chen *et al.*, 1998).

However, to our knowledge, this is the first clinical protocol in which 3D color Doppler US was used for kidney and seems to have the potential to provide greater details of the vascularity because conventional color Doppler US has several disadvantages that 3D color Doppler US has the potential to rectify. One of its major disadvantages is operator dependency in data acquisition. The operator sweeps the US beam back and forth across the kidney many times while mentally integrating multiple 2D images into a 3D impression of the underlying vessel anatomy and disease. This process is universally acknowledged as time-consuming and inefficient, and there is considerable interobserver variability. In contrast, 3D color Doppler images can be reconstructed from data obtained with a

single sweep of the US beam across the kidney. Both the US information and the relative position of each tomographic section are accurately recorded. As a result, the exact relationships among the vessels are accurately recorded in the 3D images.

Another disadvantage of conventional color Doppler US is the limited viewing perspective it allows. Sometimes, the patient's anatomy or position makes it impossible to orient the US transducer for optimal visualization of a particular vessel. Three-dimensional color Doppler US allows unrestricted access to an infinite number of viewing planes. In addition, 2D color Doppler US is ill suited for monitoring the effects of therapy over a long period of time because it is difficult to localize the 2D image plane, and to find the same location again at a later time.

To minimize artifacts, 2D images are usually acquired with nonstandard patient positioning during various phases of respiration. To accurately assess the long-term effects of treatment during follow-up, the ideal would be to replicate the US images that best demonstrated the abnormality. Although it is usually possible to approximate an earlier image, one can never be sure if the changes on a subsequent image are substantive or merely reflect slight differences in imaging technique. Three-dimensional color Doppler US allows comparison of two full data sets over time, thereby improving accuracy of evaluation.

Furthermore, with 2D scan, a "flat" anatomic section is displayed on a video monitor or on film. With 3D color Doppler US different viewing algorithms allow the data to be displayed with a variety of techniques, including color or glass body rendering by color surface or color transparent mode. Finally, if it is necessary, quantitative volume estimates made at 2D images are often based on images that are approximately orthogonal to each other, which may lead to inaccurate and variable results whereas in 3D US it has been shown to provide a more accurate and repeatable method of evaluating anatomic structures and disease entities (Spaulding, 1997; Elliot *et al.*, 1996 and Tong *et al.*, 1998).

Besides the advantages, there are some disadvantages too; including that analyzing of 3D US acquired data are more complicated than the conventional US. Also the assemblies in 3D transducers are typically bigger than 2D ones and therefore more difficult for the user to manipulate. The larger data sets produced with 3D US also make data archiving and communication more challenging.

Computer capacity and speed is also another difficulty; some produce images almost instantaneously, whereas others require several seconds to produce an onscreen image. The ability to view data with a variety of algorithms and from different perspectives may slow the image interpretation process. Inexperienced users may have

to spend extra time finding the best algorithm and perspective for viewing the data. Many of the viewing programs require a considerable amount of image manipulation to obtain high-quality results.

In conclusion, our experience shows that 3D color Doppler ultrasonography of the kidney vasculature is feasible. The ability to assess previously unattainable scan planes and 3D orthogonal projections is particularly valuable for imaging of the kidney vasculature anatomy but in the absence of tissue detail the exact relationship of vessels to greyscale abnormality can only, at best, be approximated. Transparent 3D blocks of greyscale information combined with color Doppler vascular information still do not overcome the problem of difficulty in appreciating the greyscale abnormality due to the heterogeneity of echo pattern of surrounding kidney tissue in most cases. However, three orthogonal planes (Sectional Planes) 3D image-processing permits to analyze the grayscale ultrasound data in 2D view too. In all investigations of noninvasive modalities, contrast angiography would be used as a standard comparison. Although in the present study the mentioned standard was not used, the authors realize that this technique may worth because of the 3D capabilities. Further studies will be required to assess the exact role and capability of this new technique for the evaluation of kidney disorders in dogs.

References

1. Abildgaard, A.; Klow, N.E. and Jacobsen, J.A. (1997) Effect of ultrasound contrast medium in colour Doppler and power Doppler visualisation of blood flow in canine kidneys. *Acta Radiologica*. 38: 445-453.
2. Arger, P.H.; Sehgal, C.M. and Pugh, C.R. (1999) Evaluation of change in blood flow by contrast-enhanced power Doppler imaging during norepinephrine-induced renal vasoconstriction. *J. Ultrasound Med*. 18: 843-851.
3. Bech, K.; Hilden, T. (1975) The frequency of secondary hypertension. *Acta Med. Scand*. 195: 65-79.
4. Bernheim, J.W.; Kent, K.C. (2005) Renal Artery Imaging and Physiologic Testing. In: Rutherford RB. *Vascular Surgery e-dition*, 6th edition. Philadelphia, WB Saunders. pp: 1773-1788.
5. Brown, J.M.; Quedens-Case, C. and Alderman, J.L. (1997) Contrast enhanced sonography of visceral perfusion defects in dogs. *J. Ultrasound Med*. 16: 493-499.
6. Chen, P.; Maklad, N. and Redwine, M. (1998) Color and power Doppler imaging of the kidneys. *World J Urol*. 16: 41-45.
7. Cohen, L.S.; Escobar, P.F. and Scharm, C. (2001) Three-dimensional power Doppler ultrasound improves the diagnostic accuracy for ovarian cancer prediction. *Gynecol Oncol*. 82: 40-48.
8. Daley, C.A.; Finn-Bodner, S.T. and Lenz, S.D. (1994)

- Contrast-induced renal failure documented by colour Doppler imaging in a dog. *J. Am. Anim. Hos. Ass.* 30: 33-37.
9. Downey, D.B.; Fenster, A. and Williams, J.C. (2000) Clinical Utility of Three-dimensional US. *Radiographics.* 20: 559-571.
 10. Elliot, T.L.; Downey, D.B. and Tong, S. (1996) Accuracy of prostate volume measurements in vitro using three-dimensional ultrasound. *Acad Radiol.* 3: 401-406.
 11. Hirai, T.; Ohishi, H. and Yamada, R. (1998) Three-dimensional power Doppler sonography of tumor vascularity. *Radiat Med.* 16: 353-357.
 12. Huber, W.; Schipek, C. and Ilgmann, K. (2003) Effectiveness of theophylline prophylaxis of renal impairment after coronary angiography in patient with chronic renal insufficiency. *Am. J. Cardiol.* 91: 1157-1162.
 13. Kupesic, S.; Kurjak, A. (2000) Contrast-enhanced, three-dimensional power Doppler sonography for differentiation of adnexal masses. *Obstet. Gynecol.* 96: 452-458.
 14. Mailloux, L.U.; Napolitano, B. and Bellucci, A.G. (1994) Renal vascular disease causing end-stage renal disease, incidence, clinical correlate, and outcomes: A 20-year clinical experience. *Am. J. kidney Dis.* 24: 622-629.
 15. Nyland, T.G.; Mattoon, J.S. and Herrgesell, E.J. (2002) Urinary Tract. In: Nyland TG, Mattoon JS. *Small animal diagnostic ultrasound, 2nd edition.* Philadelphia: WB Saunders, 177-180.
 16. Ohishi, H.; Hirai, T. and Yamada, R. (1998) Three-dimensional power Doppler sonography of tumor vascularity. *J. Ultrasound Med.* 17: 619-622.
 17. Pairleitner, H.; Steiner, H. and Hasenoehrl, G. (1999) Three-dimensional power Doppler sonography: Imaging and quantifying blood flow and vascularization. *Ultrasound Obstet Gynecol.* 14: 139-143.
 18. Pan, H.A.; Wu, M.H. and Cheng, Y.C. (2003) Quantification of ovarian Doppler signal in hyperresponders during in vitro fertilization treatment using three-dimensional power Doppler ultrasonography. *Ultrasound Med. Biol.* 29: 921-927.
 19. Parfrey, P.S.; Griffiths, S.M. and Barrett, B.J. (1989) Contrast material-induced renal failure in patient with diabetes mellitus, renal insufficiency, or both: A prospective controlled study. *N. Engl. J. Med.* 320: 143-149.
 20. Pickering, T.G. (1991) Diagnostic and evaluation of renovascular hypertension: Indication for therapy. *Circulation.* Feb. 83(2 Suppl): I147-54.
 21. Reid, M.H.; Mackay, R.S. and Lantz, M.T. (1980) Non-invasive blood flow measurements by Doppler ultrasound with applications to renal artery flow determination. *Investigative Radiology.* 15: 323-331.
 22. Ritchie, C.J.; Edwards, W.S. and Mack, L.A. (1996) Three-dimensional ultrasonic angiography using power-mode Doppler. *Ultrasound Med. Biol.* 22: 277-286.
 23. Rivolta, R.; Elli, A. and Tarantino, A. (1999) Dimensional and hemodynamic differences between native and transplanted kidneys, evaluated by color doppler ultrasonography. *J. Nephrol.* 12: 179-183.
 24. Sehgal, C.M.; Arger, P.H. and Silver, A.C. (2001) Renal blood flow changes induced with endothelin-1 and fenoldopam mesylate at quantitative Doppler US: initial results in a canine study. *Radiology.* 219: 419-426.
 25. Spaulding, K.A. (1997) A Review of Sonographic Identification of Abdominal Blood Vessels and Juxtavascular Organs. *Vet. Radiol. Ultrasound.* 38: 4-23.
 26. Takahashi, S.; Narumi, Y. and Takahara, S. (1999) Acute renal allograft rejection in the canine: evaluation with serial duplex Doppler ultrasonography. *Transplantation Proceedings.* 31: 1731-1734.
 27. Tong, S.; Cardinal, H.N. and Downey, D.B. (1998) Analysis of linear, area, and volume distortion in 3D ultrasound imaging. *Ultrasound Med. Biol.* 24: 355-373.