

# Histomorphometrical evaluation of the gastrointestinal mucosa following chronic administration of Ghrelin in rat

Banan Khojasteh, S.M.<sup>1</sup>; Taati, M.<sup>2</sup>; Kheradmand, A.<sup>2</sup>; Sheikhzadeh, F.<sup>1</sup> and Zendehtdel, M.<sup>3\*</sup>

<sup>1</sup>Department of Animal Biology, Faculty of Natural Sciences, University of Tabriz, Tabriz, Iran. <sup>2</sup>Department of Pathobiology, Faculty of Veterinary Medicine, Lorestan University, Khorramabad, Iran. <sup>3</sup>Department of Basic Sciences, Faculty of Veterinary Medicine, University of Tehran, Tehran, Iran.

## Key Words:

Histomorphometry; gastrointestinal mucosa; chronic administration; ghrelin; rat.

## Correspondence

Zendehtdel, M.

Department of Basic Sciences, Faculty of Veterinary Medicine, University of Tehran, Tehran, Iran.

Tel: +98(21)61117186

Fax: +98(21)66933222

Email: zendehtdel@ut.ac.ir

Received: 21 March 2011,

Accepted: 11 June 2011

## Abstract

Ghrelin, a peptide hormone, has several functions, of which the best known is its growth hormone (GH)-releasing effect in the pituitary. It also increases appetite and feeding behavior. Recent studies have implicated ghrelin in the regulation of gastrointestinal, cardiovascular, and immune function, and suggest a role for ghrelin in bone physiology. In this study, the effect of chronically administered ghrelin on the histomorphometrical properties of stomach and different parts of intestinal mucosa were evaluated in a rat model. Significant differences between control and ghrelin-treated groups were observed in gastrointestinal mucosa, stomach gland length, and duodenal mucosal thickness, villus length and crypt depth ( $P < 0.05$ ). Chronic administration of ghrelin could therefore exert a gastrointestinal protective effect, as it promotes mucosal growth in the proximal gut and enhances gastric glands in oxyntic mucosa.

## Introduction

Ghrelin, a 28-amino acid peptide, is identified as an endogenous ligand for the growth hormone secretagogue receptor (GHSR) (Kojima *et al.*, 1999). GHSR is synthesized mainly in neuroendocrine cells (X/A-like cells in rodents) of the gastric fundus, and secreted into the circulation (Inui *et al.*, 2004). It is also expressed in the small intestine, colon, pancreatic islets, hypothalamus, pituitary, and several tissues in the periphery (Nass *et al.*, 2000). GHSR-1a is the receptor to which ghrelin binds and through which it exerts its physiological functions. Ghrelin release may be influenced by the status of fasting and nutrient feeding, because central and peripheral administration of this peptide to rats resulted in an increase in their feeding behavior (Nakazato *et al.*, 2001). Ghrelin has several functions, the best known of which is its growth hormone (GH)-releasing effect in the pituitary (Kojima *et al.*, 1999; Hataya *et al.*, 2001). It also increases appetite and feeding behavior (Ghatei and Bloom, 2000; Wren *et al.*, 2001a). Recent studies have implicated ghrelin in the regulation of gastrointestinal, cardiovascular, and immune functions and suggest a role for ghrelin in bone physiology (Tritos and Kokkotou, 2006). The receptor for ghrelin was reported to be expressed equally in all parts of the gastrointestinal tract, with similar expression levels in mucosal and muscle layers (Nass *et al.*, 2000). Therefore, the digestive tract is considered as both the

main organ that secretes ghrelin and an important target of ghrelin through its receptors (Wang *et al.*, 2007). The effect of ghrelin on gastrointestinal mucosa has been little investigated, but recent studies have revealed that its central or peripheral administration results in gastrointestinal protection against mucosal injury induced by noxious agents (Brzozowski *et al.*, 2006; Sibilia *et al.*, 2003; Brzozowski *et al.*, 2004; Konturek *et al.*, 2004; İseri *et al.*, 2005; Slomiany and Slomiany, 2010; Khalefa *et al.*, 2010). Ghrelin was also shown to have a direct proliferative action on the hypotrophic gut (De Segura *et al.*, 2010). In these pathological conditions, the pharmacological effect of ghrelin on gastrointestinal mucosa has been investigated.

In the present study, the effect of ghrelin on the histomorphometrical properties of gastrointestinal mucosa was evaluated in rats. Ghrelin was used at a dose resulting in serum levels in the range of those induced by fasting (Wren *et al.*, 2001b), a physiological state.

## Materials and Methods

### Drugs and chemicals

Rat lyophilized acylated ghrelin (n-octanoylated research grade) was purchased from Tocris Cookson Ltd. (Bristol, UK) and was dissolved in sterile physiological saline solution before injection.

### Animals

All investigations were conducted in accordance

with the Guiding Principles for the Care and Use of Research Animals. All animals were treated in compliance with the recommendations of the Animal Care Committee for the Lorestan University of Medical Sciences (Khorram Abad, Iran). 60-day adult male Wistar rats ( $n = 14$ ) purchased from Pasteur Institute of Iran were used for all experiments. All animals were allowed free access to standard rat food and tap water ad libitum. All rats were housed under standard conditions in groups of seven rats per cage at 21–24°C, with a constant 12 h light/dark cycle. All experimental procedures were carried out between 08.00 hours and 11.00 hours.

### Experimental design

The animals were divided into two groups ( $n = 7$  per group) as control and treatment groups. To verify the hypothesis that ghrelin treatment might alter the histomorphometrical parameters in gastrointestinal mucosa, a general protocol of subcutaneous (S.C.) injection of ghrelin (1 nmol per 100  $\mu$ l saline), or 100  $\mu$ l vehicle (physiological saline) to the control group, was applied once a day for 10 consecutive days. The dose of ghrelin used in our in vivo experiment was comparable with amounts of ghrelin secreted into the blood during starvation. Exogenous administration of 1 nmol/rat of ghrelin is able to induce a significant elevation (2.4–2.6 fold increase) in serum levels of total ghrelin 1 h after injection (Fernandez-Fernandez *et al.*, 2005), whose magnitude is in the range of that induced by fasting (Wren *et al.*, 2001b). The animals were injected under conscious conditions after careful handling to avoid any stressful influence.

### Tissue sampling and study parameters

The rats from both groups were killed by decapitation under diethyl ether anesthesia (May & Baker Ltd, Dagenham, UK) 3 h after injection on day 10 ( $n = 14$ ) from the first day of ghrelin injection. The stomach and the intestine (from the duodenum to the rectum) were then removed with gentle manipulations for light microscope analysis. They were opened longitudinally, rinsed with saline solution and pinned flat, with the mucosal surface facing upwards, in a box coated with paraffin wax. The specimens, including three different parts of the stomach (cardiac, body and pylorus), the duodenum, the ileum and the colon, were fixed in 10% neutral buffered formalin, embedded in paraffin, sectioned at 5  $\mu$ m and stained with hematoxylin and eosin for routine light microscopic examination. Histological examinations were performed by a histologist who was blinded to the study design. The lengths of glands and mucosal thickness of stomach (Figure 1), and duodenal and ileal villous lengths, crypt depths, villi per centimeter (V/cm), and total mucosal thickness (measured from the tip of the villus to the muscularis mucosa) (Figure

2), were assessed. Additionally, the mucosal thickness and crypt depths were measured in the colon (Figure 3) using light microscopy.

### Statistical Analysis

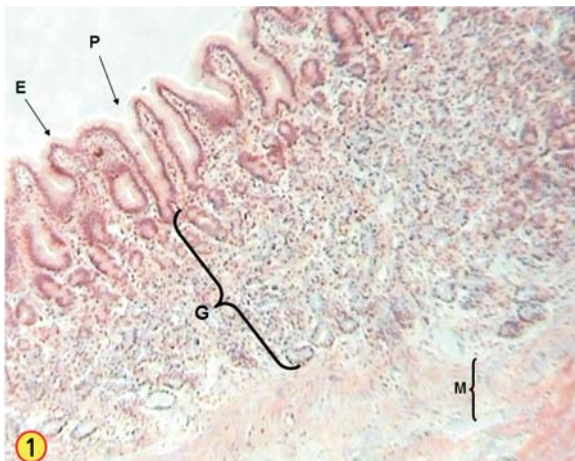All data from the parameters studied, namely total mucosal thickness, number of villi per centimeter, crypt depth and villous length were expressed as mean values  $\pm$  standard error of mean. An independent t-test was then performed using the SPSS for Windows statistical package program, version 12.0.0 (SPSS Inc., Chicago, IL), to compare the differences between the two groups receiving or not receiving ghrelin. The level of statistical significance was set at  $P < 0.05$ .

### Results

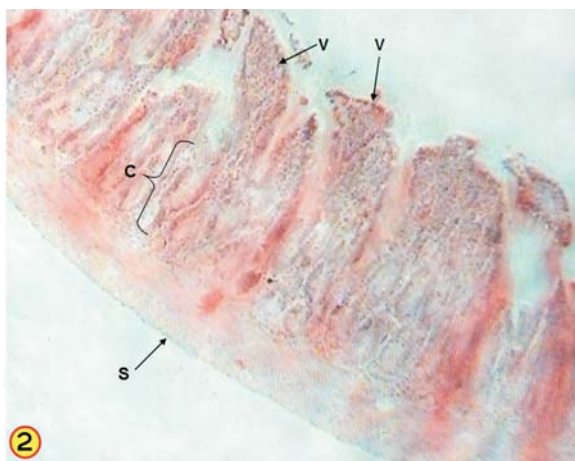
Among the assessed parameters, the gland lengths of the stomach were significantly different between ghrelin-treated and control groups ( $P < 0.05$ ) (Figure 1). The mucosal thicknesses, villi lengths and crypt depths of the duodenum were also significantly different between ghrelin-treated and control groups ( $P < 0.05$ ) (Table 1; Figure 2). The other parameters examined, including the mucosal thickness of the stomach, duodenum and ileum mucosal thicknesses villi per cm and villi lengths, crypt depths of the ileum, and mucosal thickness and crypt depths of the colon, showed no significant differences between ghrelin-treated and control groups (Figure 3).

### Discussion

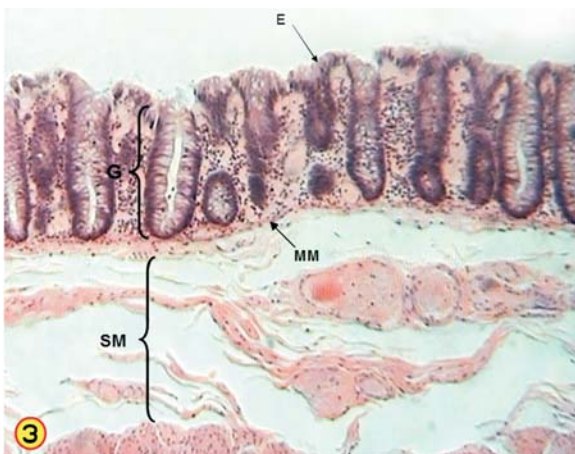
The present study demonstrated for the first time that the peripheral (S.C.) administration of ghrelin for 10 days significantly increased the length of gastric gland in oxyntic mucosa. As these glands are attributed to acid secretion, our data is in line with previous observations (Brzozowski *et al.*, 2006; Date *et al.*, 2001; Masuda *et al.*, 2000), which suggests that the peripheral and central administration of ghrelin increases gastric acid secretion in conscious rats. While a gastroprotective effect of ghrelin in pathological conditions has been shown (Brzozowski *et al.*, 2006; Sibilica *et al.*, 2003; Brzozowski *et al.*, 2004; Konturek *et al.*, 2004; Íseri *et al.*, 2005; Slomiany and Slomiany, 2010; Khalefa *et al.*, 2010). Brzozowski *et al.* (2006) revealed that alterations in gastric secretion do not play any significant role in the gastroprotective activity of this peptide. Therefore, ghrelin can be considered as a truly cytoprotective substance. The physiological role of ghrelin in gastric acid secretion is still unclear. Our data further indicates that S.C. chronic administration of ghrelin leads to significant increases in duodenal villi length, crypt depth and mucosal thickness when compared to controls. The villus size is an important measure in studies of intestinal cell proliferation, as the



**Figure 1:** The stomach showing epithelium (E), gastric pit (P), length of gland (G) and muscularis mucosae. H & E staining (×100).



**Figure 2:** Duodenal mucosa showing villi (V), crypt length (C) and serosa (S). H & E staining (×40).



**Figure 3:** Mucosa of colon. Epithelium (E), muscularis mucosa (MM) and submucosa (SM) have been shown. H & E staining (× 00).

**Table 1:** Morphometric results (mean ± SE) of stomach and duodenum mucosa for control and ghrelin-treated groups that had significant differences (\*P<0.05).

	Stomach		Duodenum	
	Gland Length	Mucosal Thickness (µm)	Villi Length (µm)	Crypt depth (µm)
Control	423.91±71.81	485±21.45	290.27±9.24	128.57±10.04
Ghrelin treated	637.29±18.42*	601.66±14.16*	420.95±20.44*	176.11±7.84*

function of crypt cell production is to provide an influx of cells to the functional compartment, the villus, the compartment size being the difference between cell influx and cell loss (Papavramidis *et al.*, 2009). In this study we found no significant changes in the mucosal parameters of the ileum and colon in ghrelin-treated rats compared to controls. A differentiated action of ghrelin on the proximal and distal gut might be a consequence of a variable expression of the ghrelin receptor, where nutritional status may be involved (Tung *et al.*, 2005). In fact, this may act as an adaptive mechanism governing intestinal growth and function. To our knowledge, the effect of exogenous ghrelin on gastrointestinal mucosa with a dose (1 nmol/rat, S.C.) that induces plasma levels of ghrelin similar to that in fasting (Wren *et al.*, 2001b) has not been previously investigated. Recently, de Segura *et al.* (2010) showed that intraperitoneal administration of ghrelin (with a dose higher than used here) restored normal levels of proliferation in the ileum of rats subjected to intestinal hypotrophy. Other authors have also demonstrated that exogenous ghrelin suppresses intestinal mucosal apoptosis in fasting rats (Park *et al.*, 2008). Ghrelin and its receptors are now recognized as components of the growth hormone axis, and are therefore potentially involved in tissue growth and development (Wang *et al.*, 2007). Previously, Konturek *et al.* (1988) have shown the effects of GH on the healing of gastric ulcers and mucosal growth in rats. Moreover, it has been revealed that the GH receptor is widely expressed throughout the intestinal mucosa (De Segura *et al.*, 2010). Alternatively, emerging evidence indicates that ghrelin may directly modulate cell proliferation and differentiation (Xu *et al.*, 2008; Gaytan *et al.*, 2005; Andreis *et al.*, 2003; Jeffery *et al.*, 2002). The mitotic effects of ghrelin have been demonstrated in numerous cell lines such as preosteoblasts (Kim *et al.*, 2005), neuronal precursors (Sato *et al.*, 2006), preadipocytes (Zhang *et al.*, 2004), and cardiomyocytes (Pettersson *et al.*, 2002). Very recently, a proliferative effect of ghrelin in gut mucosa was revealed by immunohistochemical analyses (de Segura *et al.*, 2010). It has been reported that the ghrelin functional receptor, GHSR-1a, is expressed in all parts of the gastrointestinal tract, with similar levels in mucosal and muscle layers and with highest expression in the cytoplasm of epithelial cells (Wang *et al.*, 2007). The release of ghrelin from endocrine cells in the oxyntic mucosa of the stomach is pulsatile and directly related

to feeding behavior (Tolle *et al.*, 2002), and it is upregulated during acute nutrient restriction (*i.e.* fasting and protein deprivation) (Nakazato *et al.*, 2001; Toshiani *et al.*, 2001). Additionally, a high density of ghrelin cells in oxyntic mucosa is associated with hypoglycemia (El-Salhy and Rauma, 2009). It is well known that situations such as prolonged starvation or chronic fasting may lead to hypotrophy of the gastrointestinal mucosa (de Segura *et al.*, 2010; Papavramidis *et al.*, 2009). Taken together, one would assume that proliferation of mucosal cells by ghrelin might be a physiological response to fasting-induced hypotrophy in gastrointestinal mucosa.

In conclusion, our data indicate that chronic administration of ghrelin could exert a gastrointestinal protective effect, as ghrelin promotes mucosal growth in the proximal gut and enhances gastric glands in oxyntic mucosa.

## References

1. Andreis, P.G.; Malendowicz, L.K.; Trejter, M.; Neri, G.; Spinazzi, R.; Rossi, G.P. and Nussdorfer, G.G. (2003) Ghrelin and growth hormone secretagogue receptor are expressed in the rat adrenal cortex: evidence that ghrelin stimulates the growth, but not the secretory activity of adrenal cells. *FEBS Lett.* 536: 173-179.
2. Brzozowski, T.; Konturek, P.C.; Sliwowski, Z.; Drozdowicz, D.; Kwiecien, S.; Pawlik, M.; Pajdo, R.; Konturek, S.J.; Pawlik, W.W. and Hahn, E.G. (2006) Neural aspects of ghrelin-induced gastroprotection against mucosal injury induced by noxious agents. *J. Physiol. Pharmacol.* 57(6): 63-76.
3. Brzozowski, T.; Konturek, P.C.; Konturek, S.J.; Kwiecień, S.; Drozdowicz, D.; Bielanski, W.; Pajdo, R.; Ptak, A.; Nikiforuk, A.; Pawlik, W.W. and Hahn, E.G. (2004) Exogenous and endogenous ghrelin in gastroprotection against stress-induced gastric damage. *Regul. Pept.* 120: 39-51.
4. Date, Y.; Nakazato, M.; Murakami, N.; Kojima, M.; Kangawa, K. and Matsukura, S. (2001) Ghrelin acts in the central nervous system to stimulate gastric acid secretion. *Biochem. Biophys. Res. Commun.* 280: 904-907.
5. De Segura, I.A.; Vallejo-Cremades, M.T.; Lomas, J.; Sánchez, M.F.; Caballero, M.I.; Largo, C. and de Miguel, E. (2010) Exogenous ghrelin regulates proliferation and apoptosis in the hypotrophic gut mucosa of the rat. *Exp. Biol. Med.* 235: 463-469.
6. El-Salhy, M. and Rauma, J. (2009) Low density of ghrelin cells in the oxyntic mucosa correlated to slow gastric emptying in patients with type 1 diabetes. *Molecular. Med. Reports.* 2: 893-896.
7. Fernández-Fernández, R.; Navarro, V.M.; Barreiro, M.L.; Vigo, E.M.; Tovar, S.; Sirotkin, A.V.; Casanueva, F.F.; Aguilar, E.; Dieguez, C.; Pinilla, L. and Tena-Sempere, M. (2005) Effect of chronic hyperghrelinemia on puberty onset and pregnancy outcome in the rat. *Endocrinology.* 146: 3018-3025.
8. Gaytan, F.; Morales, C.; Barreiro, M.L.; Jeffery, P.; Chopin, L.K.; Herington, A.C.; Casanueva, F.F.; Aguilar, E.; Dieguez, C. and Tena-Sempere, M. (2005) Expression of growth hormone secretagogue receptor type 1a, the functional ghrelin receptor, in human ovarian surface epithelium, mullerian duct derivatives, and ovarian tumors. *J. Clin. Endocrinol. Metab.* 90: 1798-1804.
9. Ghatei, M.A.; Bloom, S.R. (2000) Ghrelin enhances appetite and increases food intake in humans. *J. Clin. Endocrinol. Metab.* 86: 5992-5995.
10. Hataya, Y.; Akamizu, T.; Takaya, K.; Kanamoto, N.; Ariyasu, H.; Saijo, M.; Moriyama, K.; Shimatsu, A.; Kojima, M.; Kangawa, K. and Nakao, K. (2001) A low dose of ghrelin stimulates growth hormone (GH) release synergistically with GH-releasing hormone in humans. *J. Clin. Endocrinol. Metab.* 86: 4552-4555.
11. Inui, A.; Asakawa, A.; Bowers, C.Y.; Mantovani, G.; Laviano, A.; Meguid, M.M. and Fujimiya, M. (2004) Ghrelin, appetite, and gastric motility: the emerging role of the stomach as an endocrine organ. *FASEB J.* 18: 439-456.
12. Işeri, S.O.; Sener, G.; Yüksel, M.; Contuk, G.; Cetinel, S.; Gedik, N.; and Yegen B.C. (2005) Ghrelin against alendronate-induced gastric damage in rats. *J. Endocrinol.* 187: 399-406.
13. Jeffery, P.L.; Herington, A.C. and Chopin, L.K. (2002) Herington AC, Chopin LK. Expression and action of the growth hormone releasing peptide ghrelin and its receptor in prostate cancer cell lines. *J. Endocrinol.* 172: 7-11.
14. Khalefa, A.A.; Abd-Alaleem, D.I. and Attia, K.I. (2010) The protective effects of ghrelin and leptin against stress-induced gastric ulcer in rats. *Arab. J. Gastroenterology.* 11: 74-78.
15. Kim, S.W.; Her, S.J.; Park, S.J.; Kim, D.; Park, K.S.; Lee, H.K.; Han, B.H.; Kim, M.S.; Shin, C.S. and Kim, S.Y. (2005) Ghrelin stimulates proliferation and differentiation and inhibits apoptosis in osteoblastic MC3T3-E1 cells. *Bone.* 37: 59-69.
16. Kojima, M.; Hosoda, H.; Date, Y.; Nakazato, M.; Matsuo, H. and Kangawa, K. (1999) Ghrelin is a growth-hormone-releasing acylated peptide from stomach. *Nature.* 402: 656-660.
17. Konturek, S.J.; Brzozowski, T.; Dembinski, A.; Warzecha, Z.; Konturek, P.K. and Yanaihara, N. (1988) Interaction of growth hormone-releasing factor and somatostatin on ulcer healing and mucosal growth in rats: role of gastrin and epidermal growth factor. *Digestion.* 41: 121-128.
18. Konturek, P.C.; Brzozowski, T.; Pajdo, R.; Nikiforuk, A.; Kwiecien, S.; Harsch, I.; Drozdowicz, D.; Hahn, E.G. and Konturek, S.J. (2004) Ghrelin-a new gastroprotective factor in the gastric mucosa. *J. Physiol. Pharmacol.* 55: 325-336.
19. Masuda, Y.; Tanaka, T.; Inomata, N.; Ohnuma, N.; Tanaka, S.; Itoh, Z.; Hosoda, H.; Kojima, M. and

- Kangawa, K. (2000) Ghrelin stimulates gastric acid secretion and motility in rats. *Biochem. Biophys. Res. Commun.* 267: 905-908.
20. Nakazato, M.; Murakami, N.; Date, Y.; Kojima, M.; Matsuo, H.; Kangawa, K. and Matsukura, S. (2001) A role for ghrelin in the central regulation of feeding. *Nature.* 409: 194-198.
  21. Nass, R.; Gilrain, J.; Anderson, S.; Gaylinn, B.; Dalkin, A.; Day, R.; Peruggia, M. and Thorner, M.O. (2000). High plasma growth hormone (GH) levels inhibit expression of GH secretagogue receptor messenger ribonucleic acid levels in the rat pituitary. *Endocrinology.* 141: 2084-2089.
  22. Park, J.M.; Kakimoto, T.; Kuroki, T.; Shiraiishi, R.; Fujise, T.; Iwakiri, R. and Fujimoto, K. (2008) Suppression of intestinal mucosal apoptosis by ghrelin in fasting rats. *Exp. Biol. Med.* 233: 48-56.
  23. Papavramidis, T.S.; Kaidoglou, K.; Grosomanidis, V.; Kazamias, P.; Anagnostopoulos, T.H.; Paramythiotis, D. and Kotzampassi, K. (2009) Short-term fasting-induced jejunal mucosa atrophy in rats –the role of probiotics during refeeding. *Annals Gastroenterology.* 22(4): 268-274.
  24. Pettersson, I.; Muccioli, G.; Granata, R.; Deghenghi, R.; Ghigo, E.; Ohlsson, C. and Isgaard, J. (2002) Natural (ghrelin) and synthetic (hexarelin) GH secretagogues stimulate H9c2 cardiomyocyte cell proliferation. *J. Endocrinol.* 175: 201-209.
  25. Sato, M.; Nakahara, K.; Goto, S.; Kaiya, H.; Miyazato, M.; Date, Y.; Nakazato, M.; Kangawa, K. and Murakami, N. (2006) Effects of ghrelin and des-acyl ghrelin on neurogenesis of the rat fetal spinal cord. *Biochem. Biophys. Res. Commun.* 350: 598-603.
  26. Sibilila, V.; Rindi, G.; Pagani, F.; Rapetti, D.; Locatelli, V.; Torsello, A.; Campanini, N.; Deghenghi, R. and Netti, C. (2003) Ghrelin protects against ethanol-induced gastric ulcers in rats: studies on the mechanisms of action. *Endocrinology.* 144: 353-359.
  27. Slomiany, B.L.; Slomiany, A. (2010) Ghrelin protection against lipopolysaccharide-induced gastric mucosal cell apoptosis involves constitutive nitric oxide synthase-mediated caspase-3 S-nitrosylation. *Mediators. Inflamm.* 10: 1-7.
  28. Tolle, V.; Bassant, M.H.; Zizzari, P.; Poindessous-Jazat, F.; Tomasetto, C.; Epelbaum, J. and Bluet-Pajot, M.T. (2002) Ultradian rhythmicity of ghrelin secretion in relation with GH, feeding behavior, and sleep-wake patterns in rats. *Endocrinology.* 143: 1353-1361.
  29. Toshinai, K.; Mondal, M.S.; Nakazato, M.; Date, Y.; Murakami, N.; Kojima, M.; Kangawa, K. and Matsukura, S. (2001) Upregulation of ghrelin expression in the stomach upon fasting, insulin-induced hypoglycemia and leptin administration. *Biochem. Biophys. Res. Commun.* 281: 1220-1225.
  30. Tritos, N.A. and Kokkotou, E.G. (2006) The physiology and potential clinical applications of ghrelin, a novel peptide hormone. *Mayo Clin. Proc.* 81: 653-660.
  31. Tung, Y.C.; Hewson, A.K.; Carter, R.N. and Dickson, S.L. (2005) Central responsiveness to a ghrelin mimetic (GHRP-6) is rapidly altered by acute changes in nutritional status in rats. *J. Neuroendocrinol.* 17: 387-393.
  32. Wang, Z.; Wang, W.; Qiu, W.; Fan, Y.; Zhao, J.; Wang, Y. and Zheng, Q. (2007) Involvement of ghrelin-growth hormone secretagogue receptor system in pathoclinical profiles of digestive system cancer. *Acta Biochimica Biophysica Sinica.* 39(12): 992-998.
  33. Wren, A.M.; Seal, L.J.; Cohen, M.A.; Brynes, A.E.; Frost, G.S.; Murphy, K.G.; Dhillon, W.S.; Ghatei, M.A. and Bloom, S.R. (2001a) Ghrelin enhances appetite and increases food intake in humans. *J. Clin. Endocrinol. Metab.* 86: 5992-5995.
  34. Wren, A.M.; Small, C.J.; Abbott, C.R.; Dhillon, W.S.; Seal, L.J.; Cohen, M.A.; Batterham, R.L.; Taheri, S.; Stanley, S.A.; Ghatei, M.A. and Bloom, S.R. (2001b) Ghrelin causes hyperphagia and obesity in rats. *Diabetes.* 50: 2540-2547.
  35. Xu, G.; Li, Y.; An, W. and Zhang, W. (2008) Ghrelin and cell differentiation. *Acta Biochimica Biophysica Sinica.* 40: 841-847.
  36. Zhang, W.; Zhao, L.; Lin, T.R.; Chai, B.; Fan, Y.; Gantz, I. and Mulholland, M.W. (2004) Inhibition of adipogenesis by ghrelin. *Mol. Biol. Cell.* 15: 2484-2491.