

Endoscopic Finding of Gastric Ulcer in Rural Horse and Relation with *Gasterophilus* spp

Fereydon Rezazadeh^{1*}, Yashar Gharehaghajlou¹

Department of Clinical Sciences, Faculty of Veterinary Medicine, University of Tabriz, Tabriz, Iran

Abstract

BACKGROUND: Gastric ulcer is one of the most common diseases in racehorses. Colic, weight loss and poor performance are some of the clinical signs. The second and third larval stages of the bot fly *Gasterophilus* spp live in the stomach of the horse. This parasite is often found in large numbers of horses in all of the countries.

OBJECTIVES: The aim of this study was assessment of gastric ulcer in the rural horse and relation with *Gasterophilus* spp.

METHODS: In a cross-sectional study twenty rural horses were randomly selected for endoscopic finding for gastric ulcer. Gender, age, keeping situation, type of feed, history of colic, hair coat condition, deworming plan and presence of *Gasterophilus* spp. were recorded in a sheet. The horses were kept fasted for 12 hours before endoscopic examination by a VET3M OLYMPUS (Japan). Sedation was done by injection of Detomidine (Detomo Vet ® ceva-Spain) 0.1ml/100kg to look for presence of gastric ulcers with grading and *Gasterophilus* spp. Statistical analysis of the data was performed with 95% confidence interval and $P < 0.05$ was considered significant level.

RESULTS: Out of 20 horses, 13(65%) horses were mares and 7(35%) were males and Mean \pm 2SE of age was 8.9 \pm 4. Endoscopic observation showed 9 (45%) of the horses suffered from gastric ulcer. All of the ulcers were in non-glandular part and near the margo plicatus. Overall, 4 (20%) head of the horses had *Gasterophilus* spp. and all of them were present in the horse with no deworming plan. Based on the results, there was no association between presence of *Gasterophilus* with occurrence of Gastric ulcer ($P > 0.05$). Further study with high sample size is proposed.

CONCLUSIONS: There was high frequency of gastric ulcer in non-glandular portion of stomach in rural horse and there was not any association between presence of *Gasterophilus* and gastric ulcer.

KEYWORDS: *Gasterophilus* spp, gastric ulcer, gastroscopy, horse

Correspondence

Fereydon Rezazadeh, Department of Clinical Sciences, Faculty of Veterinary Medicine, University of Tabriz, Tabriz, Iran
Tel: +98(413) 36378742, Fax: +98(413)36378743, Email: f_rezazadeh@tabrizu.ac.ir

Received: 2019-06-29

Accepted: 2019-09-21

Copyright © 2020. This is an open-access article distributed under the terms of the Creative Commons Attribution- 4.0 International License which permits Share, copy and redistribution of the material in any medium or format or adapt, remix, transform, and build upon the material for any purpose, even commercially.

How to Cite This Article

Rezazadeh, F., & Gharehaghajlou, Y. (2020). Endoscopic Finding of Gastric Ulcer in Rural Horse and Relation with *Gasterophilus* spp. Iranian Journal of Veterinary Medicine, 14(1),

Introduction

Gasterophilus is from Gasterophilidae family and has 9 species that could cause a myiasis in gastrointestinal tract (Zumpt, 1965). They are distributed worldwide and especially in Afrotropical and Palearctic and could live in the equids about 10 months (Akele et al., 2018). Clinically, myiasis have been divided into 5 groups; sangvinivorous myiasis, dermal and subdermal myiasis, nasopharyngeal myiasis, intestinal myiasis, and urogenital myiasis (Zumpt, 1965). Numerous larvae of *Gasterophilus* could cause pathologic reaction in host. First stage of *Gasterophilus* is not a myiasis infection but with the formation of inflammatory reactions, it will become myiasis. Although larvae that have been swallowed with feed and indirectly pass way with feed whether they were alive or not, have not been cause of true myiasis and biological larvae of parasite have not been parasite temporarily mode of life (Zumpt, 1965). Larvae of stage 2 and 3 of *Gasterophilus intestinalis* live in equine gastric and have outspreaded worldwide, however, there were a few reports about cause of death for this species (Sc and Ph, 1972a). First stage of *Gasterophilus* larvae were drowned blood from host dermal and continued his way to oral cavity and finally reached the gastrointestinal tract (Zumpt, 1965). Diagnosis of clinical findings about stage of migration and stage of maturing are difficult but could cause harmful disorders in different species (Tavasoli and Bakht, 2012). Overall, *Gasterophilus* could cause problem in swallowing, ulcers in gastric and duodenum, obstruction in intestine, volvulus, rectal prolapse, anemia, diarrhea and digestion problem (Otranto et al., 2005).

Materials and Methods

Population study

Twenty rural horses with different gender

and age near Tabriz were selected by simple random method. Rural horses are mostly used in carrying heavy staff and passing long distances and they do not have basic care like horses in horse breeding centers or Jockey clubs. The type of feed consumed by horses was alfalfa, barley and grain which was given in four meals. All horses belonged to private owners and gastroscopy and all of the clinical examinations in the field were done with their permission. After study, all animals were returned back to their owners in the village. Specifications such as gender, age, circumstance of keeping, type of feed, History of colic, coat condition, deworming plan and time of using were recorded in pre-designed table. For facilitation of study, age was aggregated in 1-3, 4-6, 6-8 and 9 years and up.

Gastroscopy

The horses were kept fasted for 12 h before endoscopic examination by VET3M OLYMPUS (Japan). Before the gastroscopy each of the horses was sedated by injection of Detomidine (Detomo Vet ® Ceva-Spain) 0.1ml/100kg via IV. In video endoscopy right part of gastric around Margo plicatus, dorsal part of fundus, great curvature around Margo plicatus, less curvature around Margo plicatus and glandular part of stomach were examined.

Statistical Analysis

Data was analyzed by IBM SPSS statistics 24. Statistical analysis of the data was performed with 95% confidence level and $p < 0.05$ was considered as a significant level. Relation between *Gasterophilus* presence and deworming plan and Gastric ulcer were analyzed. Q-square Test was used for *Gasterophilus* presence with gastric ulcer and using anti-parasite drugs.

Results

Gastroscopy

20 horses were studied, 13 (65%) were males and 7 (35%) were mares. All of the horses did not have colic history and were kept in stables and had good coat. According to endoscopic observation 9 (45%) of the horses, 3 mares and 6 males, had gastric ulcer and 11(55%) of the horses, 4 mares and 7 males, did not have gastric ulcer [Table 1]. In video endoscopic examination all of the ulcers were in squamous portion of stomach, 4 (45%) of the ulcers were in great curvature of squamous portion, 4 (45%) ulcers were in less curvature of squamous

portion and 1 (10%) ulcer were in both less and great curvature of squamous portion of stomach [Table 2]. Based on Macalister and Andrew's pattern frequency of ulcer score in this study is: 0 score 70%, 1 score 5%, 3 score 15%, 4 score 10% and by ulcer severity frequency: 0 (55%), 1(15%), 2(15%), 3(5%) and 4(10%) [Table 3]. Overall, 4 (20%) head of the horses had *Gasterophilus* spp. and all of them showed presence in the horse with no deworming plan [Figure 1-2].

Statistical Analysis

There is not any relation between presence of *Gasterophilus* spp. using anti-parasite drug ($p=0.20$) and gastric ulcer ($p=0.8$)

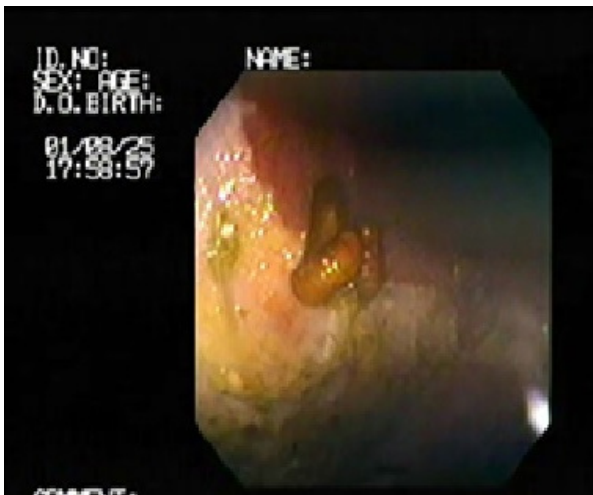


Figure 2. 12 years old mare with gastric ulcer (severity 2) and *Gasterophilus* spp.(botfly)

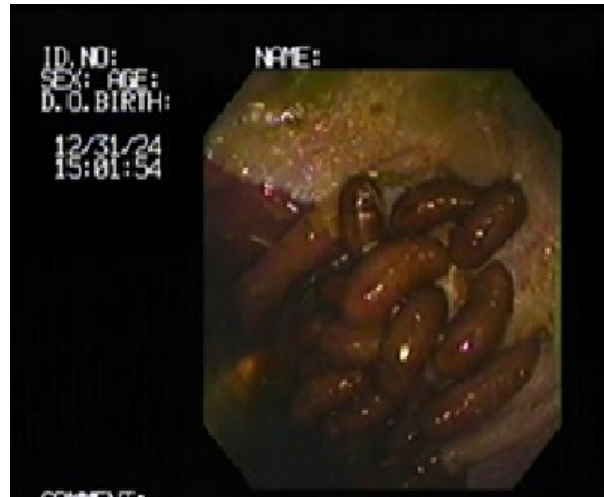

Figure 1. 12 years old mare with gastric ulcer (severity 2) and *Gasterophilus* spp.(botfly)

Table 1. Frequency of gastric ulcer in both mare and male

Female (n)		Male (n)	
Healthy	Have a ulcer	Healthy	Have a ulcer
4	3	7	6
7		13	

Table 2. Portion of ulcers in non-glandular part of stomach

	Frequency	Percent	Valid Percent	Cumulative Percent
Healthy	11	55.0	55.0	55.0
non-glandular portion of greater curvature	4	20.0	20.0	75.0
non-glandular portion of Lesser curvature	4	20.0	20.0	95.0
Both Great and Lesser curvature	1	5.0	5.0	100.0
Total	20	100.0	100.0	

Table 3. Frequency of scoring of ulcers that found in the endoscopic examination: 0 score 70%, 1 score 5%, 3score 15%, 4 score 10%

Score	Frequency	Percent	Valid Percent	Cumulative Percent
.0	14	70.0	70.0	70.0
1.0	1	5.0	5.0	75.0
3.0	3	15.0	15.0	90.0
4.0	2	10.0	10.0	100.0
Total	20	100.0	100.0	

and, based on the results, there was no association between presence of *Gasterophilus* with occurrence of Gastric ulcer ($P>0.05$).

Discussion

Equine gastric ulcer syndrome (EGUS) terminology is divided in 2 parts, non-glandular ulcer and glandular ulcer (Sykes and Jokisalo, 2014). Factors mentioned above cause ulcer in non-glandular portion that could be increased in gastric acid secretion and excessive contact of gastric acid with squamous part and increased in VFA secretion (Sykes and Jokisalo, 2015). In glandular portion ulcer might be *Helicobacter* spp, overuse of NSAIDs such as phenyl butazone, but cause of ulcer in this part is not clarified (Sykes and Jokisalo, 2015). There are a lot of

clinical findings for gastric ulcer, for example, recurrent and sever colic, diarrhea, bad hair coat condition, anorexia, weightloss, change in behavior like a crib biting, depression, decrease in performance and (Malmkvist et al., 2012; Videla and Andrews, 2009; Wickens et al., 2013) and the best way for diagnosis of EGUS is endoscopy. Climate of Iran has suitable ecological factors and Tabriz, Iran specifically, has a best weather for growing and spreading *Gasterophilus*, also most of the *Gasterophilus* species have been recognized (*G.intestinalis*, *G.haemorrhoidalis*, *G.nasalis*, *G.inermis*, *G.pecorum*, *G.meridionalis* *G.nigricornis*). The difference between species, prevalence and larval burden of *Gasterophilus* in our study and other overseas studies may be because of different

climate, management factors (anti parasite schedule), hosts (for example shade of genetics and irritant of host) and differences in genetics and population composition of parasite (Mashayekhi and Ashtari, 2013). Excess of larvae that presented in stomach may cause obstruction and colic and excess larvae that damaged the tissue of stomach or mucosa of intestinal and were limited vital nutrient may cause health problem in host (Waddell, 1972). Ulcers and lesions studied by Waddell revealed similarity with ulcers in pigs that had a gastric ulcer. The ulcers in pig stomach had bleeding but there was not any bleeding in ulcer site of horse gastric. Although this disease has high mortality in pigs, this disease has less pathogenicity in horses (Waddell, 1972). In our study, no bleeding ulcer was observed in endoscopic finding. Depth of ulcers caused by larvae do not have any association with thickness of gastric and duodenum. Moreover, ulcers which were caused by larvae can affect thickness of layer. Cells proliferation under gastric ulcers and duodenum ulcer do not have any relation with depth of ulcers. Cells proliferation under gastric ulcer had more significant progress than ulcers in duodenum part. Histopathologic findings revealed severe fibrosis in ulcers and this finding in affected duodenum revealed severe damage in submucosal glands around and below lesions. Fibrosis of the underlying lamina propria mucosa and tunica submucosa was distinctive but was not able to renew thickness of duodenum (Cogley and Cogley, 1999). The horse was necropsied and stomach adjacent to spleen had a gastritis, ulcers with 1cm were presented and all the ulcers were in non-glandular part of gastric (Dart et al., 1987). The study of Sequeira and his colleagues was performed in 95 horses that

16.84% of which had a *Gasterophilus nasa-lis* and the lesions site of larvae attachment both microscopically and macroscopically was examined. Erosion, ulcers of stomach and proximal duodenum were mostly recognized macroscopic. Based on microscopic findings, lesions of spectrum ranged from inflammatory reactions to necrosis and ulceration. Macroscopic findings revealed that lesions were scattered in duodenum and ampulla part of proximal duodenum and lesions shape was circular and punctiform. Also, at higher levels of infestation, lesion had a different type (Sequeira et al., 2001). None of our cases necropsy during the period of study, so we did not have any information about type of lesion in necropsy or histopathology. In study of 16 horses that were clinically suspected for gastric ulcer, five of the horses had presented both gastric ulcer and *Gasterophilus* and all of the horses died because of cachexia. *Gasterophilus* was found in post mortem findings of three horses (Mashayekhi and Ashtari, 2013). We could not send the samples for parasitological study because all of the horses were alive and samples were randomly selected without a history of colic. Nine mares of 80 horses in one herd that were fed in pasture died. Necropsy of gastrointestinal tract revealed a lot of bot flies that had adhered to esophagus mucosa and non-glandular part of gastric. Parasitological tests revealed 3rd stage larvae of *Gasterophilus pecorum* (Moshaverinia et al., 2016). Fortunately, none of the animals died during the period of our study. Also, in the study of 330 horses was done in Belgium during one year, 193(58%) horses had *Gasterophilus*. Size of lesions was between 1cm² and 17cm² and most of the larvae were seen in *Margo plicatus* (Agneessens et al., 1998). S.R Felix et al reported prevalence of Gas-

terophilus in Brazil in which 395 horses were slaughtered, 126 of the horses were infested with *Gasterophilus*, 100 horses (25.32%) had *G. inesternalis* and 47 (11.90%) had *G. nasalis* (Felix et al., 2007). Bucknell and his colleagues demonstrated presence of parasite was affected by age of horses and in their study *Gasterophilus nasalis* was present in horses that were more than 20 years old (Bucknell, 1995). However, in our study and based on statistical analyses, the mentioned results were not acquired. The study of gross necropsy on 10 donkeys in Spain, due to their lack of proper nutrition, showed that 30% had *Gasterophilus* and histopathology studies showed damage to stomach and subchorionic edema with parakeratotic hyperkeratosis (Briceño et al., n.d.). In summation, in our study we could not find any relation between horses and presence of *Gasterophilus* and it may be due to the small amount of our samples for study of gastric ulcer.

Acknowledgments

The authors thank Vice-president of research in the University of Tabriz and all of the horse owners, especially, Mr. Jabraeil Mollaei Sefidan for his collaboration.

Conflict of Interest

The authors declare that there is no conflict of interest.

References

- Agneessens, J., Engelen, S., Debever, P., Ver-cruysse, J., 1998. *Gasterophilus intestinalis* infections in horses in Belgium. *Vet Parasitol.* 77, 199–204. [https://doi.org/10.1016/S0304-4017\(98\)00106-X](https://doi.org/10.1016/S0304-4017(98)00106-X). PMID: 9746291
- Akele, Y., Enbiyale, G., Negash, A., Ayana, E., 2018. Equine myiasis caused by *Gasterophilus* flies: A review. *Faculty of Veterinary Medicine, College of Medical and Health Science, Lecturer at University of Gondar, Faculty of Veterinary Medicine*, 9, 44–52. <https://doi.org/10.5829/idosi.apg.2018.44.52>
- Morales Briceño, A., Lamprea Garrido, A. and Méndez Sánchez, A., 2015. Gastric ulcers syndrome in donkeys. *Revista de Medicina Veterinaria*, (30), pp.31-35. Bucknell, D.G., 1995. Victoria, *Atmtdiia* 25.
- Cogley, T.P., Cogley, M.C., 1999. Inter-relationship between *Gasterophilus* larvae and the horse's gastric and duodenal wall with special reference to penetration. *Vet Parasitol.* 86, 127–142. [https://doi.org/10.1016/S0304-4017\(99\)00119-3](https://doi.org/10.1016/S0304-4017(99)00119-3). PMID:10496697
- Dart, A.J., Hutchins, D.R., Begg, A.P., 1987. Suppurative splenitis and peritonitis in a horse after gastric ulceration caused by larvae of *Gasterophilus intestinalis*. *Aust Vet J.* 64, 155–158. <https://doi.org/10.1111/j.1751-0813.1987.tb09669.x>. PMID: 3632494
- Felix, S.R., Silva, C.E., Schmidt, E., Nizoli, L.Q., Götze, M.M., Silva, S.S., 2007. Presence of *Gasterophilus* (Leach, 1817) (Diptera: Oestridae) in horses in Rio Grande do Sul State, Brazil. *Parasitol Latinoam.* 62, 122–126. <https://doi.org/10.4067/S0717-77122007000200004>
- Malmkvist, J., Møller, J., Luthersson, N., Palme, R., Winther, J., Søndergaard, E., 2012. Behaviour and stress responses in horses with gastric ulceration. *Appl Anim Behav Sci.* 142, 160–167. <https://doi.org/10.1016/j.applanim.2012.10.002>
- Mashayekhi, M., Ashtari, B., 2013. Study of *Gasterophilus* role in Equine Gastric Ulcer Syndrome in Tabriz area. *Bull Environ Pharmacol. Life Sci.* 212, 169–172.
- Moshaverinia, A., Baratpour, A., Abedi, V., Mohammadi-yekta, M., 2016. *Gasterophilosis* in Turkmen horses caused by *Gasterophilus pecorum* (Diptera, Oestridae) 17, 49–52.
- Otranto, D., Milillo, P., Capelli, G., Colwell, D.D., 2005. Species composition of *Gasterophilus* spp. (Diptera, Oestridae) causing equine gastric myiasis in southern Italy: Parasite biodiversity and risks for extinction. *Vet Parasitol.* 133, 111–118. <https://doi.org/10.1016/j.vet>

par.2005.05.015 . PMID: 15978726

Waddell, A. H. (1972). The pathogenicity of *Gastrophilus intestinalis* larvae in the stomach of the horse. *Aust Vet J*, 48(6), 332-335. Sc, B. V, Ph, D., 1972b. in the stomach of the horse 48, 5-8. <https://doi.org/10.1111/j.1751-0813.1972.tb02261.x> . PMID: 5075205

Sequeira, J.L., Tostes, R.A., Oliveira-Sequeira, T.C.G., 2001. Prevalence and macro- and microscopic lesions produced by *Gasterophilus nasalis* (Diptera: Oestridae) in the Botucatu Region, SP, *Bras Vet Parasitol*. 102, 261-266. [https://doi.org/10.1016/S0304-4017\(01\)00536-2](https://doi.org/10.1016/S0304-4017(01)00536-2) . PMID: 11777606

Sykes, B., Jokisalo, J.M., 2015. Rethinking equine gastric ulcer syndrome: Part 3 - Equine glandular gastric ulcer syndrome (EGGUS). *Equine Vet Educ*. 27, 372-375. <https://doi.org/10.1111/eve.12287>

Sykes, B.W., Jokisalo, J.M., 2015. Rethinking equine gastric ulcer syndrome: Part 2 - Equine squamous gastric ulcer syndrome (ESGUS). *Equine Vet Educ*. 27, 264-268. <https://doi.org/10.1111/eve.12277>

Sykes, B.W., Jokisalo, J.M., 2014. Rethinking equine gastric ulcer syndrome: Part 1 - Terminology, clinical signs and diagnosis. *Equine Vet Educ*. 26, 543-547. <https://doi.org/10.1111/eve.12236>

Tavassoli, M., Bakht, M., 2012. *Gastrophilus* spp. myiasis in Iranian equine. *Sci Parasitol* 13, 83-86.

Videla, R., Andrews, F.M., 2009. New Perspectives in Equine Gastric Ulcer Syndrome. *Vet Clin North Am. - Equine Pract*. 25, 283-301. <https://doi.org/10.1016/j.cveq.2009.04.013>. PMID: 19580940

Wickens, C.L., McCall, C.A., Bursian, S., Hanson, R., Heleski, C.R., Liesman, J.S., McElhenney, W.H., Trottier, N.L., 2013. Journal of equine veterinary science assessment of gastric ulceration and gastrin response in horses with history of crib-biting. *J Equine Vet Sci*. 33, 739-745. <https://doi.org/10.1016/j.jevs.2012.12.004>

Zumpt, F., 1965. Myiasis in man and animals in the Old World. A textbook for physicians, veterinarians and zoologists. *Myiasis in Man and*

Animals in the Old World. A Textbook for Physicians, Veterinarians and Zoologists.

یافته های آندوسکوپی زخم معده در اسب های روستایی و ارتباط آن با لارو گونه های گاستروفیلوس

فریدون رضازاده^{۱*}، یاشار قره آغاجلو^۱

گروه علوم درمانگاهی، دانشکده دامپزشکی دانشگاه تبریز، تبریز، ایران

(دریافت مقاله: ۰۸ تیر ماه ۱۳۹۸، پذیرش نهایی: ۳۰ شهریور ماه ۱۳۹۸)

چکیده

زمینه مطالعه: زخم معده یکی از بیماری های شایع در اسب های ورزشی است. کولیک، کاهش وزن کاهش کارایی ورزشی برخی از نشانه های بالینی این بیماری است. لارو مرحله دوم و سوم خرمگس یا گونه های گاستروفیلوس در معده اسب می توانند زندگی نمایند. اگر چه پیدان شدن این انگل در معده اسب در بسیاری از کشورها و در جمعیت زیادی از اسبها مشاهده شده است.

هدف: از مطالعه حاضر یافتن فراوانی زخم معده در اسب های روستایی و ارتباط آن با لارو گونه های گاستروفیلوس بوده است.

روش کار: در یک مطالعه مقطعی ۲۰ رأس اسب روستایی بصورت تصادفی برای ارزیابی زخم معده مورد آندوسکوپی قرار گرفتند. جنس، سن، وضعیت نگه داری، نوع خوراک، تاریخچه رخداد کولیک، وضعیت پوشش خارجی، برنامه ضد انگلی و حضور یا عدم حضور لارو گاستروفیلوس در یک برگه ثبت گردید. ۱۲ ساعت قبل از آندوسکوپی با استفاده از دستگاه VET3M Olympus (Japan)، اسبها ناشتا بوده و آرام بخشی با استفاده از دتومیدین (Detemo vet®، Ceva-Spain) به میزان ۰/۱ میلی لیتر/۱۰۰ کیلوگرم وزن بدن صورت گرفت. آنالیز آماری داده ها با استفاده از نرم افزار SPSS نسخه ۲۴ انجام شد و سطح اطمینان ۹۵٪ انجام شد.

نتایج: ۱۳ (۶۵٪) رأس از اسبها ماده و ۷ (۳۵٪) رأس آنها نر بودند. سن اسب های مورد مطالعه $4 \pm 8/9$ سال بود و ۹ (۴۵٪) رأس از اسبها در آندوسکوپی زخم معده را نشان دادند. تمامی زخم های مورد مشاهده در بخش غیر غده ای معده و نزدیک مارگو پلیکاتوس قرار داشت. چهار رأس (۲۰٪) از اسبها لارو گونه های گاستروفیلوس را نشان دادند و در هیچکدام از اسبها برنامه ضد انگلی اجرا نشده بود. بر اساس آنالیز آماری صورت گرفته در مطالعه حاضر ارتباطی بین حضور انگل و زخم معده بدست نیامد ($P < 0/05$). مطالعه دیگری با جمعیت زیادی از اسبها بایستی صورت بگیرد.

نتیجه گیری نهایی: فراوانی زخم معده در جمعیت اسب های روستایی بالاست و ارتباطی بین حضور انگل در معده و زخم های موجود در آن یافت نشد.

واژه های کلیدی:

زخم معده، اسب، گونه های گاستروفیلوس، گاستروسکوپی