

## The Effect of Autogenous Peritoneal Graft Augmented with Platelets- Plasma Rich Protein on the Healing of Induced Achilles Tendon Rupture, in Dogs

Layth Mahmoud Alkattan Asma Hussein Alawi Osama Mofak Al-Iraqi

*Department of Surgery and Theriogenology, College of Veterinary Medicine, University of Mosul, Mosul, Iraq*

### Abstract

**BACKGROUND:** In dogs, Achilles tendon rupture is an important clinical issue. Treatment of the ruptured tendon remains a controversial problem. However, surgical intervention, by the using of different biological scaffolds, has been recognized as the most effective approach for the repair of such cases.

**OBJECTIVES:** The current study aimed to evaluate the efficiency of platelets-plasma rich protein (PRP) and autogenous peritoneal scaffold to improve the healing process of ruptured Achilles tendon in dogs.

**METHODS:** Eighteen healthy dogs of the local breed were randomly allocated into three equal groups. Achilles tendon of the hind limbs were prepared aseptically and transected transversely. In the control group, the tendon was reconstructed with the traditional suture using modified Kessler techniques. In the peritoneal scaffold group, a combination of traditional suture and the autogenous peritoneal scaffold was used to augment the defected tendon. In the peritoneal scaffold with the PRP group, the induced rupture was treated as similar to the peritoneal scaffold group and supported by a topical application of PRP. In addition to the gross observation, the healing process was evaluated with histopathological and sonographic investigations at 15, 30, and 60 days post-operative.

**RESULTS:** By comparison with control, the utilizing of autologous peritoneum scaffold augmented with PRP revealed a valuable impact on Achilles tendon healing. This impact was manifested by improved fibroblastic proliferation, reduced adhesion, and improved mechanical function of the tendon. Also, the sonographic examination of the fibrosis site demonstrated the presence of hyperechoic spots.

**CONCLUSIONS:** We concluded that utilizing both the peritoneal scaffold augmented and PRP along with the traditional suture revealed remarkable optimistic effects on healing of the ruptured Achilles tendon in dogs.

**KEYWORDS:** Achilles tendon repair, Dogs, Evaluation, Peritoneum, Scaffolds

### Correspondence

Alkattan L M, Department of Surgery and Theriogenology, College of Veterinary Medicine, University of Mosul ,Mosul, Iraq  
Tel: +96 47701631455, Fax: +96 47701631455, Email: [laythalkattan@yahoo.com](mailto:laythalkattan@yahoo.com)

Received: 2019-12-25

Accepted: 2020-04-11

Copyright © 2020. This is an open-access article distributed under the terms of the Creative Commons Attribution- 4.0 International License which permits Share, copy and redistribution of the material in any medium or format or adapt, remix, transform, and build upon the material for any purpose, even commercially.

### How to Cite This Article

Alawi, A .H., Alkattan, L. M., and Al- Iraqi, OM . (2020). The Effect of Autogenous Peritoneal Graft Augmented with Platelets- Plasma Rich Protein on the Healing of Induced Achilles Tendon Rupture, in Dogs. Iranian Journal of Veterinary Medicine, 14(2):111-119

## **Introduction**

Tendon injuries commonly occur and constitute one of the greatest challenges for orthopedic surgery. The healing process of such cases is slow and treatment might require prolonged rehabilitation (Denitsa et al., 2015). In dogs, both partial and total rupture of Achilles tendon is not an uncommon traumatic problem (Taniguchil et al., 2018). Several therapeutic choices have been used to repair the ruptured tendons; these included traditional suturing, autografting, allografting, and synthetic prostheses (Denitsa et al., 2015). Treatment of the ruptured Achilles tendon is continued to be controversial; however, the most frequently applied methods are conservative, percutaneous, and surgical repair (Greca et al., 2005). Re-rupture after treatment is the major problem; Thus, surgical intervention is advisable to restore tendon integrity, strength, and functional (Spinella et al., 2010). Various studies have assessed the efficacy of utilizing several materials that have the potential to improve the healing process and tendon regeneration without the development of fibrotic tissue. For instance, polypropylene mesh, collagen fiber implantation, pericardium, small intestine submucosa, dermal patch, mesenchymal stem cells, vein graft, platelet-rich plasma and omentum (Jahani et al., 2015; Canapp et al., 2016; Bellenger, 2003). The peritoneum is a serous membrane covered by mesothelial cells and supported by a stromal layer. The stromal layer is composed of elastic and collagen fiber, mast cells, macrophages, lymphocytes, adipose cells, and glycosaminoglycans (Konig et al., 2004). The utilization of the peritoneum is based on the capacity of its relative cells to release growth factors such as transforming growth factor, fibroblast growth factor, and epider-

mal growth factor, which demonstrated a positive effect on the healing process (Hosgood, 2003). The application of PRP enables tendon lesions to recuperate and eliminate signs of inflammation (Bellido et al., 2018). Ultrasonographic evaluation of the normal Achilles tendon was firstly reported in 1997, where a report investigated the effectiveness of ultrasonography as a diagnostic imaging procedure in orthopedic problems in small animals (Kramer et al., 1997). Based on the sonographic echotexture pattern, a previous study on canine Achilles tendon injury demonstrated that ultrasonographic examination is insufficient for differentiation between the partial and complete rupture of the Achilles tendon (Rivers, 1997). However, another relevant study indicated that ultrasonography can be employed to categorize the partial ruptures into deep or superficial ruptures (Kramer et al., 2001). Additionally, a considerable amount of literature has been published on the using of ultrasounds as a diagnostic tool of Achilles tendon affections in dogs (Baltzer and Rist, 2009; Case et al., 2013; Spinella et al., 2010). Therefore, the present study was directed to investigate the role of PRP with peritoneum in the healing process of experimental Achilles tendon rupture in dogs.

## **Materials and methods**

Healthy local breed dogs (n=18) were randomly allocated into three equal groups (6 animals each). A uniform protocol of general anesthesia consisting of Ketamine 5% (10 mg/kg) and Xylazine 2% (3 mg/kg) intramuscularly (IM) was followed. The site of operation directly over the tendon was prepared under standard sterilization procedures. In the control group, Achilles ten-

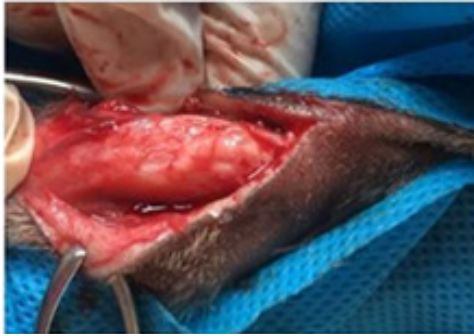
don was transversely sectioned and repaired with a modified Kessler method only and the leg was fixed with Gipson. In the peritoneal scaffold group, peritoneum graft was harvested directly by making an incision at the lower abdomen near to the umbilicus from the same dog, isolated segment (approximately 3×3 cm) was preserved in ringer solution containing 10% gentamicin. The tendon repaired as mentioned in the control group and augmented with peritoneum graft. In the peritoneal scaffold with the PRP group, the tendon was repaired by tenorrhaphy, augmented with peritoneum graft, and PRP was applied directly on the site of the ruptured area.

The platelet-rich plasma protein (PRP) was prepared at the time of operation where blood samples (20 ml) were collected from the jugular vein and separated into two test tubes (10 ml) containing 0.5 ml of 3.2% sodium citrate. Following centrifugation at 1500 rpm for 10 min, the supernatant aspirated and the remaining part of blood represents the PRP (2 ml). This portion was centrifuged again at 1500 rpm for 15 min, then PRP was activated with two drops of 10% calcium chloride (Malik et al., 2013). The site of operation was prepared for surgical operation starting just 5cm proximal to the calcaneus on the lateral aspect of the limb. Then, the surgical site was closed routinely and covered with a non-adhesive dressing bandage. The operated limb immobilized using Gipson (with window) for 2-weeks. Postoperatively, the site of surgery was evaluated clinically at 15, 30, and 60 days. Lameness was categorized according to the lameness scoring (I to VI scale) system (Millis et al., 2004). To determine the gross pathological changes, biopsies were collected from two dogs at each period and the site of the collected specimen was repaired routinely without killing the

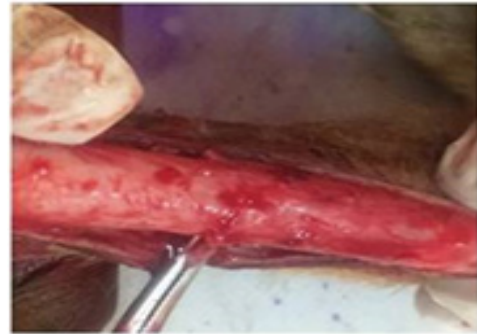
animal. Ultrasonographic examination was performed at the longitudinal axis (Lamb and Duvernois, 2005). Tissue sections were stained with Harri's hematoxylin and alcoholic eosin (Suvana et al., 2013), and the stained slides were examined at 100X.

## Results

Postoperatively, clinical parameters indicated that all operated animals were healthy, alert, and showed normal activity with a good appetite. There was no evidence of serious complications such as infection or wound dehiscence at the operative leg. However, in all groups, animals exhibited lameness a few days post-operation. Lameness was classified according to the lameness score system as grade I. In the control group, the symptoms of lameness persisted for 15 days and 8 days in the peritoneal scaffold group. Interestingly, in the peritoneal scaffold with the PRP group, less severe lameness was reported which lasts for 6 days. Grossly, there was thickening at the area of operation which persisted for 20, 26, and 27 days in control, peritoneal scaffold, and peritoneal scaffold with PRP groups, respectively. In all groups, lameness was subsided gradually. Grossly, in the control group, there was massive adhesion between the tendon and neighboring tissues with incomplete healing at the two ends of the tendon. In the peritoneal scaffold group, there was moderate adhesion with an earlier healing process than the control group (Figure 1). In the peritoneal scaffold with the PRP group, there was mild adhesion with complete healing (Figure 2). Interestingly, in all operated animals, there was no change in the total tendon length.



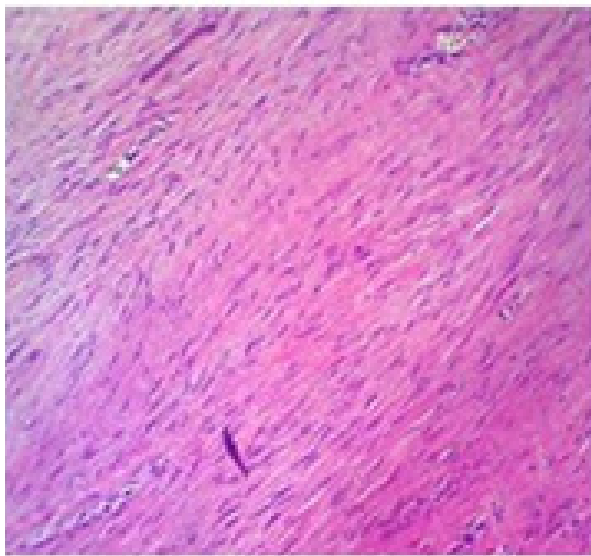
**Figure 1.** The peritoneal scaffold group, moderate adhesion with adequate healing (15 days post-surgery).



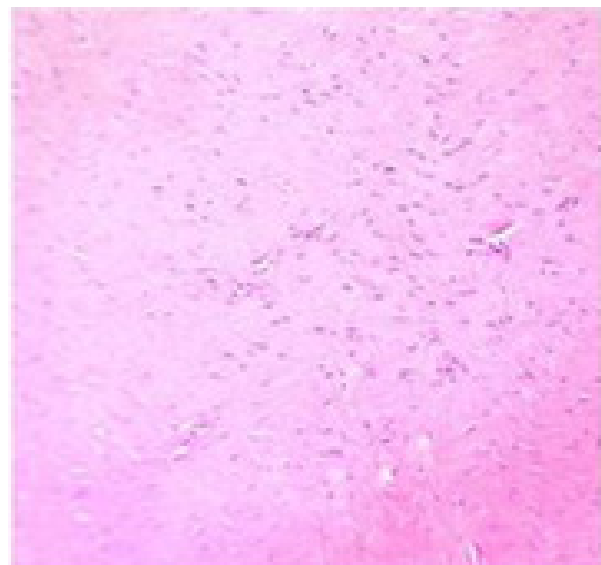
**Figure 2.** The peritoneal scaffold with PRP group mild adhesion with complete healing.

Histopathologically, in the control group, results revealed the presence of maturation of the granulation tissue which characterized by dense collagen fiber with a moderate proliferation of active fibroblast after 30 days post-surgery. However, after 60 days of operation, mature connective tissue was presented and characterized by the organization of collagen fiber (Figure 3). In the peritoneal scaffold group, at 15 days, there was a severe proliferation of active fibroblasts with a little number of blood vessels. Additionally, there was a reduction in the density of collagen fiber with a mild inflammatory response. At day 60, there was a de-

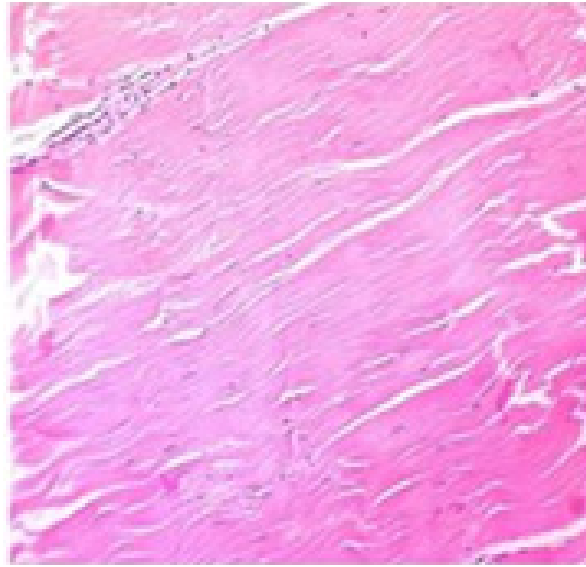
crease in the number of spindle fibroblast cells, collagen fiber organization and vascularity were qualitatively similar to those of normal tendon tissue. There were no signs of cartilage or bone formation within the tendon (Figure 4). In the peritoneal scaffold with the PRP group, at 30 days, the presence of connective tissue with collagen fibers formation accompanied by a reduction in the number of fibroblast cells and no inflammatory reaction. At 60 days, sections revealed the presence of new collagen fibers with further decreases in the number of fibroblasts. Besides, edema was noted between collagen fibers (Figure 5).



**Figure 3.** Control groups at day 60 post-operation. The section displays the presence of mature connective tissue and the organization of collagen fiber. HandE, 100X.



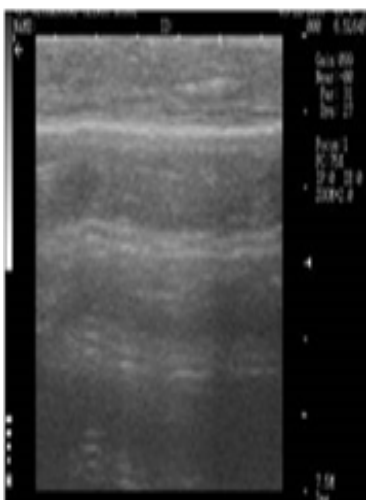
**Figure 4.** The peritoneal scaffold group at 60 days showed a decreased number of spindle fibroblast cells and collagen fiber organization HandE, 100x.



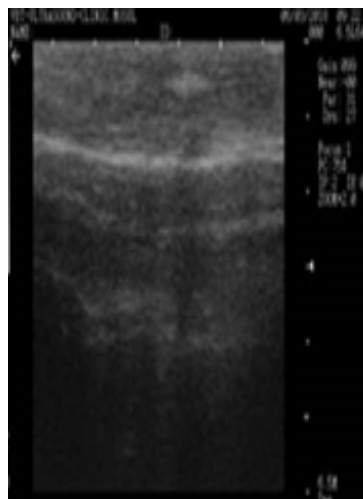**Figure 5.** The peritoneal scaffold with the PRP group at 60 days showed new collagen fibers formation with a decreased number of fibroblast cells. The presence of edema between collagen fibers. HandE, 100X.

In the control group, the sonographic investigation revealed a mottled heterogeneous fiber pattern with an area of hypoechogenicity at 15 days; however, hyperechogenicity was the main feature at 30 days with homogenous fiber pattern (Figure 6). In the peritoneal scaffold group, at 15 days, hyperechogenic with a hypoechogenic area were recognized

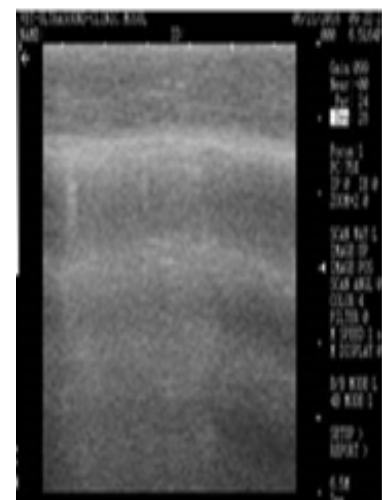
at the center of the tissue. Moreover, sections showed a small hypoechoic area at 30 days and hyperechogenic at 60 days (Figure 7). In the peritoneal scaffold with the PRP group, at 15 days, the hyperechogenic area was determined at the center. In the 30 and 60 days, there was hyperechogenic hypoechogenicity at the site of operation (Figure 8).



**Figure 6.** Longitudinal ultrasound image of a lateral aspect of the calcaneal tendon in the control group at 60 days. Homogenous fiber pattern with an area of hyperechogenic.



**Figure 7.** Longitudinal ultrasound image of a lateral aspect of the calcaneal tendon in the peritoneal scaffold group at 60 days. Homogenous fiber pattern with a hyperechoic area.



**Figure 8.** Longitudinal ultrasound image of a lateral aspect of the calcaneal tendon in the peritoneal scaffold with the PRP group at 60 days. Homogenous fiber pattern with a small hypoechogenic area.



## Discussion

Tendon regeneration is a complex and very slow process. Several biologic or synthetic scaffold devices for tendon augmentation were used to provide more effective management and increased healing rates (Walden et al., 2016). A successful restoration with a good outcome should have suitable durability, tension, and strength to meet the dynamic workload (Jahani et al., 2015). In the current trial, results showed that treatment with the scaffold of autologous peritoneum has positively accelerated the healing of the ruptured tendon. This outcome might provide evidence that scaffold can serve as temporary supportive materials for the host tissue in the processes of growth and repairing. Furthermore, the using of PRP for augmentation of the transected tendon might provide advantageous effects on the mechanical properties of the tendon. Clinical observation reveals improvement in the gait and gradual decreases of lameness especially at day six post-surgery in peritoneal scaffold and PRP group. This may be attributed to the role of the peritoneal scaffold as a protective shield, which decreases the adhesion between the tendon and the surrounding region (Castillo et al., 2019). Also, the peritoneal scaffold might have a curative effect due to the proliferation and migration of fibroblasts. For instance, in addition to the extracellular matrix synthesis, rapid degradation of the implanted scaffold was determined; thus, in treated groups, there was an early improvement in the mechanical function of tendon and the signs of lameness subsided rapidly (Bellenger, 2003). Moreover, the addition of PRP acts as a fibrin tissue adhesive, which increases the tensile strength of the tendon and improved gait (Sarrafian et al., 2010). Similarly, a recent study indicated the

effective role of using the PRP for repairing digital flexor tendons in rabbits (Sara et al., 2017). Grossly, adhesion is the most important clinical concerns in tendon repair, which is mainly related to unsuccessful functional outcome (Fahie, 2005). The autologous peritoneum scaffold augmented with PRP acts as a protective shield and contribute to overcome adhesion with the neighboring tissue; consequently, keeping the gliding property of the tendon (Kewa et al., 2011; Elenes et al., 2012). By comparison with the control group, the detected degree of adhesion was lesser in the peritoneal scaffold group, which allows to earlier return to the functional activity of the treated leg (Hajipour, 2016).

In all groups, histopathological examination revealed the presence of matured granulation tissue and inflammatory response in the first 15 days with a complete remodeling of injured edges. Besides, there was an extension of the fibrous extracellular matrix between the wound edges; furthermore, a complete maturation of collagen sheets with strength and stretching of wound borders. The previously described processes indicating a completed healing process is evident at the extracellular and cellular levels. The healing process might be enhanced by growth factors that present in PRP; for instance, tumor necrosis factor alpha (Moshiri and Oryan, 2013). Our results in the peritoneal scaffold group demonstrated physiological inflammatory reactions rather than inflammatory processes against pathogens. This observation might be attributed to the positive impact of PRP by initiating the healing process through activation of the inflammatory reaction mediating by interleukin-6 (IL-6). Furthermore, the PRP promotes inflammatory reaction by activation of oxygen free radicals that plays an import-

ant role in the elimination of pathogens from the contaminated surgical wound (Sample et al., 2018). The effect of PRP might be referred to its content of numerous growth factors including platelet-derived growth factor (PDGF), transforming growth factor- $\beta$  (TGF- $\beta$ ), vascular endothelial growth factor (VEGF), epidermal growth factor (EGF), insulin-like growth factor (IGF) and fibroblast growth factor (FGF). These factors have the potency to initiate and accelerate the healing phases through the enhances of angiogenesis, cellular mitosis, and formation of new sheets of collagen fibers (Najafbeygi et al., 2017). In this study, PRP treatment demonstrated complete healing and the affected tissue returned to its normal feature. PRP contains factors, such as IL-6 and IL-12, where these factors found to be influencing the transforming of a tendocyte into a fibroblast, which is responsible for remodeling precursors of collagen fibers into type I collagen fibers (Moshiri and Oryan, 2013). Therefore, our results indicated that regeneration with the using of PRP is much more effective than using peritoneal scaffold alone. The using of PRP along with peritoneal graft might contribute in the remodeling of extracellular matrix components, increase collagen fiber production and deposition, earlier granulation tissue maturation and organization (Cai et al., 2019; Sarafian et al., 2010; Hosgood, 2003).

In all groups, the ultrasonographic examination exhibited thickening of the treated tendon in which continued to be detectable to the end of the study. However, thickening in the control group was much more than the treatment groups, a similar observation was previously reported Fredberg and Bolvig (2002). Another previous work stated that the increased tendon thickness is a conse-

quence of the local inflammation, which is usually accompanied by edema (Rumack et al., 2005). Recent work suggested that the increased tendon size, in both acute and chronic tendinopathies, favor sonography at the affected site. For instance, the increased tendon size in acute tendinitis is a consequence of haemorrhage and edema; however, in chronic tendinitis, the presence of fibrous tissue, intra-tendinous calcification, and degenerative changes, including increased proteoglycan content, loss of collagen organization and bundling, and myxomatous degeneration tend to cause a permanent thickening in the affected tendon (Macdugall et al., 2018).

Sonographic examination in both the control group (15 and 30 days post-surgery) and in the first and second treated group (15 days post-surgery) showed a heterogeneous fiber pattern in the course of the tendon. It has been suggested that the mottled or heterogeneous fiber pattern might be associated with several disorders such as fiber disruption, intra-tendinous haemorrhage, disorganization of collagen fibers after surgery (Rumack et al., 2005; Macdugall et al., 2018). Whereas, the improved tendon pattern occurs early (30 days) in the peritoneal scaffold with the PRP group, which indicates that PRP improved the healing process. However, in the peritoneal scaffold group, the inflammation persisted, evident as small hypochoic areas, even at the 30 days post-surgery. These results are similar to those reported in a previous study specified that the injured Achilles tendon might return to its normal echogenicity after 29 days of treatment (Chamberlain et al., 2013).

The utilizing of peritoneum graft supported with platelets-plasma rich protein (PRP) has a positive impact on acceleration

and improvement of Achilles tendon repair.

### Acknowledgments

We would like to thank the College of Veterinary Medicine, Assistant professor Dr. Hana Ismail, Dept. of Pathology; Dr. Isam Sharum for his support during the research period.

### Conflict of Interest

The authors declared that there is no conflict of interest.

### References

- Bellenger, C. (2003). Abdominal wall In: Slatter D (ed): Textbook of Small Animal Surgery. 3rd ed. Saunders, Philadelphia. USA. p 177.
- Bellido, C., Abellán, C., Molina A., Blanco, A, and Moyano, R. (2018) .Histopathological study of the Achilles tendon after exposure to bisphenol-A and its subsequent treatment with platelet growth factors..*Vet Arhiv*,88(1),21-35. <https://doi.org/10.24099/vet.arhiv.160920>
- Baltzer, WI., Rist, P.(2009). Achilles tendon repair in dogs using the semitendinosus muscle: surgical technique and short-term outcome in five dogs. *Vet Surg*, 38(6),770-779. <https://doi:10.1111/j.1532-950X.2009.00565.x>.
- Cai, Y., Sun, Z., Liao, B., Song, Z., Xiao, T. and Zhu, P.( 2019). Sodium hyaluronate and platelet-rich plasma for partial-thickness rotator cuff tears. *Med Sci Sports Exerc.*, 51(2), 227–233. <https://doi:10.1249/MSS.0000000000001781>.
- Case, J.B, Palmer, R., Valdes-Martinez, A., Egger, E.L and Haussler, K.K 2013. Gastrocnemius tendon Sstrain in a dog treated with autologous mesenchymal stem cells and a custom orthosis. *Vet. Surg.*, 42,355-360. <https://doi:10.1111/j.1532-950X.2013.12007.x>
- Chamberlain, Connie, S., Duenwald-Kuehl, Sarah, E., Okotie, Gregory, M., Brounts, Sabrina, H., Baer, Geoffrey, S., and Vanderby, R. (2013). Temporal healing in rat achilles tendon: Ultrasound correlations. *Ann Biomed Eng.*,41(3), 477–487. <https://doi:10.1007/s10439-012-0689-y>.
- Canapp, S.O., Canapp, D.A., Ibrahim, V., Carr, B.J., Cox, C, Barrett, J.G. (2016) The use of adipose-derived progenitor cells and platelet-rich plasma combination for the treatment of supraspinatus tendinopathy in 55 dogs: A retrospective study. *Front Vet Sci* .,9 (3),61. <https://doi:10.3389/fvets.2016.00061>.
- Castillo, J.M., Flores-Plascencia, A., Perez-Montiel, M.D., Garcia, S., Vergara, N., Perez-Blanco, A. and Sanchez-Valdivieso, E.A. (2019) Parietal peritoneum graft for duodenum injuries in an animal model. *ABCD Arq Bras Cir Dig.*,32(1),e1418. <https://doi:10.1590/0102-672020180001e1418>
- Denitsa, D., Sebastian, A.M., Martin, M, Christopher H.E. (2015) Biologics for tendon repair. *Adv Drug Deliv Rev.*,84,222–239.<https://doi.org/10.1016/j.addr.2014.11.015>
- Elenes, EY; Hunter, SA; Boivin, G.P., Laughlin, R.T.(2012) Prevention of Peritendinous Adhesions using Peritoneal Membrane Allograft in Flexor Tendon Repair. Annual Meeting.
- Fahie, M.A.(2005) Healing, diagnosis, repair, and rehabilitation of tendon conditions. *Vet Clin Small Anim Pract.* 35(5),1195–1211. <https://doi:10.1016/j.cvsm.2005.05.008>.
- Fredberg, U., Bolvig, L.(2002)Significance of ultrasonographically detected asymptomatic tendinosis in the patellar and Achilles tendons of elite soccer players: A longitudinal study. *Am J Sports Med.*,30(4),488–91. <https://doi:10.1177/03635465020300040701>.
- Greca, F.C., Ramose, E.J., Dallolmo, V.C. Silva, AP, Mima, W.H., Okawa, L., Alencar, T.G.(2005) Evaluation of porcine small intestinal submucosa in Achilles Tendon Repair. *J Appl Res.*, 5 ( 1), 115-123.
- Hosgood, G.( 2003) Wound repair and specific tissue response to injury. In: Textbook of Small Animal Surgery Slatter D .(3rd ed) Saunders, Philadelphia.USA.p. 66-84, 571-603.
- Hajipour, ML.( 2016) Gliding properties of the flexor tendon in zone 2:tendon repair and pulley resection. PhD. Thesis, University of Leicester .p.26-36.
- Jahani, S.I., Moslemi, H.R., Dehghan, M., Sedaghat, R., Nezhad, R.M , Moghaddam D R (2015)The effect of butyric acid with autogenous omental graft on healing of experimental Achilles tendon



- injury in rabbits. *Iran J Vet Res*, 16(50), 100-104. PMID: 27175160
- Kewa, S.J., Gwynne, J.H., Enea, D., Abu-rub, M. (2011) Regeneration and repair of tendon and ligament tissue using collagen fiber biomaterials. *Acta Biomaterialia*, 7, 3237–3247. [https://doi: 10.1016/j.actbio.2011.06.002](https://doi.org/10.1016/j.actbio.2011.06.002).
- Kramer, M., Gerwing, M., Hach, V., Schimke, E. (1997) Sonography of the musculoskeletal system in dogs and cats. *Vet Radiol Ultrasound*, 38, 139–149. [https://doi: 10.1111/j.1740-8261.1997.tb00829.x](https://doi.org/10.1111/j.1740-8261.1997.tb00829.x).
- Kramer, M., Gerwing, M., Michele, U., Schimke, E., Kindler, S. (2001) Ultrasonographic examination of injuries to the calcaneal tendon in dogs and cats. *J Small Anim Pract*, 42, 531–535.
- Konig, H.E., Liebich, H.G., Maierl, J. (2007) Hind limb or pelvic limb. In: Konig, H.E. and Liebich, H.G. *Veterinary Anatomy of Domestic Mammals*. (3rd ed.) Stuttgart GmbH, Germany, PP. 249-276.
- Lamb, C., Duvernois, A. (2005) Ultrasonographic anatomy of the normal canine calcaneal tendon. *Vet Radiol Ultrasound*, 46(4), 326–330. [https://doi: 10.1111/j.1740-8261.2005.00061.x](https://doi.org/10.1111/j.1740-8261.2005.00061.x)
- Millis, D.L., Levine, D., Taylor, R.A. (2004) *Canine Rehabilitation and Physical Therapy* 1st ed. Elsevier, USA. p. 182.
- Malik, A., Tabassum, R., Ahmad, M. (2013) Autogenous platelet-rich plasma in the healing of bone defects. *World J of Med and Medical Sci. Res.*, 1 (5), 082-084.
- Moshiri, A., Oryan, A. (2013) Tendon and ligament tissue engineering, healing and regenerative medicine. *J Sports Med. Doping Stud.*, 3(2), 1-18. [https://doi: 10.4172/2161-0673.1000126](https://doi.org/10.4172/2161-0673.1000126)
- McDougall, R.A., Canapp, S.O., Canapp, D.A. (2018) Ultrasonographic findings in dogs treated with bone marrow aspirate concentrate and platelet-rich plasma for a supraspinatus tendinopathy: A retrospective study. *Front Vet Sci*, 5, 98. [https://doi: 10.3389/fvets.2018.00098](https://doi.org/10.3389/fvets.2018.00098)
- Najafbeygi, A., Fatemi, M.J., Lebaschi, A.H., Mousavi, S.J., Husseini, S.A. and Niazi, M., (2017). Effect of basic fibroblast growth factor on achilles tendon healing in rabbit. *World J Plast Surg*. 6(1), 26-32.
- Rumack, M.C., Wilson, S. R., Charboneau, J.W. (2005). *Diagnostic Ultrasound*. 3rd ed. USA. p. 909.
- Rivers, B.J., Walter, P.A., Kramek, B., Wallace, L. (1997) Sonographic findings in canine common calcaneal tendon injury. *Vet Comp Orthop Traumatol*, 10, 49–57.
- Spinella, G., Tmburror, R., Loprete, G., Vilar, J.M., Valentini, S. (2010) Surgical repair of Achilles tendon rupture in dogs: a review of the literature, a case report: *Vet Med (Praha)*, 55(7), 303–310. [https://doi: 10.17236/sat00035](https://doi.org/10.17236/sat00035).
- Sara, J., Amirata V., Raziallah, J. Javad, A. (2017) Autologous platelet rich plasma injection improves early tendon repair in rabbits: a histopathological and biomechanical study. *Iran J Vet Sci Technol*, 12(1), 40-45.
- Sample, S.J., Racette, M.A., Hans, E.C., Volstad, N.J., Schaefer, S.L., Bleedorn, J.A., Jeffrey P. Little, J.P., Kenneth, R., Waller, K.R., (2018) Use of a platelet-rich plasma-collagen scaffold as a bio-enhanced repair treatment for management of partial cruciate ligament rupture in dogs. *PLOS ONE*, 13(6), 1-22. [https://doi:10.1371/journal.pone.0197204](https://doi.org/10.1371/journal.pone.0197204).
- Sarrafian, T. L., Wang, Hackett, H. S., Yao, J.Q., Shih, M., Ramsay, R.L., Turner, A.S., (2010) Comparison of Achilles tendon repair techniques in a sheep model using a cross-linked acellular porcine dermal patch and platelet-rich plasma fibrin matrix for augmentation. *J Foot Ankle Surg.*, 45, 128–134. [https://doi: 10.1053/j.jfas.2009.12.005](https://doi.org/10.1053/j.jfas.2009.12.005).
- Suvarna, S.K., Layton, C., Bancroft, J.D., Bancroft's (2013) *Theory and Practice of Histological Techniques*. 7th ed. Churchill Livingstone Press, USA. P. 12-32.
- Taniguchil, Y.U., Yoshioka, T., Kanamori, A. (2018) Intra-articular platelet-rich plasma (PRP) injections for treating knee pain associated with osteoarthritis of the knee in the Japanese population: a phase I and IIa clinical trial. *Nagoya J Med Sci*. 80, 39–51. [https://doi:10.18999/nagjms.80.1.39](https://doi.org/10.18999/nagjms.80.1.39).
- Walden, G., Liao, X.B., Donell, S., Raxworrthy, M.J., Graham, P., Riley, G.R., Saeed, A. (2017) A clinical, biological and biomaterials perspective into tendon injuries and regeneration. *Tissue Eng Part B*, 23(1), 44-58. [https://doi:10.1089/ten.TEB.2016.0181](https://doi.org/10.1089/ten.TEB.2016.0181)

