

Clinical, Radiological and Microscopical Findings of Chondrosarcoma in a Cat

Sara Shokrpour^{1*}, Behzad Pourreza², Mina Khodadadi³ , Masoumeh Moradi Ozarlou⁴,
Reza Khoshvaghti⁵, Bita Fazel⁵

1. Department of Pathology, Faculty of Veterinary Medicine, University of Tehran, Tehran, Iran
2. Department of Radiology and Surgery, Faculty of Veterinary Medicine, University of Tehran, Tehran, Iran
3. Department of Basic Sciences, Faculty of Veterinary Medicine, University of Tehran, Tehran, Iran
4. Department of Pathobiology, Faculty of Veterinary Medicine, University of Tabriz, Tabriz, Iran
5. Faculty of Veterinary Medicine, University of Tehran, Tehran, Iran

Abstract

Chondrosarcoma is an uncommon malignant neoplasm in which the neoplastic cells produce chondroid and varying amounts of matrix. This tumor is the second most common primary skeletal tumor in animals. In our case, radiological and histopathological findings supported the final diagnosis of chondrosarcoma in a six-year-old male cat weighing 6.3 kg with a large and solitary mass in the right humerus. The shoulder joint had a limited range of motion. Radiographs were obtained from the raised growth. The mass was surgically excised for histopathological evaluation. Microscopically, the mass was composed of bundles and nests of neoplastic mesenchymal cells. Histopathologically, multiple-sized lacunae within a homogenous cartilage matrix were observed. There was marked anisocytosis and anisokaryosis. Neoplastic chondrocytes and oval cells with 1 to 3 nucleoli were seen. Based on the macroscopic, radiological, and cartilaginous differentiation of tumor cells and matrix, the mass was diagnosed as well-differentiated chondrosarcoma.

KEYWORDS: Cat, Chondrosarcoma, Histopathology, Radiology, Surgery

Correspondence

Seyed Mostafa Peighambari, Department of Pathology, Faculty of Veterinary Medicine, University of Tehran, Tehran, Iran Tel: +98 (021) 61117065, Fax: +98 (021) 66933222, Email: shokrpour@ut.ac.ir

Received: 2021-02-13

Accepted: 2021-04-26

Copyright © 2021. This is an open-access article distributed under the terms of the Creative Commons Attribution- 4.0 International License which permits Share, copy and redistribution of the material in any medium or format or adapt, remix, transform, and build upon the material for any purpose, even commercially.

How to Cite This Article

Shokrpour, S., Pourreza, B., Khodadadi, M., Moradi Ozarlou, M., Khoshvaghti, R., Fazel, F. (2021). Clinical, Radiological and Microscopical Findings of Chondrosarcoma in a Cat. Iranian Journal of Veterinary Medicine, 15(4), 452-456.

Case History

Skeletal neoplasia most commonly occurs in the femur and humerus (Ettinger, Feldman, & Cote, 2016; Withrow, Vail, & Page, 2013). Chondrosarcoma is an uncommon malignant neoplasm in which the neoplastic cells produce chondroid and fibrillar matrix (Durham, Popovitch, & Goldschmidt, 2008). This tumor is the most important primary skeletal tumor in veterinary medicine (Nielsen, 1976; Rozeman, Cleton-Jansen, & Hogendoorn, 2006). Chondrosarcomas are usually diagnosed in cats 9 years of age or older, with an average age of 9.6 years. This tumor frequently occurs in males than in females. Feline chondrosarcoma appears to grow slowly and invade locally—but rarely metastasizes (Durham *et al.*, 2008). This paper is about the macroscopic, surgical, radiological, and histopathological findings of chondrosarcoma in a cat.

Clinical Presentation

In August 2020, a six-year-old male cat weighing 6.3 kg with a large and solitary mass in the right humerus was referred to our clinic. In the clinical examination, the cat was responsive. Its pulse and respiratory rate were normal, and signs of pain on palpation were detected around the affected area. Limited joint mobility in the shoulder joint, especially in flexion mode, was seen. Macroscopically, a firm swelling was observed in the proximal right humerus. The axillary lymph nodes had normal size

([Figure 1A](#)). Radiographs of the right hand revealed osseous lytic and proliferative changes of the proximal humerus. The diameter of the mass was about 10 cm. Though radiological findings suggested osteochondroma ([Figure 1B](#)).

Finally, limb amputation was elected ([Figure 1C](#)). Anesthesia was induced by intravenous injection of ketamine (10 mg/kg; Alfasan, Woerden, the Netherlands) and diazepam (0.5 mg/kg; Caspian Tamin Pharmaceutical, Rasht, Iran) and maintained with 1%-1.5% isoflurane (Baxter, Norfolk, UK) in oxygen.

Analgesia was provided by subcutaneous injection of ketoprofen (2 mg/kg; Razak, Tehran, Iran) once daily for three days. Tissue samples of the mass were fixed in 10% neutral buffered formalin and routinely processed, dehydrated, and embedded in the paraffin wax, sectioned at 5 μ m in thickness (Rotary Microtome RM2145, Leica), and stained with hematoxylin and eosin (H&E) stain. The cat recovered uneventfully.

Diagnostic testing

Microscopically, the mass was composed of bundles, nests, and sheets of neoplastic chondrocytes that produced a basophilic cartilage matrix. However, the mass was poorly vascular, and islands of chondrocytes were separated by fibrous connective tissue ([Figure 1D](#)).

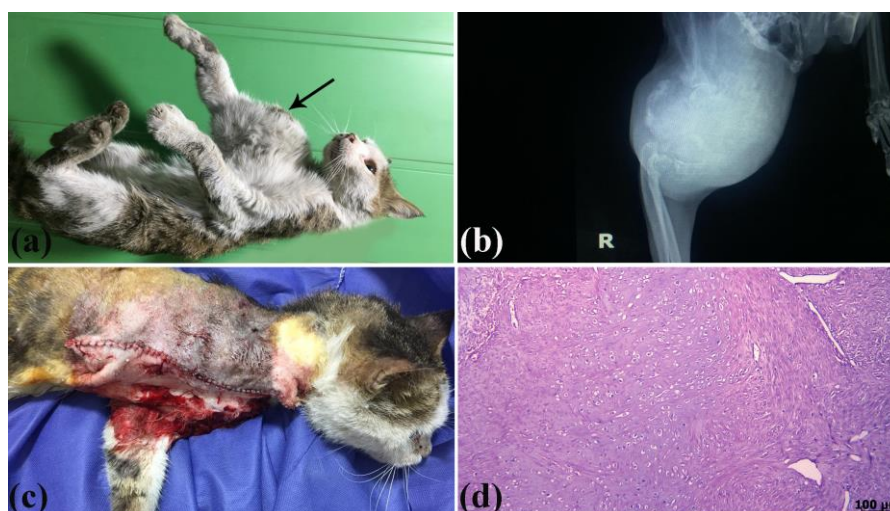


Figure 1. A, the mass on the right humerus (arrow). B, the radiograph of the mass. C, limb amputation. D, histopathological section of chondrosarcoma, the nests, sheets of neoplastic mesenchymal cells, and chondroid matrix, H&E.

The biopsy specimens displayed areas of necrosis (Figure 2A). Microscopic evaluation revealed variably sized lacunae within a fibrillar matrix. Individual neoplastic chondrocytes had distinct cellular borders and abundant eosinophilic cytoplasm. There was marked anisocytosis and anisokaryosis. Pleomorphic

cells with 1 to 3 nucleoli were also observed (Figures 2B and 2C). The mitotic figures were less than 1 per high-power field (HPF; Figure 2D). Based on the histopathological findings, the diagnosis of the mass was confirmed as well-differentiated chondrosarcoma.

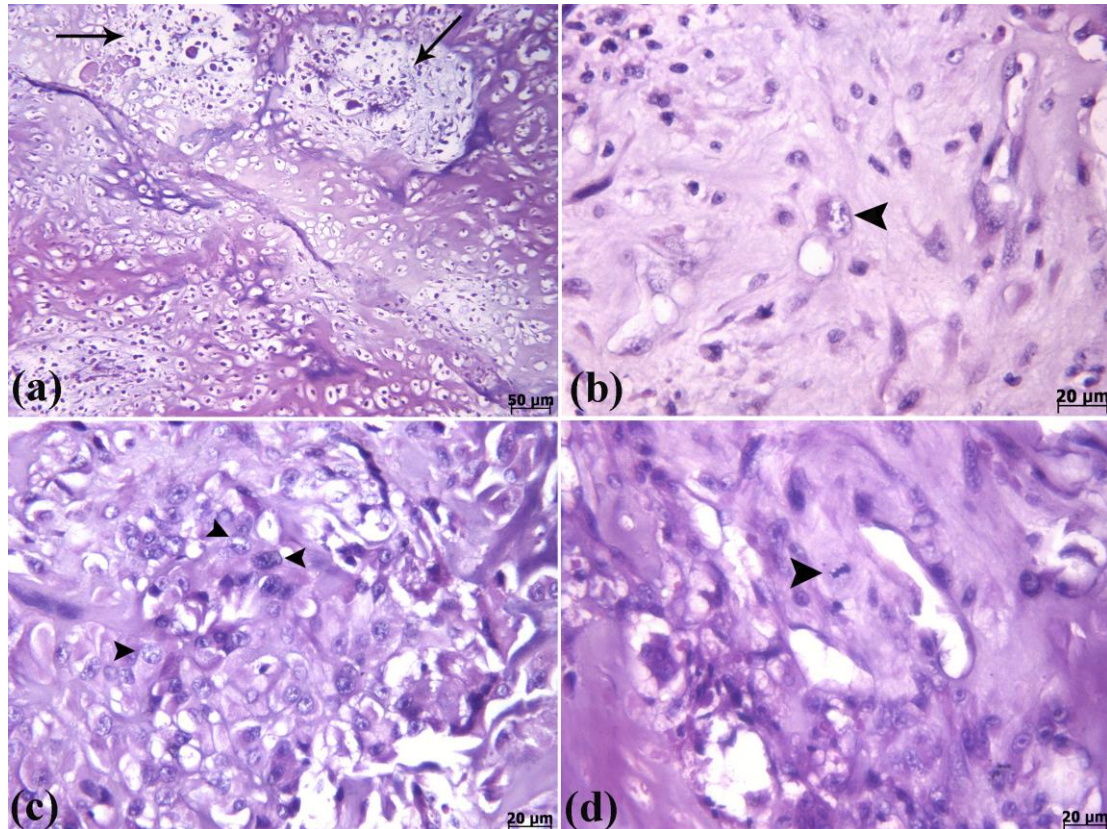


Figure 2. A and B, histopathological sections of chondrosarcoma. A, multifocal necrosis (arrows). B, bizarre neoplastic chondrocytes. C, pleomorphic to oval cells with 1 to 3 nucleoli (arrowheads). D, mitotic figure (arrowhead), H&E.

Assessments

Skeletal neoplasia is a rare phenomenon in cats. Osteosarcoma is the most common primary malignant bone tumor in this species, while fibrosarcoma and chondrosarcoma are the second and third most common cancers (Withrow, 2007). Chondrosarcoma may originate from the flat and long bones in cats (Merchav, Dank, Aizenberg, & Shahar, 2005). This study is about the presence of chondrosarcoma in a cat. There is only one report about chondrosarcoma in a cat (Merchav *et al.*, 2005). In our case, limb amputation was performed. Although information about other possible therapies except for surgical ones in this case (such as radiation) is still limited, following amputation, the survival time seems to be lengthened (Straw, Withrow, Gillette, & McChes-

ney, 1986; Turrel & Pool, 1982). Also, wide surgical excision is a curative therapy for this neoplasm (Durham *et al.*, 2008; FARESE *et al.*, 2009). In cats, metastasis is not very common. As a result, surgical removal is curative (Merchav *et al.*, 2005; Thompson, Pool, & Meuten, 2017).

Lameness and pain on palpation in our case are similar to other cases of chondrosarcoma (Merchav *et al.*, 2005). Microscopically, in chondrosarcoma, there is no osteoid production (Thompson & Dittmer, 2017). In the current case, osteoid was not observed, which was in line with the previous report. Similar to the present case, mitotic figures are low in well-differentiated chondrosarcomas (Thompson & Dittmer,

2017). Two months after surgical treatment, neither recurrence nor metastases were detected in our case. In this case, surgical excision was a treatment of choice (Miller Jr, Griffin, & Campbell, 2012; Nakashima, Unni, Shives, Swee, & Dahlin, 1986).

Conclusion

On the basis of the macroscopic and microscopic characteristics, the cause of this neoplasm remained

unknown. Limb amputation or wide surgical excision is a curative therapy for this tumor.

Acknowledgments

Mr. Samani is thanked for assisting with the histopathological sections.

Conflict of Interest

The authors declare that there are no conflicts of interest.

References

- Durham, A. C., Popovitch, C. A., & Goldschmidt, M. H. (2008). Feline Chondrosarcoma: A Retrospective Study of 67 Cats (1987–2005). *Journal of the American Animal Hospital Association*, 44(3), 124-130. [DOI:10.5326/0440124]
- Ettinger, S. J., Feldman, E. C., & Cote, E. (2016). *Textbook of veterinary internal medicine expert consult*: Saunders.
- Farese, J. P., Kirpensteijn, J., Kik, M., Bacon, N. J., Waltman, S. S., Seguin, B., . . . Withrow, S. J. (2009). Biologic Behavior and Clinical Outcome of 25 Dogs with Canine Appendicular Chondrosarcoma Treated by Amputation: A Veterinary Society of Surgical Oncology Retrospective Study. *Veterinary Surgery*, 38(8), 914-919. [DOI:10.1111/j.1532-950X.2009.00606.x]
- Merchav, R., Dank, G., Aizenberg, I., & Shahar, R. (2005). Chondrosarcoma of the proximal humerus in a cat. *Journal of Small Animal Practice*, 46(9), 454-456. [DOI:10.1111/j.1748-5827.2005.tb00346.x]
- Miller Jr, W. H., Griffin, C. E., & Campbell, K. L. (2012). *Muller and Kirk's Small Animal Dermatology*: Elsevier Health Sciences.
- Nakashima, Y., Unni, K. K., Shives, T. C., Swee, R. G., & Dahlin, D. C. (1986). Mesenchymal chondrosarcoma of bone and soft tissue. A review of 111 cases. *Cancer*, 57(12), 2444-2453. [DOI:10.1002/1097-0142(19860615)57:123.0.CO:2-K]
- Nielsen, S. W. (1976). Comparative Pathology of Bone Tumors in Animals, with Particular Emphasis on the Dog. In E. Grundmann (Ed.), *Malignant Bone Tumors* (pp. 3-16). Berlin, Heidelberg: Springer Berlin Heidelberg. [DOI:10.1007/978-3-642-80997-2_2]
- Rozeman, L. B., Cleton-Jansen, A. M., & Hogendoorn, P. C. W. (2006). Pathology of primary malignant bone and cartilage tumours. *International Orthopaedics*, 30(6), 437-444. [DOI:10.1007/s00264-006-0212-x]
- Straw, R. C., Withrow, S. J., Gillette, E. L., & McChesney, A. E. (1986). Use of radiotherapy for the treatment of intranasal tumors in cats: six cases (1980-1985). *Journal of American Veterinary Medicine Association*, 189(8), 927-929.
- Thompson, K., Pool, R., & Meuten, D. (2017). Tumors in domestic animals. In (7 ed.): Ames, Iowa: Iowa State Press.
- Turrel, J. M., & Pool, R. R. (1982). Primary bone tumors in the cat: a retrospective study of 15 cats and a literature review. *Veterinary Radiology*, 23(4), 152-166. [DOI:10.1111/j.1740-8261.1982.tb01099.x]
- Withrow, S. J. (2007). *Withrow and MacEwen's small animal clinical oncology*: Elsevier Health Sciences. [DOI:10.1002/9781119181200]
- Thompson, KG., Dittmer, KE. (2017) Tumors of Bone. In: Tumors in Domestic Animals, Meuten DJ, (ed), 5th ed. Wiley Blackwell. Ames, IA, USA, 394-400. [DOI:10.1002/9781119181200]



یافته‌های بالینی، رادیولوژی و میکروسکوپی کندروسارکوم در یک گربه

سارا شکرپور^۱، بهزاد پوررضا^۲، مینا خدادادی^۳ ، معصومه مرادی ازولو^۴، رضا خوشوقتی^۵، بیتا فاضل^۵

^۱گروه پاتولوژی، دانشکده دامپزشکی دانشگاه تهران، تهران، ایران

^۲گروه رادیولوژی و جراحی، دانشکده دامپزشکی دانشگاه تهران، تهران، ایران

^۳گروه علوم پایه، دانشکده دامپزشکی دانشگاه تهران، تهران، ایران

^۴گروه پاتوبیولوژی، دانشکده دامپزشکی دانشگاه تبریز، تبریز، ایران

^۵فراخ‌التحصیل دانشکده دامپزشکی دانشگاه تهران، تهران، ایران

(دریافت مقاله: ۲۵ بهمن ماه ۱۳۹۹، پذیرش نهایی: ۰۶ اردیبهشت ماه ۱۴۰۰)

کندروسارکوم توموری بدخیم با وقوع کم است که سلول‌های نئوپلاستیک، کندروئید و ماتریکس فیبریلار تولید می‌کنند. این تومور دومین تومور معمول اسکلتی بعد از استئوسارکوم در انسان و حیوانات است. در این حیوان، با توجه به یافته‌های رادیولوژی و هیستوپاتولوژی، کندروسارکوم تشخیص داده شد. یک مورد گربه نر با یک توده بزرگ در اندام حرکتی قدامی با حرکت محدود در مفصل شانه ارجاع داده شد. رادیوگراف‌هایی از مفصل شانه و اندام حرکتی قدامی راست تهیه شد. توده به روش جراحی برداشته شد و برای بررسی‌های هیستوپاتولوژی به آزمایشگاه ارسال گردید. در بررسی‌های میکروسکوپی، توده مذکور از طناب‌ها و صفحاتی از سلول‌های مزانشیمی نئوپلاستیک تشکیل شده بود. از نظر هیستوپاتولوژیک، تعداد زیادی لاکونا با سایز متفاوت در ماتریکس غضروفی هیالینه و هموژنوس مشاهده شد. کندروسیت‌های نئوپلاستیک و سلول‌های بیضی تا پلئومورفیک با ۱ تا ۳ هسته دیده شدند. بر اساس یافته‌های ماکروسکوپی، رادیولوژی و تمایز غضروفی سلول‌های توموری و ماتریکس، توده مذکور کندروسارکوم تمایز یافته تشخیص داده شد.

واژه‌های کلیدی: گربه، کندروسارکوم، هیستوپاتولوژی، رادیولوژی، جراحی