Original Article

Effects of Iron Overload on Cardiac Health and the Protective Role of Betaine in Male Rats

Haider Mawash*, Saif Al-Aqbi

Department of Pathology and Poultry Disease, Faculty of Veterinary Medicine, University of Kufa, Kufa, Iraq.

Use your device to scan and read the article online

How to Cite This Article Mawash, H., & Al-Aqbi, S. (2026). Effects of Iron Overload on Cardiac Health and the Protective Role of Betaine in Male Rats. *Iranian Journal of Veterinary Medicine, 20*(5), 1053-1064. http://dx.doi.org/10.22034/ijvm.20.5.1006081

http://dx.doi.org/10.22034/ijvm.20.5.1006081

ABSTRACT

Background: Iron is a vital element that takes part in many biological processes; nevertheless, the excess of iron in the body is a serious toxicological risk as it causes oxidative stress and, consequently, damage to the systemic organs. Betaine is a naturally occurring, non-toxic substance that is found in various organisms, and is known to stabilize protein structures and improve the antioxidant defense mechanisms of the body.

Objectives: The aim of the study was to examine the protective role of betaine against cardiac injury and systemic toxicity in case of chronic iron overload using an animal model.

Methods: Thirty-two adult male albino rats were randomly divided into four groups: a negative control group, an iron-overload group (receiving iron sucrose), a treatment group (receiving iron sucrose in combination with oral betaine), and a betaine-only group. Over a 30-day experimental period, systemic iron levels, biomarkers of oxidative stress, and molecular indicators of cardiac injury were evaluated. The cardiac tissues were also subjected to histopathological examination to determine the structural changes.

Results: Iron overload led to a significant increase in iron storage, with increased oxidative stress markers and cardiac injury markers. Histological examination showed that the iron-overload group had severe myocardial damage and inflammation. Conversely, betaine co-administration had a significant mitigating effect, reducing oxidative stress markers and enhancing iron homeostasis. In addition, cardiac tissue analysis showed that there was no evidence of necrosis or structural damage of the cardiac tissue compared to the iron-only group.

Conclusion: Betaine demonstrates a marked protective effect against iron-induced toxicity. Its cardioprotective effects are explained by its capacity to maintain iron homeostasis, decrease oxidative stress, and preserve cellular structural integrity. These results indicate that betaine can be used as a promising therapeutic adjunct in the management of conditions induced by iron overload.

Keywords: Betaine, Iron overload, Cardio protection, Oxidative stress, Iron metabolism

Article info:
Received: 15 Apr 2026
Accepted: 17 Jun 2026
Publish: 01 Sep 2026

*** Corresponding Author:**
Haider Mawash
Address: *Department of Pathology and Poultry Disease, Faculty of Veterinary Medicine, University of Kufa, Kufa, Iraq.*
Phone: *+96 (47) 723823031*
E-mail: *Haidera.mawash@student.uokufa.edu.iq*

Copyright © 2026 The Author(s);
This is an open access article distributed under the terms of the Creative Commons Attribution License (CC-By-NC: https://creativecommons.org/licenses/by-nc/4.0/legalcode.en), which permits use, distribution, and reproduction in any medium, provided the original work is properly cited and is not used for commercial purposes.

Introduction

Iron is a basic transition metal and one of the most common elements in the Earth's crust, which combines the essential biological roles with significant toxicological risks (Dev et al., 2017; Muckenthaler et al., 2017). It is an essential cofactor in cellular metabolism, DNA synthesis, and respiration, and plays a key role in oxygen delivery via hemoglobin (Read et al., 2021; Soares et al., 2016). One of the major properties of iron is the possibility to exist in two oxidation states: the ferric (Fe^{3+}) storage form and the ferrous (Fe^{2+}) active form (Ru et al., 2024; Vogt et al., 2021).

Iron metabolism is a very controlled phenomenon since an excess in free iron may lead to systemic toxicity. Non-transferrin-bound iron (NTBI) builds up when the ratio of systemic iron to the binding capacity of proteins, such as transferrin and ferritin exceeds the binding capacity (Arosio et al., 2015; Sukhbaatar et al., 2018). Such surplus iron is a catalyst to the Fenton reaction, which causes the production of deadly hydroxyl radicals that initiate lipid peroxidation and subsequent organ dysfunction in the heart, liver, and kidneys (Gammella et al., 2016; Roemhild et al., 2021; Vogt et al., 2021).

Betaine is a stable, non-toxic, natural compound that is present in different organisms, and was first discovered in the sugar beets (Arumugam et al., 2021; Hoffman et al., 2009). It acts as a compatible osmolyte and a donor of methyl groups and plays a key role in osmotic regulation (Willingham et al., 2020; Zhang et al., 2016). Because of its peculiarities, betaine stabilizes protein structures and increases the antioxidant defenses, in particular, the Nrf2-Keap1-ARE signaling pathway (Bellezza et al., 2018; Craig, 2004; Konstantinova et al., 2008). Betaine can prevent cellular apoptosis by inhibiting caspase-3 expression and thus protect vital organs against oxidative stress (Veskovic et al., 2019).

Aims of the study

The main objective of this study was to examine the protective effect of betaine against the multi-organ injury caused by iron.

The study objectives were to measure *BNP* gene expression and troponin C to assess myocardial stress; assess oxidative stress indicators, particularly malondialdehyde (MDA); and monitor systemic iron parameters, including serum iron, ferritin, and transferrin.

Significance and scope

The study is important because it addresses a gap in the literature concerning the combined cardioprotective effects of betaine under chronic iron-overload conditions (Kumfu et al., 2022; Mancardi et al., 2021). Although the role of betaine in hepatic injury is well documented, its systemic regulatory effects on iron flux and cardiovascular stability represent a new aspect of clinical adjunct therapy (Ashtary-Larky et al., 2022; Yousef et al., 2022). The research was carried out using a 30-day experimental model in adult male albino rats.

Materials and Methods

Experimental animals and ethical approval

Thirty-two adult male albino rats weighing 200–250 g were used in this study. The animals were housed under standard environmental conditions (25 ˚C and 30% humidity) and maintained on a 12-hour light/dark cycle at the Faculty of Veterinary Medicine, University of Kufa. All procedures were approved by the Central Bioethics Committee at the University of Kufa. The rats were randomly divided into four equal groups (n=8 per group) for 30 days:

Negative control group (C-): Received intraperitoneal (I.P.) injections of distilled water.

Positive control group (C+): Received injections of iron sucrose (Jamjoom Pharma, Saudi Arabia) at 80 mg/kg body weight every 7 days (Khristian et al., 2024).

Treatment group (iron + betaine): Received iron sucrose (80 mg/kg every 7 days) and oral betaine (Solarbio, China) at 15 mg/kg through oral gavage.

Betaine group: Received only oral betaine (15 mg/kg) daily (Alipourfard et al., 2023).

Sample collection

Anesthesia was induced in the rats on day 30 by intramuscular injection of ketamine (80 mg/kg) and xylazine (8 mg/kg) (Jirkof et al., 2023). Blood was collected by cardiac puncture, and the samples were centrifuged at 3,000 rpm for 10 minutes to obtain serum. Heart tissues were collected and placed in 10% neutral buffered formalin for histopathological examination.

Laboratory analysis

Gene expression (reverse transcription quantitative polymerase chain reaction [RT-qPCR]): Total RNA was isolated from heart tissue using a TRIzol-based kit (ABM, Canada), and the total RNA concentration was measured using a Quantus™ Fluorometer (Promega, USA). Brain-type natriuretic peptide (Bnp) mRNA levels were measured using a Stratagene MX 3000-P cycler (Germany) and normalized to GAPDH as an internal control. Fold changes in gene expression were determined using the $2^{-\Delta\Delta Ct}$ equation, with the positive control group as the calibrator ($2^{-\Delta\Delta Ct}$=1.0000) (Schmittgen et al., 2008).

ELISA Assays: Serum levels of cardiac troponin C, ferritin, transferrin, serum iron, and MDA were determined using specialist rat-specific ELISA kits (Ideal Medica Technologies, China). The samples were read using a Biotek (USA) ELISA reader.

Histopathological study

The fixed heart tissues were dehydrated using varying concentrations of ethanol, cleared with xylene, and embedded in paraffin wax. Sections (4 µm thick) were stained with hematoxylin and eosin (H&E) to assess myocardial health and structural integrity (Bancroft et al., 2013).

A semi-quantitative scoring system was used to assess myocardial damage (0=non-significant occupied lesion - sol, 1=mild pathological changes, 2=moderate pathological changes, 3=severe pathological changes, 4=highly severe pathological changes/tissue damage—point of no return). Five parameters were evaluated: striation loss, interstitial edema, inflammation, hemosiderosis/hemorrhage, and coagulative necrosis (Godbole & Mahajan, 2025).

Statistical analysis

Data were analyzed using GraphPad Prism software, version 10.0. Results are expressed as Mean±SD for eight rats per group (n=8). Differences among the four experimental groups were evaluated using a one-way analysis of variance (ANOVA), followed by Tukey's multiple-comparison test to identify specific group differences. Statistical significance was pre-defined at $P<0.05$. In the figures, significance levels are indicated as highly significant ($P\leq0.0001$) or non-significant (ns).

Results

Bnp mRNA expression

RT-qPCR analysis showed significant changes in the expression of Bnp mRNA among the experiment groups. The Iron group showed a marked increase in Bnp mRNA expression (1.0000±0) in comparison with the other groups. In contrast, co-treatment with iron and betaine significantly reduced its expression levels to 0.0866±0.06738, a highly significant reduction compared with the iron-only group ($P\leq0.0001$). The fold change of the betaine-only group was 0.0586±0.02245, and no significant difference was found between the iron-plus-betaine group and the betaine-only group (Figure 1).

Oxidative stress and cardiac markers (ELISA): biochemical analyses

MDA: Serum MDA concentrations, used as a marker for lipid peroxidation, were significantly elevated in the Iron group (0.7128±0.03273) compared to the negative control group (0.2787±0.02312) ($P\leq0.0001$). Treatment with iron plus betaine significantly lowered MDA levels to 0.3736±0.06149. The betaine-only group showed an MDA level of 0.2535±0.02136, which was not significantly different from the negative control group (Figure 2).

Cardiac troponin C: A marked increase in serum cardiac troponin C was observed in the iron group (145.4789±4.23515) compared to the negative control group (65.507±6.86153) ($P\leq0.0001$). Administration of betaine in the treatment group significantly attenuated this rise, reducing the concentration to 97.0845±7.94158. No significant difference was detected between the betaine-only group (67.338±5.36363) and the negative control group (Figure 3).

Iron homeostasis parameters

Serum ferritin: The iron group exhibited a drastic increase in serum ferritin levels (73.5027±3.49245) compared to the negative control group (27.4402±4.33678) ($P\leq0.0001$). Co-administration of betaine significantly reduced ferritin levels to (39.1749±1.63789). The betaine-only group remained comparable to the control at 26.9299±2.86514 (Figure 4).

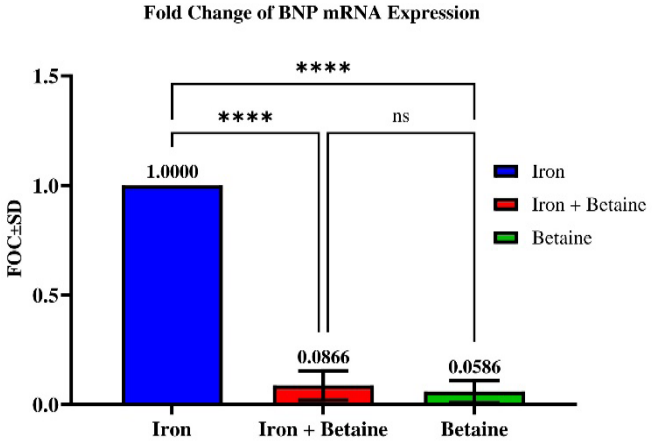

Figure 1. Fold change (FOC) in Bnp mRNA expression

Ns: Not significant.

Note: The bar graph shows relative Bnp mRNA expression (fold change, Mean±SD) in the iron, iron + betaine and betaine groups (n=8), with the Iron group used as the calibrator (1.0000). Statistical comparisons were performed by one-way ANOVA followed by Tukey's multiple-comparison test. ****P≤0.0001.

Transferrin: Serum transferrin levels were significantly depleted in the iron group (1.4423±0.21956) compared to the negative control group (8.8123±0.20971). However, the iron + betaine group showed a significant recovery of transferrin concentrations to 4.9892±0.39967 (P≤0.0001). The betaine-only group (8.9038±0.21956) showed a non-significant difference compared to the negative control group (Figure 5).

Serum iron: Administration of iron significantly increased serum iron levels in the Iron group (31.4387±1.52911) compared to the negative control group (10.0215±1.46018). Treatment with betaine maintained serum iron at a significantly lower level (12.293±1.16663) than in the iron-only group (P≤0.0001). The betaine-only group had a serum iron level of 9.5712±1.20286 (Figure 6).

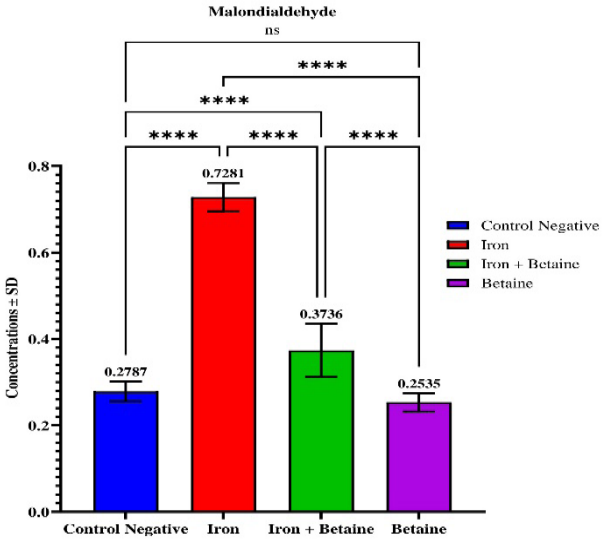

Figure 2. Serum MDA concentrations in the experimental groups

Ns: Not significant.

Note: The bar graph shows MDA concentrations (nmol/mL; Mean±SD) in Control Negative, iron, iron + betaine and betaine groups (n=8). Statistical comparisons were performed by one-way ANOVA followed by Tukey's multiple-comparison test. ****P≤0.0001.

Table 1. Semi-quantitative histopathological lesion scores and tissue damage percentages in different experimental groups.

Groups / Scores	Control	Iron	Iron + Betaine	Betaine
Anucleate cardiac myocyte/losses striated	0	1	1	0
Edema	0	2	1	0
Inflammation	0	3	0	0
Hemosiderosis+ hemorrhage	0	4	0	0
Cardiac muscle fiber coagulative necrosis	0	4	0	0
Total tissue damage (%)	0	70-75%	5-10%	0

Note: Scoring was based on a 5-point scale: 0 = No significant occupied lesion (SOL); 1 = Mild pathological changes; 2 = Moderate pathological changes; 3 = Severe pathological changes; 4 = Highly severe pathological changes or tissue damage (Point of no return).

Histopathological findings

Negative control and betaine groups: Microscopic examination of heart sections from the negative control and betaine-only groups revealed normal histological architecture, characterized by healthy texture of cardiac muscle fibers without significant lesions (Figure 7).

Iron (positive control) group: Heart sections showed extensive coagulative necrosis, loss of striations in cardiomyocytes, and prominent neutrophilic infiltration in the interstitium. Hemorrhagic areas, interstitial edema, and hemosiderin deposition (iron buildup) were also observed (Figure 8).

Iron + betaine group: Sections from this group showed significant attenuation of cardiac injury with betaine treatment. Tissue fragmentation was significantly reduced, and partial restoration of the normal myocyte architecture was observed compared with the positive control group. Slight degenerative changes and residual interstitial separations were also observed (Figure 9).

Betaine-only group: Microscopic examination of cardiac sections from the betaine-only group revealed normal myocardial architecture comparable to that of the negative control group, without significant lesions (Figure 10).

Histopathological scoring (Table 1) showed also observed. The iron-only group was the most severely affected, with a total tissue damage percentage of 74.375% and grade 4 ("point of no return") coagulative necrosis and hemosiderosis. In contrast, the Iron + betaine group

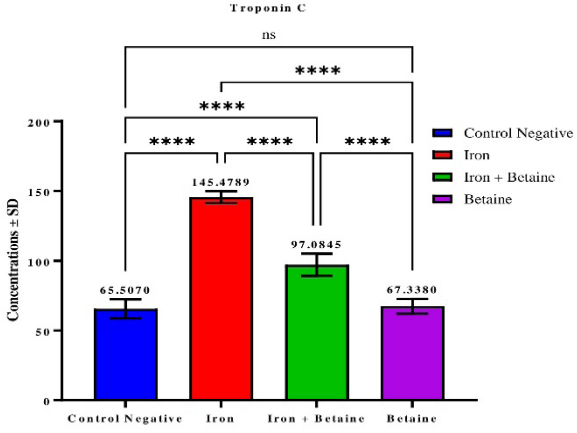

Figure 3. Serum troponin C concentrations in the experimental albino rat groups

Ns: Not significant.

Note: The bar graph shows serum cardiac troponin-C concentrations (pg/mL) in the four experimental group (n=8). Values are expressed as the Mean±SD and were determined using an ELISA. Significant differences are indicated by ****P≤0.0001.

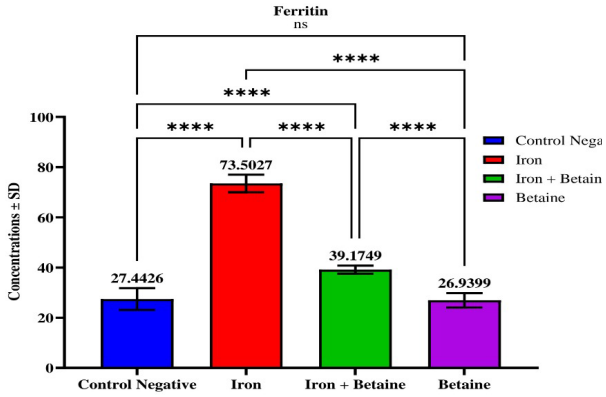

Figure 4. Serum ferritin concentrations in the experimental albino rat groups

Note: ns: Not significant.

Note: The bar graph shows ferritin concentrations (ng/mL; Mean±SD) in Control Negative, iron, iron + betaine and betaine groups (n=8), measured by ELISA. Statistical comparisons were performed by one-way ANOVA followed by Tukey's multiple-comparison test. ****P≤0.0001.

showed significant attenuation of injury across most parameters. Lesions were significantly reduced, and only a few parameters remained slightly affected (grade 1) compared with the positive control group (Figure 11). Tissue damage was very slight (6.875%).

Discussion

The findings of this research show that long-term iron exposure causes systemic toxicity characterized by severe oxidative stress, mechanical and structural strain, and substantial damage to heart tissue. Betaine, a multi-target protective agent, was able to counter these pathological alterations by modulating iron homeostasis and improving antioxidant defenses.

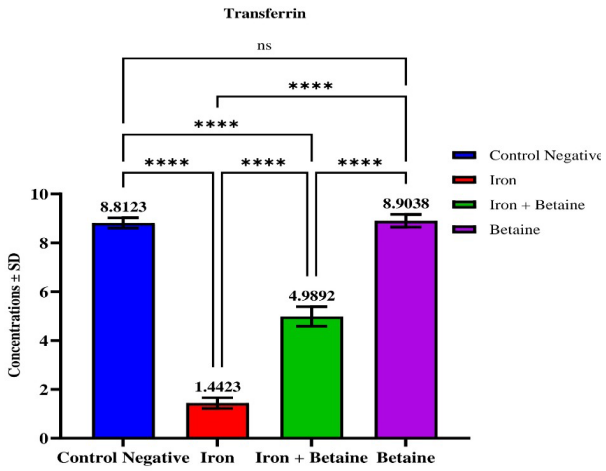

Figure 5. Serum transferrin concentrations in the experimental groups

Ns: Not significant.

Note: The bar graph shows transferrin concentrations (g/L; Mean±SD) in Control Negative, iron, iron + betaine and betaine groups (n=8), measured using ELISA. Statistical comparisons were performed by one-way ANOVA followed by Tukey's multiple-comparison test. ****P≤0.0001.

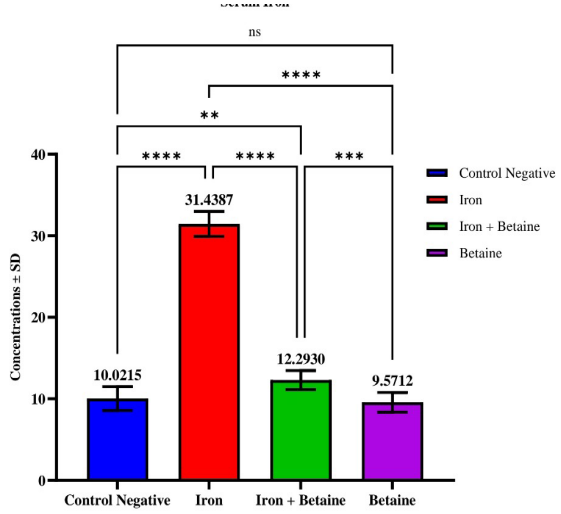

Figure 6. Serum iron concentrations in the experimental groups

Ns: Not significant.

Note: The bar graph shows serum iron concentrations (µmol/L; Mean±SD) in control negative, iron, iron + betaine and betaine groups (n=8), measured using ELISA. Statistical comparisons were performed by one-way ANOVA followed by Tukey's multiple-comparison test. The graph uses **, ***, and **** for significant comparisons. Confirm the corresponding P-value thresholds against the Tukey output.

Myocardial stress and injury markers

The iron-overloaded group was used as the calibrator, and a value of 1.000 was assigned to the highest level of myocardial molecular stress. The decrease in Bnp expression to 0.0866-fold in the treatment group represents a significant quantitative decrease in the molecular signaling associated with heart failure. This finding suggests that betaine could reduce genetic markers of cardiac wall stretch by more than 90% compared to the untreated iron-overloaded state, bringing the molecular environment closer to that of the negative control.

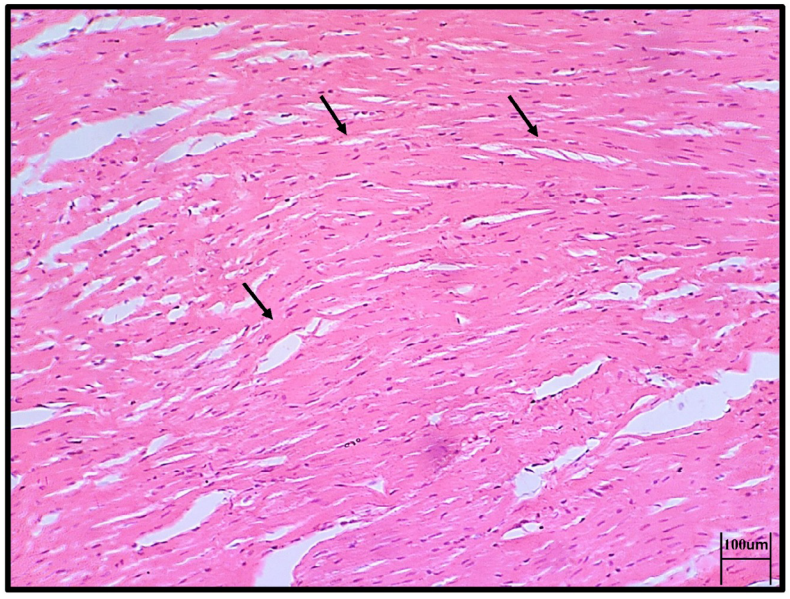

Figure 7. Histopathological section of the heart in the control negative group (H&E; magnification: ×10)

Note: Normal myocardial architecture and cardiac muscle fibers are indicated by black arrows.

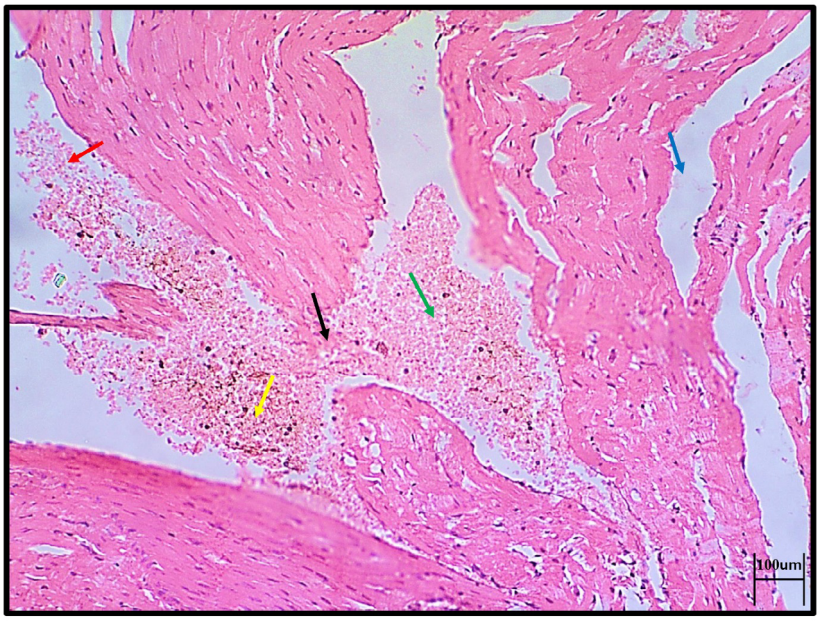

Figure 8. Histopathological section of the heart in the control positive group (H&E; magnification: ×10)

Note: The section shows myocardial tissue with extensive coagulative necrosis (black arrow), loss of striations (blue arrow), and prominent neutrophilic infiltration in the interstitium (red arrow). Hemorrhage and interstitial edema are also visible (green arrow), as is hemosiderin deposition (yellow arrow), an indicator of iron-overload injury.

The significant increases in Bnp mRNA expression (Figure 1) and serum cardiac troponin C (Figure 3) in the iron-overloaded group are key indicators of ventricular dysfunction and cardiac wall stress. Bnp is a sensitive biomarker of iron-overload cardiomyopathy (IOC) and can indicate left ventricular impairment before clinical symptoms appear (Murphy et al., 2010). Excessive iron accumulation places excessive mechanical stress on the

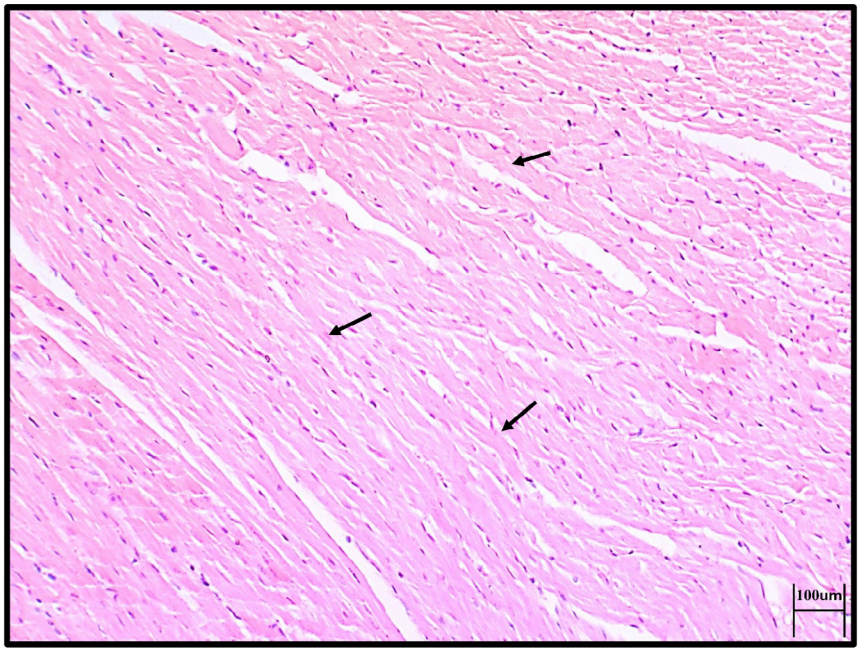

Figure 9. Histopathological section of the heart from the iron + betaine group (H&E; magnification: ×10)

Note: Black arrows indicate comparatively preserved myocardial fiber architecture with limited residual interstitial separation.

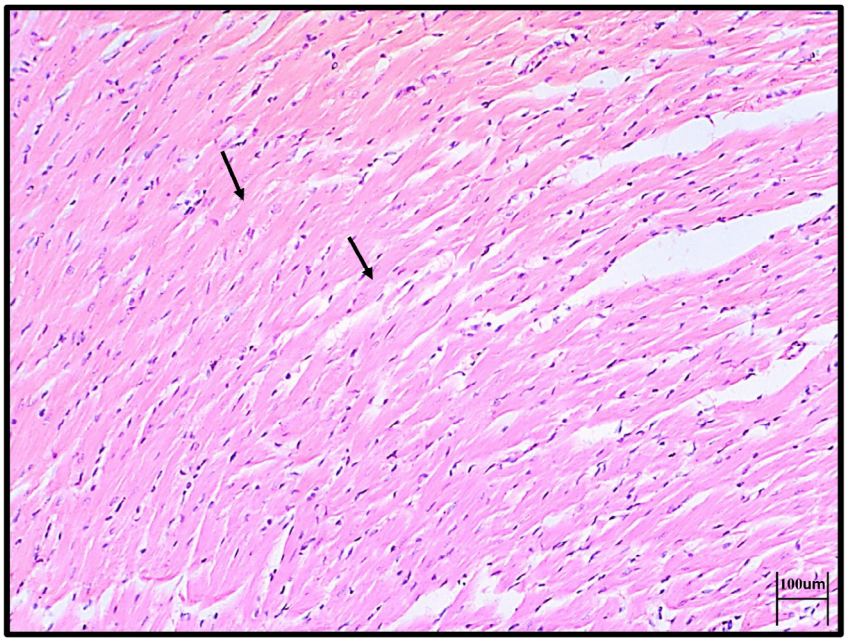

Figure 10. Histopathological section of the heart in the betaine-only group (H&E; magnification: ×10)

Note: The section shows preserved myocardial architecture similar to the negative control group (black arrows).

myocardial walls, prompting the compensatory release of Bnp. It also increases cardiomyocyte membrane permeability, leading to the leakage of troponin C into the serum (Das et al., 2015).

Betaine treatment significantly lowered these indicators, suggesting improved hemodynamic stability. This cardioprotective effect may be mediated by betaine's ability to stabilize energy levels, preserve mitochondrial ATP levels, and maintain cellular membrane integrity (Alirezaei et al., 2017; Ganesan et al., 2010).

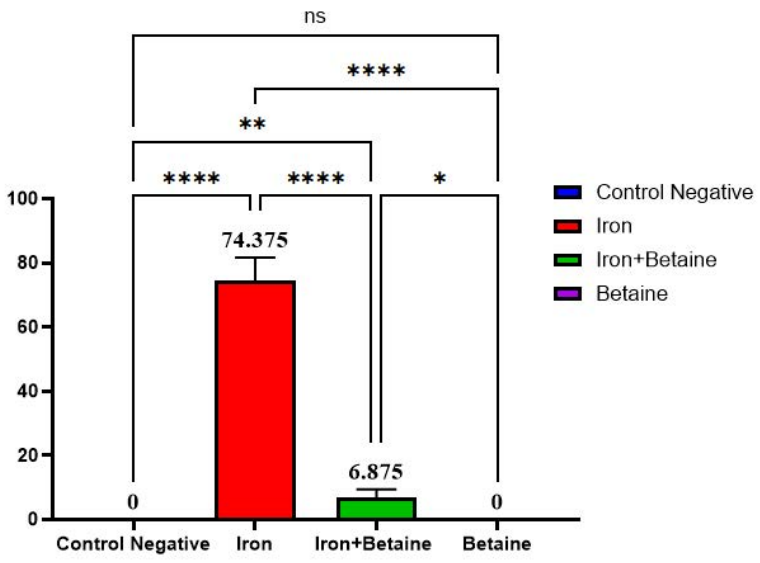

Figure 11. Total myocardial tissue damage (%) across the experimental groups

Note: The bars represent total tissue damage percentages derived from semi-quantitative histopathological scoring: Control Negative, 0%; Iron, 74.375%; Iron + Betaine, 6.875%; Betaine, 0% (n=8 per group). The underlying individual lesion categories were scored from 0 to 4 as described in Table 1; the vertical axis in this graph represents percentages, not raw 0–4 lesion scores. Significance symbols are reproduced from the original graph and should be verified against the source statistical output.

Oxidative stress and lipid peroxidation

Pronounced lipid peroxidation is evidenced by the significant elevation of serum MDA levels in the iron-overloaded group (Figure 2). This chemical shift is catalyzed by the Fenton reaction, in which excess free iron promotes the formation of hydroxyl radicals that vigorously attack cellular membranes (Bartfay et al., 2000). Betaine's ability to inhibit MDA generation demonstrates a strong anti-peroxidative effect, consistent with its effects on enhancing glutathione (GSH) activity and activating the Nrf2-Keap1-ARE signal transduction pathway (Erman et al., 2004; Li et al., 2019; Na et al., 2019).

Systemic iron homeostasis

Systemic iron overload was indicated by increased serum ferritin (Figure 4) decreased serum transferrin (Figure 5) and increased serum iron (Figure 6). Ferritin is also a major marker of iron-store saturation (Paterek et al., 2018; Vogt et al., 2021). The reported decrease in serum transferrin is probably a compensatory mechanism by which the liver restricts further iron transport to tissues because of excessive iron stores (Vogt et al., 2021). Betaine partially restored transferrin levels and reduced iron stores, highlighting its importance as a key regulator of iron flux and storage (Arumugam et al., 2021; Yousef et al., 2022).

Histopathological findings

Coagulative necrosis and the presence of hemosiderin (Figure 8), both characteristic of iron-mediated tissue injury and ferroptosis, provide histopathological evidence of such damage (Fang et al., 2020; Yan et al., 2019). Conversely, the negative control (Figure 7) and betaine-only (Figure 10) groups exhibited normal myocardial architecture, indicating that betaine is a nontoxic compound with no effect on cardiac histology under normal conditions. The partial restoration of myocyte structural integrity in the treatment group (Figure 9) suggests that betaine has the potential to act as a chemical chaperone that preserves the structural integrity of contractile proteins by protecting against oxidative tissue injury in iron-loaded conditions (Das et al., 2015; Toya et al., 2020).

The semi-quantitative scoring system adds analytical depth by corroborating the severe myocardial injury caused by iron and the marked protective effect of betaine (Table 1; Figure 11). The iron-overloaded group reached the "point of no return" for myocardial injury at Grade 4, with 74.375% damage (Figure 11). This resulted directly from the breakdown of myocardial architecture caused by iron-mediated ferroptosis and excessive oxidative stress, which led to the compensatory elevation of Bnp and the leakage of troponin C (Das et al., 2015, Fang et al., 2020, Murphy et al., 2010).

The significant decrease in tissue damage, from 74.375% to minimal residual damage of 6.875% after betaine administration, indicates that betaine is a potent multitarget protective agent (Table 1; Figure 11). This structural preservation is consistent with the molecular suppression of Bnp expression by more than 90% (0.0866-fold). Betaine has been found to function as a chemical chaperone that stabilizes the integrity of contractile proteins, as well as an energy stabilizer that helps maintain mitochondrial ATP levels (Alirezaei et al., 2017; Das et al., 2015; Ganesan et al., 2010; Toya et al., 2020).

Betaine is able to regulate systemic iron homeostasis, thereby preventing the heart from progressing to irreversible pathological stages (Bellezza et al., 2018; Gammella et al., 2016; Roemhild et al., 2021). The present results indicate that betaine not only attenuates myocardial injury, but also substantially protects against cardiac structural deterioration, which is usually caused by chronic iron-mediated oxidative stress.

Study limitations

Although the present study produced significant findings, it has some limitations that should be noted. First, although H&E staining provided clear evidence of myocardial injury and hemosiderin deposition, the absence of specific iron staining, such as Prussian blue, limits the definitive localization and quantification of focal iron distribution. Finally, the current 30-day experimental model focuses on the subacute-to-chronic phase of iron overload. Long-term observations and assessments of different betaine dose responses are suggested to further investigate its long-term clinical potential.

Conclusion

The present study shows that systemic toxicity is associated with iron overload and is characterized by increased oxidative vulnerability and structural heart damage. Betaine administration was an effective multitarget protective agent against these pathological changes. Betaine protects the heart by decreasing biomarkers of myocardial stress (Bnp and troponin C), inhibiting lipid peroxidation via the Nrf2 pathway, and regulating systemic iron homeostasis. In general, betaine is a potential non-toxic natural protec-

tive agent that can protect vital organs against iron toxicity and may serve as an effective remedial therapy for iron-loading illnesses and related cardiomyopathy.

Ethical Considerations

Compliance with ethical guidelines

This study was approved by the Central Bioethics Committee at the University of Kufa, Kufa, Iraq (Code: No. T/2744).

Funding

This research did not receive any grant from funding agencies in the public, commercial, or non-profit sectors.

Authors' contributions

Conceptualization, methodology, software, validation, formal analysis, investigation, resources, data curation, visualization, project administration, and writing the original draft: Haider Mawash; Review, editing, and final approval: All authors; Supervision: Saif Al-Aqbi.

Conflict of interest

The authors declared no conflict of interest.

Acknowledgments

The authors would like to express their heartfelt gratitude to the University of Kufa, Faculty of Veterinary Medicine, for providing the laboratory facilities, equipment, and animal-house environment required for this study. They also wish to acknowledge the Central Bioethics Committee at the University of Kufa for its ethical review of the research protocols, its guidance, and its official review of the protocols, which were approved by the appropriate authorities.

References

Alipourfard, F., Shajiee, H., Nazari-Serenjeh, F., Hojati, V., & Alirezaie, M. (2023). Betaine attenuates oxidative stress and cognitive dysfunction in an amyloid β-induced rat model of Alzheimer's disease. *Research in Pharmaceutical Sciences, 18*(3), 270-278. [DOI:10.4103/1735-5362.371583] [PMID]

Alirezaei, M., Jaldani, V., Dezfoulian, O., & Shahsavari, G. (2017). Betaine improves gastroprotective effects of ranitidine and omeprazole against Indomethacin-induced gastric ulcer in rats. *Herbal Medicines Journal, 2*(1), 9-17. [Link]

Arosio, P., Carmona, F., Gozzelino, R., Maccarinelli, F., & Poli, M. (2015). The importance of eukaryotic ferritins in iron handling and cytoprotection. *The Biochemical Journal, 472*(1), 1–15. [DOI:10.1042/BJ20150787] [PMID]

Arumugam, M. K., Paal, M. C., Donohue, T. M., Jr, Ganesan, M., Osna, N. A., & Kharbanda, K. K. (2021). Beneficial effects of betaine: a comprehensive review. *Biology, 10*(6), 456. [DOI:10.3390/biology10060456] [PMID]

Ashtary-Larky, D., Bagheri, R., Ghanavati, M., Asbaghi, O., Tinsley, G. M., & Mombaini, D., et al. (2022). Effects of betaine supplementation on cardiovascular markers: A systematic review and Meta-analysis. *Critical Reviews in Food Science and Nutrition, 62*(23), 6516-6533. [DOI:10.1080/10408398.2021.1902938] [PMID]

Bancroft, J. D., & Layton, C. (2013). The hematoxylins and eosin. In S. K. Suvarna, C. Layton, & J. D. Bancroft (Eds.), *Bancroft's theory and practice of histological techniques* (7th ed., pp. 173–186). Amsterdam: Churchill Livingstone Elsevier. [DOI:10.1016/B978-0-7020-4226-3.00010-X]

Bartfay, W. J., & Bartfay, E. (2000). Iron-Overload Cardiomyopathy: Evidence for a Free Radical- Mediated Mechanism of Injury and Dysfunction in a Murine Model. *Biological Research For Nursing, 2*(1), 49-59. [DOI:10.1177/109980040000200106] [PMID]

Bellezza, I., Giambanco, I., Minelli, A., & Donato, R. (2018). Nrf2-Keap1 signaling in oxidative and reductive stress. *Biochimica et Biophysica Acta. Molecular Cell Research, 1865*(5), 721–733. [DOI:10.1016/j.bbamcr.2018.02.010] [PMID]

Craig, S. A. (2004). Betaine in human nutrition. *The American Journal of Clinical Nutrition, 80*(3), 539-549. [DOI:10.1093/ajcn/80.3.539] [PMID]

Das, S. K., Wang, W., Zhabyeyev, P., Basu, R., McLean, B., & Fan, D., et al. (2015). Iron-overload injury and cardiomyopathy in acquired and genetic models is attenuated by resveratrol therapy. *Scientific Reports, 5*(1), 18132. [DOI:10.1038/srep18132] [PMID]

Dev, S., & Babitt, J. L. (2017). Overview of iron metabolism in health and disease. *Hemodialysis International. International Symposium on Home Hemodialysis, 21*(Suppl 1), S6–S20. [DOI:10.1111/hdi.12542] [PMID]

Erman, F., Balkan, J., Çevikbaş, U., Koçak-Toker, N., & Uysal, M. (2004). Betaine or taurine administration prevents fibrosis and lipid peroxidation induced by rat liver by ethanol plus carbon tetrachloride intoxication. *Amino Acids, 27*(2), 199-205. [DOI:10.1007/s00726-004-0105-5] [PMID]

Fang, X., Cai, Z., Wang, H., Han, D., Cheng, Q., & Zhang, P., et al. (2020). Loss of cardiac ferritin h facilitates cardiomyopathy via Slc7a11-mediated ferroptosis. *Circulation Research, 127*(4), 486-501. [DOI:10.1161/CIRCRESAHA.120.316509] [PMID]

Gammella, E., Recalcati, S., & Cairo, G. (2016). Dual role of ROS as signal and stress agents: iron tips the balance in favor of toxic effects. *Oxidative Medicine and Cellular Longevity, 2016*, 8629024. [DOI:10.1155/2016/8629024] [PMID]

Ganesan, B., Buddhan, S., Anandan, R., Sivakumar, R., & AnbinEzhilan, R. (2010). Antioxidant defense of betaine against isoprenaline-induced myocardial infarction in rats. *Molecular Biology Reports, 37*(3), 1319-1327. [DOI:10.1007/s11033-009-9508-4] [PMID]

Godbole, S., & Mahajan, A. (2025). Study of morphological and histopathological lesions in heart and coronary vessels in cases with history of sudden death. *European Journal of Cardiovascular Medicine, 15*(7), 953–958. [Link]

Hoffman, J. R., Ratamess, N. A., Kang, J., Rashti, S. L., & Faigenbaum, A. D. (2009). Effect of betaine supplementation on power performance and fatigue. *Journal of the International Society of Sports Nutrition, 6*, 7. [DOI:10.1186/1550-2783-6-7] [PMID]

Jirkof, P., & Lofgren, J. (2023). Anesthesia and analgesia in laboratory rodents. In M. C. Dyson, P. Jirkof, J. Lofgren, E. A. Nunamaker, & D. Pang (Eds.), *Anesthesia and Analgesia in Laboratory Animals* (pp. 287-356). Cambridge: Academic Press. [DOI:10.1016/B978-0-12-822215-7.00007-X]

Khristian, E., Ghozali, M., Bashari, M. H., Purnama, J. N., Irianto, G., & Panigoro, R., et al. (2024). Intravenous administration of iron dextran as a potential inducer for hemochromatosis: Development of an iron overload animal model. *Narra J, 4*(3), e1003. [DOI:10.52225/narra.v4i3.1003] [PMID]

Konstantinova, S. V., Tell, G. S., Vollset, S. E., Nygård, O., Bleie, Ø., & Ueland, P. M. (2008). Divergent associations of plasma choline and betaine with components of metabolic syndrome in middle age and elderly men and women. *The Journal of Nutrition, 138*(5), 914-920. [DOI:10.1093/jn/138.5.914] [PMID]

Kumfu, S., Chattipakorn, S. C., & Chattipakorn, N. (2022). Iron overload cardiomyopathy: using the latest evidence to inform future applications. *Experimental Biology and Medicine, 247*(7), 574-583. [DOI:10.1177/15353702221076397] [PMID]

Li, C., Wang, Y., Li, L., Han, Z., Mao, S., & Wang, G. (2019). Betaine protects against heat exposure-induced oxidative stress and apoptosis in bovine mammary epithelial cells via regulation of ROS production. *Cell Stress and Chaperones, 24*(2), 453-460. [DOI:10.1007/s12192-019-00982-4] [PMID]

Mancardi, D., Mezzanotte, M., Arrigo, E., Barinotti, A., & Roetto, A. (2021). Iron overload, oxidative stress, and ferroptosis in the failing heart and liver. *Antioxidants, 10*(12), 1864. [DOI:10.3390/antiox10121864] [PMID]

Muckenthaler, M. U., Rivella, S., Hentze, M. W., & Galy, B. (2017). A red carpet for iron metabolism. *Cell, 168*(3), 344-361. [DOI:10.1016/j.cell.2016.12.034] [PMID]

Murphy, C. J., & Oudit, G. Y. (2010). Iron-Overload Cardiomyopathy: Pathophysiology, Diagnosis, and Treatment. *Journal of Cardiac Failure, 16*(11), 888-900. [DOI:10.1016/j.cardfail.2010.05.009] [PMID]

Na, J. D., Choi, Y. J., Jun, D. S., & Kim, Y. C. (2019). Alleviation of paraquat-induced oxidative lung injury by betaine via regulation of sulfur-containing amino acid metabolism despite the lack of betaine-homocysteine methyltransferase (BHMT) in the lung. *Food & Function, 10*(2), 1225-1234. [DOI:10.1039/C8FO01457D] [PMID]

Paterek, A., Kępska, M., Sochanowicz, B., Chajduk, E., Kołodziejczyk, J., & Polkowska-Motrenko, H., et al. (2018). Beneficial effects of intravenous iron therapy in a rat model of heart failure with preserved systemic iron status but depleted intracellular cardiac stores. *Scientific Reports, 8*(1), 15758. [DOI:10.1038/s41598-018-33277-2] [PMID]

Read, A. D., Bentley, R. E., Archer, S. L., & Dunham-Snary, K. J. (2021). Mitochondrial iron-sulfur clusters: structure, function, and an emerging role in vascular biology. *Redox Biology, 47*, 102164. [DOI:10.1016/j.redox.2021.102164] [PMID]

Roemhild, K., von Maltzahn, F., Weiskirchen, R., Knüchel, R., von Stillfried, S., & Lammers, T. (2021). Iron metabolism: Pathophysiology and pharmacology. *Trends in Pharmacological Sciences, 42*(8), 640-656. [DOI:10.1016/j.tips.2021.05.001] [PMID]

Ru, Q., Li, Y., Chen, L., Wu, Y., Min, J., & Wang, F. (2024). Iron homeostasis and ferroptosis in human diseases: mechanisms and therapeutic prospects. *Signal Transduction and Targeted Therapy, 9*(1), 271. [DOI:10.1038/s41392-024-01969-z] [PMID]

Schmittgen, T. D., & Livak, K. J. (2008). Analyzing real-time PCR data by the comparative CT method. *Nature Protocols, 3*(6), 1101-1108. [DOI:10.1038/nprot.2008.73] [PMID]

Soares, M. P., & Hamza, I. (2016). Macrophages and Iron Metabolism. *Immunity, 44*(3), 492-504. [DOI:10.1016/j.immuni.2016.02.016] [PMID]

Sukhbaatar, N., & Weichhart, T. (2018). Iron regulation: macrophages in control. *Pharmaceuticals, 11*(4), 137. [DOI:10.3390/ph11040137] [PMID]

Toya, T., Ito, K., Kagami, K., Osaki, A., Sato, A., & Kimura, T., et al. (2020). Impact of oxidative posttranslational modifications of SERCA2 on heart failure exacerbation in young patients with non-ischemic cardiomyopathy: A pilot study. *International Journal of Cardiology. Heart & Vasculature, 26*, 100437. [DOI:10.1016/j.ijcha.2019.100437] [PMID]

Veskovic, M., Mladenovic, D., Milenkovic, M., Tosic, J., Borozan, S., & Gopcevic, K., et al. (2019). Betaine modulates oxidative stress, inflammation, apoptosis, autophagy, and Akt/mTOR signaling in methionine-choline deficiency-induced fatty liver disease. *European Journal of Pharmacology, 848*, 39-48. DOI:10.1016/j.ejphar.2019.01.043] [PMID]

Vogt, A. S., Arsiwala, T., Mohsen, M., Vogel, M., Manolova, V., & Bachmann, M. F. (2021). On iron metabolism and its regulation. *International Journal of Molecular Sciences, 22*(9), 4591. [DOI:10.3390/ijms22094591] [PMID]

Willingham, B. D., Ragland, T. J., & Ormsbee, M. J. (2020). Betaine supplementation may improve heat tolerance: potential mechanisms in humans. *Nutrients, 12*(10), 2939. [DOI:10.3390/nu12102939] [PMID]

Yan, N., & Zhang, J. J. (2019). The emerging roles of ferroptosis in vascular cognitive impairment. *Frontiers in Neuroscience, 13*, 811. [DOI:10.3389/fnins.2019.00811] [PMID]

Yousef, M., Abdulmunem Abdulhameed, R., & Talib Yaseen Aldossary, A. (2022). Effect of betaine on blood parameters related to the iron status in acrylamide-treated rats. *Archives of Razi Institute Journal, 77*(3), 1241-1247. [DOI:10.22092/ari.2022.357804.2101] [PMID]

Zhang, M., Zhang, H., Li, H., Lai, F., Li, X., & Tang, Y., et al. (2016). Antioxidant mechanism of betaine without free radical scavenging ability. *Journal of Agricultural and Food Chemistry, 64*(42), 7921-7930. [DOI:10.1021/acs.jafc.6b03592] [PMID]