

## Infection of the Isfahan tooth-carp, *Aphanius isfahanensis* (Actinopterygii: Cyprinodontidae) with *Diplostomum spathaceum* (Trematoda: Diplostomidae): a case report.

Gholami, Z.<sup>1</sup>, Akhlaghi, M.<sup>2\*</sup>, Esmaeili, H. R.<sup>3</sup>

<sup>1</sup>Islamic Azad University, Babol Branch, Department of Veterinary Medicine, Babol-Iran.

<sup>2</sup>Aquatic Animal Health Unit, School of Veterinary Medicine, Shiraz University, Shiraz-Iran.

<sup>3</sup>Department of Biology, College of Sciences, Shiraz University, Shiraz-Iran.

(Received 5 May 2008, Accepted 10 December 2008)

**Abstract:** *Aphanius isfahanensis* is a new endemic killifish species that has been described in the Zayandeh River of the Isfahan basin in Iran. During a study on the biology of nine fish from this species, the parasite *Diplostomum spathaceum* was observed in the aqueous humor of the eye of a single individual. It was visible as a white mass with a diameter of 0.38 mm. This is the first report on the infection of *A. isfahanensis* with *D. spathaceum metacercaria*. They are pathogenic to fish and cause opacities in the optical lens (worm star) and blindness. Since *A. isfahanensis* is an endemic species, this discovery may be useful information to inform strategy with regards to the conservation of this fish.

**Keywords:** *Aphanius isfahanensis*, *Diplostomum spathaceum*, endemic, killifish

### Introduction

*Aphanius isfahanensis* (Kapourdandandar-e Esfahan) (Figures 1a and 1b) is a novel species of killifish and has been described in the Zayandeh River, which is in the Isfahan basin of Iran. It found in areas where there is brackish water, which has a temperature of 27°C, a pH of 6.7, conductivity of 10.9 mS, dissolved concentration of solids of 5450 ppm, and a slow water current (Hrbek *et al.*, 2006). There is only a scarce amount of data on many of the aspects of the biology of this fish, especially with regards to its parasites.

Trematodes of the genus *Diplostomum* are circumpolar distributed parasites that dwell in the small intestine of piscivorous birds, which include gulls and terns in particular. They require two intermediate hosts in their life cycle: firstly,

cercariae are produced asexually by sporocysts in a lymnaeid snail; secondly, metacercariae are localized in the eyes of fish and can then infect birds that consume the fish host (Chappell *et al.*, 1994).

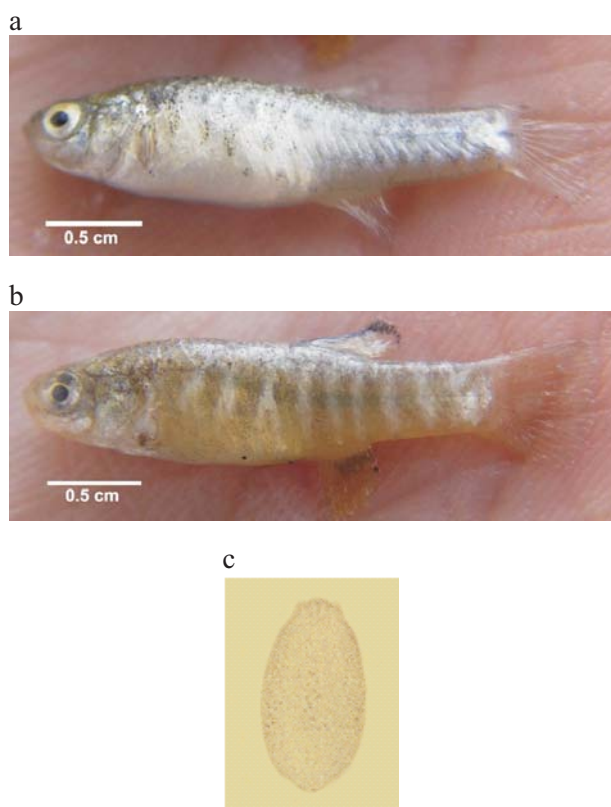
### Report of the infection

Fish were collected in spring (April to June) of 2006 from the lower reaches of the Zayandeh River with the use of a dip net. They were preserved in 10% formalin until their examination. We dissected a cohort of nine *Aphanius isfahanensis*, which included six females and three males. The mean length of males and females were 2.9 cm and 3.4 cm, respectively. A single female fish was found to be infected with the parasite, which was observed in the aqueous humor of one eye as a white mass with a diameter of 0.38 mm. The isolated parasite was

\*Corresponding author: akhlaghi@shirazu.ac.ir  
Tel: +98(711)6138737 Fax: +98(711)2286940



identified as *D. spathaceum metacercaria* (Chappell *et al.*, 1994). This is the first report of an infection of *A. isfahanensis* with *D. spathaceum metacercaria* (Figure 1c). *Diplostomum spathaceum* is the main agent of diplostomiasis, which is an important disease in fish. The metacercariae of *D. spathaceum* live in the optical lens of many freshwater fish without undergoing encystation. They are pathogenic to the fish by causing opacity of the eye lens. As well as inhabiting the lens, retina and aqueous humor of fish eyes, they have also been described in the brain, spinal cord and nasal cavities (Stables and Chappell, 1986; Chappell *et al.*, 1994). Infection with *Diplostomum* spp. leads to severe ocular pathology and can result in the death of the fish, which has implications for commercial fish farming.



**Figure 1:** Photographs of (a) female and (b) male (with flank bars on body) *Aphanis isfahanensis* from the Zayandeh River, Isfahan province, in the center of Iran. (c) This slide shows an example of *Diplostomum spathaceum* (magnification  $\times 100$ ) that was isolated from one of the eyes of a single fish.

## Discussion

Mokhayer (1989) reported the metacercariae of *D. spathaceum*, a fluke that affects the eye, in *Aphanius sophiae* in Iran. Species of the genus *Diplostomum* are distributed widely and are common parasites in aquatic environments (Esc and Fernandez, 1993). The fluke can cause complete blindness and death in species of fish that are important commercially. Diplostomiasis is very common in the freshwater fishes of Iran (Jalali, 1998). Khara *et al.* (2005) reported the prevalence of 8.59% of *D. spathaceum* in the lenses of perch eyes. In a recent work, the prevalence of *D. spathaceum* in some freshwater fishes of northwest Iran was reported as follows: *Capoeta capoeta*: 84%; *Cyprinus carpio*: 72%; *Lucioperca lucioperca*: 67%; and *Albornoides bipunctatus*: 73% (Pazooki *et al.*, 2007). The results of Jalali (1998) and Pazooki *et al.* (2007) show that incidence of *D. spathaceum* in the study area, especially among cyprinid fish, is very high.

The fish used in this study were collected from the Zayandeh River. This river is a very important water reservoir in the Isfahan area as there are many hatcheries and farms in the Isfahan Province that could be harmed by the endemic infection of *D. spathaceum*. The disease caused by invasion of the eye by larval digeneans, which become established and grow in the lens (Doroco *et al.*, 2000). This case report may be helpful for the conservation of *A. isfahanensis* and many other species. The present study revealed a new host and locality of infection. Therefore, an epidemiological survey in the region during the period of a year will be important to enable the formulation and implementation of successful infection control strategies.

## References

1. Chappell, L. H., Hardie, L. J., Scombes, C. J. (1994) Diplostomiasis: the disease and host-parasite interactions. In: Parasitic Disease of Fish (Eds. A. W. Pike and J. W. Lewis). Samara Publishing Ltd. pp: 59-86.
2. Doroco, M., Dilsiz, N., Grabbe, M. C. (2002) Occurrence and effects of *Diplostomum* spp.



- infection in eyes of *Acanthobrama marmid* in Keban Dam Lake, Elazig, Turkey. Turk. J. Vet. Anim. Sci. 26: 239-243.
3. Esc, G. W., Fernandez, J. C. (1993) A functional Biology of parasitism ecological and evolutionary implications. Chapman and Hall. London, UK. pp: 337.
  4. Hrbek, T., Keivany, Y., Coad, B. W. (2006) New species of *Aphanius* (Teleostei: Cyprinodontidae) from Isfahan Province of Iran and reanalysis of other Iranian species. Copeia. 2: 244-255.
  5. Jalali, B. (1998) Parasites and Parasitic Diseases of Iranian Freshwater Fishes. Iranian Fisheries Company. Tehran, Iran. pp: 562.
  6. Khara, H., Nezami, A., Sattari, M., Mousavi, A., Mousapoor, M., Hajipoor, A. (2005) Occurrence and intensity of parasites from perch (*Perca fluviatilis*, L. 1785) in Amirkelaieh wetland of Lahijan (Caspian basin – Iran). Pajouhesh and Sazandegi. 67: 92-103.
  7. Mokhayer, B. (1989) Fish Diplostomiasis in Iran. J. Fac. Vet. Med. Univ. Tehran. 44: 11-18.
  8. Pazooki, J., Masoumian, M., Yahyazadeh, M., Abbasi, J. (2007) Metazoan Parasites from Freshwater Fishes of Northwest Iran. J. Agri. Sci. Tech. 9: 25-33.
  9. Stables, J. N., Chappel, L. H. (1986) The epidemiology of diplostomiasis in farmed rainbow trout from north-east Scotland. Parasitology. 92: 699-710.

