

Study of the prevalence and type of ophthalmic diseases among different breeds of horses in Tehran riding clubs

Taghipour Bazargani, T.¹; Moaddab, S.H.^{1*}; Raoofi, A.¹; Masoudifard, M.¹ and Bahonar, A.R.²

¹Department of Clinical Sciences, Faculty of Veterinary Medicine, University of Tehran, Tehran, Iran. ²Department of Food Hygiene and Quality Control, Faculty of Veterinary Medicine, University of Tehran, Tehran, Iran.

Key Words:

Eye; ocular lesions; horse; riding clubs.

Correspondence

Moaddab, S.H.
Department of Clinical Sciences, Faculty of
Veterinary Medicine, University of Tehran,
P. O. Box: 14155-6453, Tehran, Iran.
Tel: +98(411)5546729
Email: hmoaddab@gmail.com

Received: 22 July 2010,

Accepted: 4 December 2010

Abstract

The aim of this study was to determine the prevalence and type of ophthalmic diseases among horse populations in the suburban riding clubs of Tehran. Ophthalmologic examinations were performed in 901 horses and ocular lesions were diagnosed in 40 (4.4%) animals. In the 54 eyes of these horses that had ocular defects, 103 ocular abnormalities were detected. Of those horses affected, 65% showed abnormalities in one eye and 35% had abnormalities in both eyes. Various sequelae to ocular trauma and periodic ophthalmia were the most common and recognizable causes, which comprised 25% and 15% of horses with ocular defects, respectively.

Introduction

Ocular disorders in horses are important because impaired vision of the animal can lead to accidents and put the health of the animal and the rider at risk. To date, no reports have been published on the prevalence and the type of ocular lesions of horses in Iran. Hurn and Turner (2006) observed that 7.4% of thoroughbreds had eye diseases that potentially threatened their vision. In studies by Reichmann (2008), 3.1% of the equine population was affected by an ocular disease. According to Mellor *et al.* (2001), approximately 1% of horses in northern Britain had permanent or recurrent ocular disorders.

The aim of this work was to record the prevalence and document the types of eye defects and diseases in populations of different horse breeds in Tehran. In addition, it compared the epidemiological data of this survey with those of other international reports.

Materials and Methods

All horses underwent a complete eye examination. Both eyes were examined following dark adaptation with a pen light and a direct ophthalmoscope. In accordance with the results of this initial examination, more precise ophthalmological diagnostic techniques, such as ocular swabbing, scraping, dilatation of pupils with tropicamide, fluorescein staining, nasolacrimal duct catheterization, were carried out as recommended by Speirs and Wrigley (1997). To evaluate the state of the globe and internal structures, in cases with opacities on or within the eye, ocular ultrasonography

was carried out because adequate fundic examination by ophthalmoscopy was not possible. After the lesions were detected, detailed patient histories were obtained from the owners. A diagnosis was made on the basis of the history, and of clinical, direct ophthalmoscopic and ultrasonographic findings.

Results

In this study, 901 horses, consisting of 483 females (53.6%), 223 geldings (24.7%), and 195 males (21.6%), with an age range from 6 months to 22 years (mean 8.5 years, median 10 years) were examined. Breeds, number and percentage of animals of each breed and the incidences of different eye diseases are shown in Table 1.

Forty (4.4%) of the horses had eye lesions (Table 2). Of these affected horses, 65% showed abnormalities in one eye and 35% had defects in both eyes. In total, 103 ocular abnormalities were detected in 54 eyes of the 40 horses with eye lesions. Physical injuries and equine

Table 1: Prevalence of affected horses according to their breeds.

Breed	No. (%)	Affected horses (%)
Mixed breed	409 (45.3)	13 (3.17)
Thoroughbred	149 (16.5)	2 (1.34)
Arab	104 (11.5)	7 (6.73)
Turkman	80 (8.8)	5 (6.25)
KWPN	57 (6.3)	4 (7.01)
Holsteiner	55 (6.1)	6 (10.9)
Hanoverian	23 (2.5)	2 (8.69)
Oldenburg	14 (1.5)	1 (7.14)
Trakehner	7 (0.7)	
Caspian	3 (0.3)	

Table 2: Prevalence of ocular lesions in affected horses.

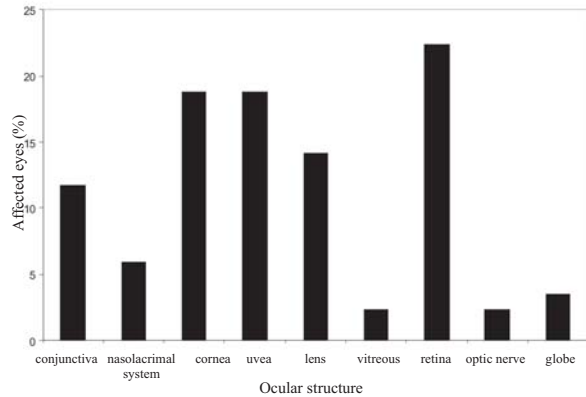
Types of ocular lesions	Affected eyes	Affected horses	Causes of ocular lesions
Conjunctivitis	10	6	ERU* (1), systemic disease (2), dacryocystitis (3)
Epiphora	12	9	ERU (4), systemic disease (2), keratitis (2), dacryocystitis (1)
Mucopurulent ocular discharge	5	3	Dacryocystitis and chronic nasolacrimal blockage (3)
Corneal scarring	8	8	Corneal disease (ulcer, trauma)
Corneal pigmentation	4	4	Chronic keratitis (2), chronic uveitis (1), uveal melanoma (1)
Corneal edema	4	4	ERU (3), nonulcerative keratitis (1)
Evidence of previous uveitis	4	4	ERU (4)
Anterior synechiae	1	1	Trauma (1)
Posterior synechiae	5	5	ERU (4), trauma (1)
Change in iris color	3	3	ERU (3)
Iris hypoplasia	1	1	Congenital
Persistent pupillary membrane	1	1	Congenital
Melanoma	2	1	
Atrophy of corpora nigra	4	4	ERU (4)
Cataract	10	8	ERU (6), trauma (1), congenital (1)
Lens luxation/subluxation	3	3	ERU (2), trauma (1)
Hyalitis	2	2	ERU (2)
Retinal degeneration	2	1	Trauma
Retinal detachment	1	1	ERU (1)
Peripapillary chorioretinopathy	7	6	ERU (1), incidental (?), previous systemic disease (?)
Focal chorioretinopathy	9	8	Postinflammatory (?), incidental (?)
Optic nerve atrophy	2	1	Trauma (1)
Phthisis bulbi	2	2	Trauma (1), ERU (1)
Buphthalmos	1	1	ERU (1)

*ERU = Equine recurrent uveitis.

recurrent uveitis (ERU) were the two most common diseases resulting in ocular lesions, which accounted for 10 (25%) and six (15%) of the horses with ocular disorders, respectively. The prevalences of lesions affecting different parts of the eye are shown in Figure 1. All six horses affected with conjunctivitis suffered from secondary conjunctivitis. Two horses had respiratory diseases, and one of them was affected with ERU that resulted in ciliary flush and the appearance of redness and hyperemia of conjunctival tissue. Ultimately, conjunctivitis constituted one of the clinical findings in three patients affected with dacryocystitis. Dacryocystitis had been diagnosed in these three horses on the basis of a history of chronic epiphora and mucopurulent discharge without being associated with ocular inflammation. In two horses, the condition tended to occur seasonally during the warmer months of year. Failure of passage of fluorescein dye from the lower punctum into the nares indicated nasolacrimal duct obstruction. Relief of the obstruction with retrograde irrigation and application of topical antibiotics and anti-inflammatory drugs led to complete recovery.

In this study, trauma was the most common cause of corneal disorders that led to various complications of

Figure 1: Prevalence of affection in different parts of eye.



corneal wounding, such as corneal scars and corneal pigmentation. From 10 horses with trauma-induced corneal lesions, seven were flat-racing horses and three were jump-racing horses. Although a peripheral corneal scar does not greatly affect vision, axial scars and scars that affect a large area can seriously alter vision (Figure 2).

Corneal edema due to corneal endothelial damage, which initially is not associated with corneal ulcer and was fluorescein-negative, was diagnosed in three horses with ERU, and in one horse with nonulcerative keratitis. In one of the patients with ERU-induced corneal endothelial dysfunction and corneal edema, rupture of epithelial bullae eventually led to corneal ulceration, possibly as a result of self-trauma. A fluorescein-negative corneal vascularization and edema were the main signs detected during ophthalmologic examination of an Arabian mare with a history of recurrent ocular disease. Ultrasonographic examination of the affected eye revealed that no other ocular compartment was affected. Nonulcerative keratitis and corneal lesions were controlled with topical dexamethasone. Intraocular melanoma was diagnosed in a 7-year-old grey gelding; there were also lesions in the cervical area and the

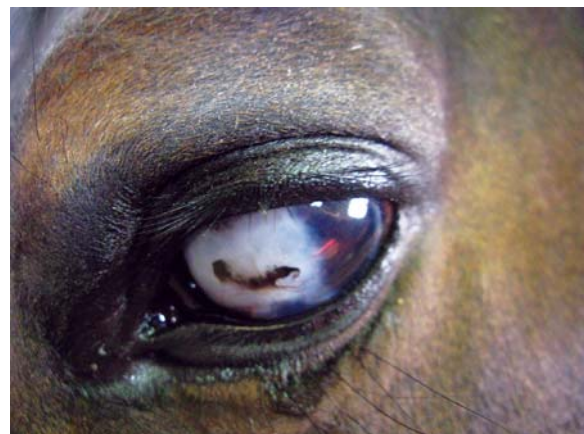

Figure 2: Traumatic induced corneal scarring and pigmentation in the right eye of an 8-year-old mixed breed mare.

perineum. The origin of the tumor was the iris, and the tumor mass was in contact with the posterior surface of the cornea (Figure 3). In the other eye, a similar but smaller tumor mass could be observed. This case was a very rare and interesting phenomena in which both skin and intraocular melanoma were found simultaneously.

Hyalitis with characteristic ultrasonographic findings, such as echogenic swirling material within the vitreous that represented vitreal debris secondary to inflammation (Figure 4), was diagnosed in two horses with ERU. Retinal detachment was observed in one horse, whereas a posterior cortical cataract was observed in the other, which were both possibly the result of vitritis.

Discussion

Primary conjunctivitis as a distinct entity is uncommon in horses (Gilger, 2005). Since conjunctivitis

is one of the clinical findings of many systemic diseases, and inflammation of adjacent ocular structures can manifest itself as a secondary conjunctivitis, a complete general and ophthalmologic examination should be carried out to rule out all systemic and ocular causes of secondary conjunctivitis (Auer and Stick, 2006; Gilger, 2005). It was shown that all examined horses with conjunctivitis suffered from secondary conjunctivitis and showed other clinical signs complications. Due to the impressive appearance of corneal disorders that are easily recognized by horse owners, the relatively large globe size, the normal protrusion of the corneal surface and the environment in which horses exist, ocular traumata and corneal trauma-induced disorders are frequent causes of the so-called “horse’s ocular blemishes” in pre-purchase examinations (Auer and Stick, 2006; Launosis *et al.*, 2008). In this study, it was shown that flat-racing horses are much more at risk of ocular traumatic injuries than jump-racing horses. This is probably due to the fact that flat-racing horses are mainly exposed to sand and other solid particles that are thrown up by hooves during high speed races on a sandy race track.

The low prevalence of common acute ocular lesions, such as corneal ulcer and corneal edema, may have been explained by the fact that this study was retrospective one (Wilkie, 2004). Barely noticeable symptoms, such as atrophy of the corpora nigra, iris depigmentation, hyperpigmentation, or pigment flecks on the anterior lens capsule, can be indicative of very serious diseases, such as ERU (Maggs, 2009). By paying attention to these signs, a possible onset of ERU can be predicted, which could be especially important when the owner of the horse is unaware of its previous history. In this study it was demonstrated that most of the cataract cases were derived from ERU, which confirmed earlier findings that cataracts developed in 41% of all cases with ERU (Gilger, 2005). In ocular examinations relating to horses with chorioretinitis, there was only one case in which other signs of uveitis were seen. However, in other cases with ERU, opacities of cornea, cataract, vitritis or retinal detachment prevented the observation of potential or probable chorioretinitis with a direct ophthalmoscope. It is known in other cases of chorioretinopathy that the animals did not show any impairment of vision or any symptoms of recognizable ocular diseases. As these symptoms might be residual signs of previous systemic infections, they were regarded as incidental findings (Chandler *et al.*, 2003; Gilger, 2005). It should be noted that the true percentage of horses affected with ocular lesions in stables might differ from the figures described here, since affected animals are normally not kept. This is due to the high prices of keeping these animals except for breeding (Hayek *et al.*, 2005).

In conclusion, ERU and traumatic insults are the two most common causes for the various ocular lesions which observed in this study.

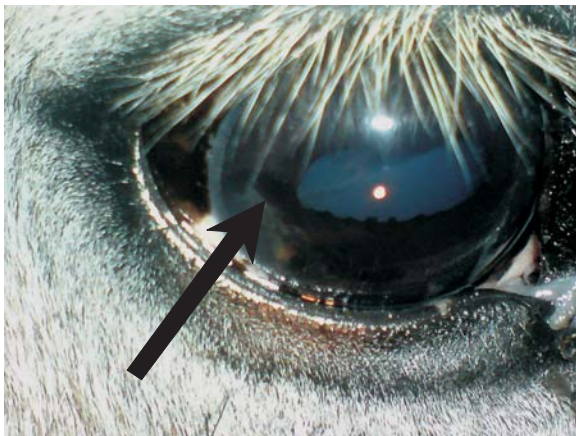


Figure 3: Intra ocular melanoma (arrow) arising from anterior surface of iris, filling the anterior chamber, and in contact with the posterior surface of the cornea.

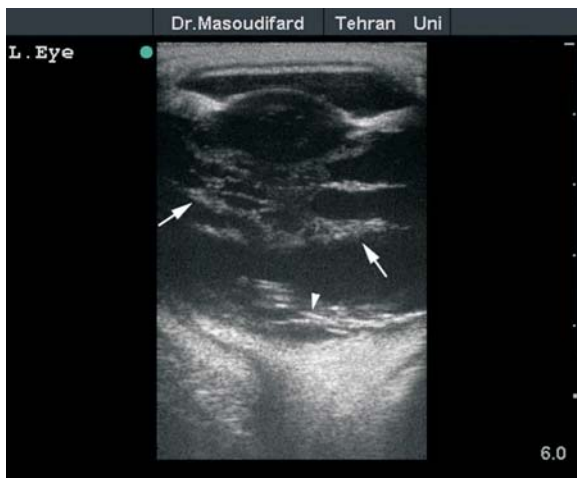

Figure 4: Ultrasonographic scanning of the left eye in a Thoroughbred stallion. Swirling echogenic materials including vitreal debris and fibrin in the vitreous (arrows) and partial retinal detachment (arrowhead) were found.

References

1. Auer, J.A; Stick, J.A. (2006) Equine surgery. 3rd edition, Saunders, St Louis, USA pp: 731-734.
2. Chandler, K.J.; Billson, F.M. and Mellor, D.J. (2003) Ophthalmic lesions in 83 geriatric horses and ponies. *Vet. Rec.* 153(11): 319-322.
3. Gilger, B.C. (2005) Equine Ophthalmology. 1st edition, Elsevier Inc, St. Louis, USA pp: 125-127, 271-275.
4. Hayek, A.R.; Jones, B.; Evans, D.L.; Thomson, P.C. and McGreevy, P.D. (2005) Epidemiology of horses leaving the Thoroughbred and Standardbred racing industries. Proceedings of the 1st International Equitation Science Symposium. 26-27th August, Melbourne, Australia.
5. Hum, S.D.; Turner, A.G. (2006) Ophthalmologic examination findings of thoroughbred racehorses in Australia. *Vet. Ophthalmol.* 9(2): 95-100.
6. Launosis, T.; Perrin, R. and Brogniez, L. (2008) Ophthalmologic findings in 100 French sport horses during pre-purchase examination. Proceedings of the 10th International Congress of World Equine Veterinary Association. Jan 28th - Feb 1st, Moscow, Russia.
7. Maggs, D.J. (2009) Diseases of the eye. In: Large Animal Internal Medicine. Edited by: Smith B.P. 4th edition, Mosby Elsevier, pp: 1267-1268, 1290-1293.
8. Mellor, D.J.; Love, S.; Walker, R.; Gettnby, G. and Reid, S.W.J. (2001) Sentinel practice-based survey of the management and health of horses in northern Britain. *Vet. Rec.* 149: 417-423.
9. Reichmann, P. (2008) Occurrence of ophthalmologic diseases in horses used for urban cart hauling in Londrina, PR, Brazil. *Ciencia Rural* 38(9): 2225-2528.
10. Speirs, V.C.; Wrigley, R.H. (1997) Clinical Examination of Horses. 1st edition, Saunders, Philadelphia, USA pp: 241-261.
11. Wilkie, D.A. (2004) Equine Ophthalmology. In: Equine Internal Medicine. Edited by: Reed, S.M., Bayly, W.M. and Sellon, D.C. 2nd edition, Saunders, St Louis, USA pp: 1010-1011.