

A comparative study on bacteriology and pathology in uteri of cattle and buffaloes in Ahwaz region, Iran

Sayyari, M.^{1*}, Farhangnia, M.², Ghaemmaghami, SH.³, Sharma, RH.⁴

¹Department of Pathobiology, School of Veterinary Medicine, Shiraz University, Shiraz, Iran.

²Iranian Veterinary Organization, Tehran, Iran.

³Faculty of Scientific Board of Natural Resource and Agricultural center of Arak, Arak, Iran.

⁴Department of Pathobiology, Faculty of Veterinary Medicine, University of Shahid Chamran, Ahwaz, Iran.

Key words:

uterus, cow, buffalo, lesion, microbiology.

Correspondence

Sayyari, M.

Department of Pathobiology, Faculty of Veterinary Medicine, Shiraz University, Shiraz, Iran.

Tel: +98(711) 2286950

Fax: +98(711) 2286940

Email: sayyari@shirazu.ac.ir

Received: 12 July 2011

Accepted: 5 November 2011

Abstract:

BACKGROUND: Uterine infection is a major problem in reproductive management. **OBJECTIVES:** The aim of this study was to find out the common pathological condition of cattle and buffaloes' uteri in the Ahwaz region and, also to compare uterine lesions. **METHODS:** One hundred and thirty eight cattle and 101 buffalo uteri were examined for macroscopic lesions, opening them through the cervix to the apex of the animals' horns. The prepared tissue sections were stained with hematoxylin, eosin, and Giemsa staining. Standard bacteriological works, were used for the isolation and identification of aerobes and anaerobes. **RESULTS:** Depending on the severity of the lesions, endometritis was scored from mild (level 1) to severe (level 4). Level 1 including 39 cows (19.69%) and 36 buffaloes (28.8%); Level 2 including 37 cows (18.68%) and 28 buffaloes (22.4%); Level 3 including 23 cows (11.61%) and 22 buffaloes (17.6%); and, Level 4 including 17 cows (8.58%) and 5 buffaloes (4%). Other lesions consisted of acute metritis: (cows=4.54%), buffalo=0.8%); chronic metritis (cows=2.02%) and buffaloes=2.4%; granulomatous metritis cow (0.5%) and buffalo (0.8%); perimetritis (cows (3.3%) and buffaloes (1.6%); pyometra: (cow 0.5%) and buffalo (0.8%); external cysts: (buffalo 0.8%); and, haemangioma: (cow (0.5%) and buffalo (0.8%). No significant correlation was found among the lesions, except for acute metritis, ($p=0.475$). **CONCLUSIONS:** Conducting a clinical and paraclinical study on fertile animals in the Ahwaz region is highly recommended to reduce the economic losses due to uterine infection.

Introduction

Most lesions of the uterine tubes are either incidental or secondary to lesions in other parts of the reproductive tract. Prolapse of the uterus has importance after parturition in both the ewe and cow. Factors that cause uterine inertia include prolonged dystocia, hypocalcemia and ingestion of estrogenic plants. Endometrial atrophy is usually due to loss of ovarian function secondary to hypopituitarism.

Endometrial hyperplasia is important in the ewe and also occurs in the cow; however, adenomyosis and endometriosis are rare in the cow (McGavin et al., 2007). Most uterine infections resulting from ascending infections arise when the cervix becomes open during estrus, parturition or postpartum involution (Murry et al., 1990; Sheldon et al., 2004; Foldi et al., 2006; Schmidt et al., 2006). A variety of bacteria, both Gram-positive and Gram-negative, either aerobes or anaerobes, were isolated from the

early postpartum uterus. Post parturition bacteria may invade the birth canal and the uterine cavity ascending from the environment as well as the animals' skin and feces. Endometritis is an inflammation limited to the endometrium, usually occurring due to the seminal fluid and bacterial infection in non-pregnant animals (Sheldon and Dobson, 2004). In cows, postpartum endometritis occurs, to some extent, even after a normal pregnancy and parturition, Endometritis is a more common and severe condition following an abnormal parturition (McGavin et al., 2007). Uterine disease is a major cause of infertility and, in some cases, mortality. The most common type of these inflammatory diseases usually results from bacterial contamination of the uterus (Azawi et al., 2007). Information on the pathological conditions of the buffaloes' uteri is confined to a few reports from India, Pakistan, Iraq, Egypt and Iran (Khan, 1991). Uterine contamination following calving is common, but most healthy cows are able to clear bacteria from their uteri in the first 2 to 3 weeks after calving (Bondurant, 1991). This study, performed on the uteri of cows and buffaloes slaughtered in Ahwaz, Khuzestan Province, located in southwest Iran, aimed at unveiling the common pathological conditions in the uteri of animals found in this area.

Materials and Methods

The abattoir was visited once a week and approximately 20 uteri from cows above 5 years, and 10 uteri from buffaloes above 8 years were examined at random. A total of 198 uteri from cows and 125 uteri from buffaloes were examined for macroscopic lesions, opening through the cervix to the apex of the horns. Uteri of 60 cows and 24 buffaloes did not show any macroscopic lesions and were eliminated from the study. Samples were transferred to the laboratory inside plastic bags containing ice, and the bacteriological culture was prepared for study. In the next stage, using standard methods, pieces of the uterus showing gross abnormalities were taken from the left and the right horns and the body was fixed in 10% formalin, processed and embedded in paraffin, sectioned at 6 μ m diameter and stained with Haematoxylin and eosin, and Giemsa. Toluidin blue stain was employed to identify the mast cells.

Specific staining methods, namely Gram, Modified Ziehl-Neelsen, GomoriAldihydefuschin, and PAS were used as required. The uterine samples were cultured for both aerobic and anaerobic bacteria, and standard biochemical tests were used for the isolation and identification of aerobes and anaerobes. A: Macintosh anaerobic glass jars with vents were used for culturing obligate anaerobic. The anaerobic jar was used with a commercially available pack that delivers an H₂+Co₂ atmosphere. Plates of Brewer's Agar were inoculated by rubbing the swab and were placed inside the anaerobic jar which was then sealed and placed inside incubators at 37 C for 7 days. B: To avoid obligate anaerobic bacteria elimination upon oxygen exposure, the anaerobes were cultured using reducing media. For preliminary confirmation, all anaerobes were isolated on anaerobic Brewer's Agar and were cultured aerobically. Organisms which failed to grow aerobically were considered to be the true anaerobes. Culturing followed using specific media such as mannitol, indole and sorbitol containing media, and specific standard microbiological tests were conducted, such as oxidase and coagulase. A lesion grading system, as described by Gonzalez et al, 1985, was followed to study the quantitative and qualitative reactions in the uterine tissue. This is a process described as under cell infiltration. Mucosa was considered Category 1 (normal) if the inflammatory cells count in 10 randomly selected high power fields (hpf; 7 mm) ranged from 0 to 20 cells. The cellular infiltrate was classified as Category 2, when the count was 21 to 40 cells/hpf; Category 3, when the cell count was 41 to 70/hpf; and, Category 4, when more than 70 cells/hpf; infiltrated the lamina propria. When the focal aggregates of cells were found the inflammatory score was described according to the number of focal aggregates in the tissue so category 2 included 1-3 focal aggregates; category 3 included 4-5 focal aggregates and category 5 included \geq focal aggregates. The degree of fibrosis was classified on the basis of the average number of layers of fibroblasts around the glands so; 1-3 fibroblast layers was considered as category 2, 4-5 fibroblast layers was considered as category 3 and \geq 6 fibroblast layer as category 4.

Results

Endometritis: Lesions of endometritis were

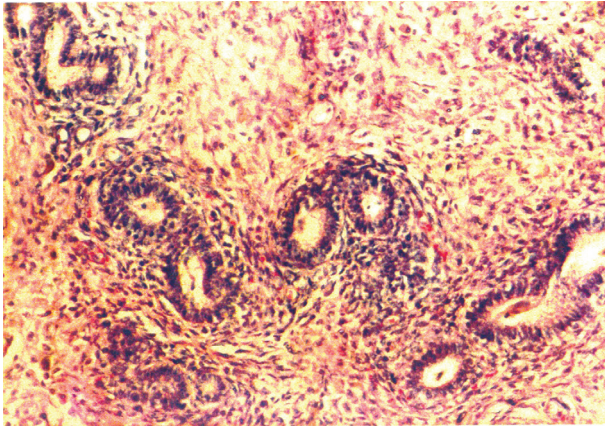


Figure 1. Mucosa of uterus of cow: Periglandular fibrosis, Inflammatory cell (H&E, X 250).

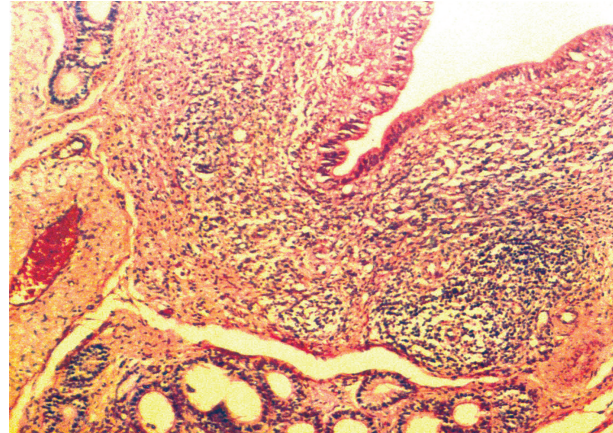


Figure 1. Submucosa of uterus of cow: lymphoid aggregation and hyperplasia (H&E, X125).

classified in 4 categories depending on the severity of the lesions (Table 1).

Category 1: Grossly, endometrium was congested and a varying quantity of mucus was present in the lumen. Microscopically, the mucosa showed edema and congestion of blood vessels. Neutrophils, lymphocytes, plasma cells, and mast cells, almost equal in number, were infiltrated into the lamina propria. Uterine glands showed no abnormality. 9 uteri of the cows (19.69%), and 36 uteri of the buffaloes (28.8%) were in this group.

Category 2: Grossly, endometrium was congested and edematous. The inflammatory cells included neutrophils, eosinophils, mast cells and lymphocytes. The latter was predominant and in some places formed aggregates. Fibrosis of 1-3 layers was found around the glands (Fig 1). The glandular epithelial cells showed vacuolation in their cytoplasm. 37 uteri of cows (18.68%) and 28 uteri of buffaloes (22.4%) were in this group.

Category 3: Grossly, the uterine mucosa showed grayish discoloration and the mucus was scanty. The inflammatory cells increased in number and the lymphoid aggregates were similar to lymphoid follicles (Fig 2). Fibroblasts around the degenerating uterine glands varied between 4 and 5 layers. 23 uteri of the cows (11.61%) and 22 uteri of the buffaloes (17.6%), were in this group.

Category 4: Grossly, the uterine mucosa was seen as dry and wrinkled in places, and showed grayish discoloration. Microscopically, in addition to a greater number of inflammatory cells per hpf, the most prominent feature observed was multifocal

lymphoid aggregates, especially around the blood vessels and uterine glands. Fibrosis around the glands was extensive. In some places the glands were atrophied, and in other places cystic. Cystic glandular changes were found in 8 out of 17 (47.0%) uteri of the cows in this group. 8.58% of the uteri of the cows and 4% of the uteri of the buffaloes were in this group. Metritis: Lesions of acute metritis, showing the infiltration of neutrophils and a few mononuclear cells in the mucosa muscular layer and serosa, were observed in 4.54% of the cows and 0.8% of the buffaloes. In two cows and one buffalo, it was noticed that there was a mild mononuclear cell infiltration in the lamina propria, with moderate fibrosis in the muscular layer. Perimetritis was seen in 6 cows (3.03%) and 2 buffaloes (1.6%), with varying degrees of thickening of the serosal layer. Mild fibrosis also extended into the muscle layer. The blood vessels in the muscular layer showed hypertrophy in their medial layer. Granulomatous metritis: Typical granulomatous inflammation in the mucosal layer, extending at places into the muscular layer, were found in 1 cow (0.5%) and 1 buffalo (0.8%). Their slides were examined for miliary tuberculosis and found to be negative for Acidfast bacilli. Haemangioma: In one cow (0.5%) and one buffalo (0.8%) there was an almost 3 cm diameter red area, observed grossly on the mucosal surface which revealed lesions similar to cavernous haemangioma. Large vascular spaces, separated by connective tissue septa and lined by large endothelial cells, were a microscopic feature.

40 cow samples and 42 buffalo samples were found to be positive in bacterial cultures isolated for

Table 1. Frequency of pathological lesions in the uterus of (cow- Buffalo) slaughtered in Ahwaz-Iran. ****Percent out of total uterus examined.

Lesions	Animal	cow		Buffalo		P
		Number	percent**	Number	percent**	
Endometritis in 4 category	Category 1	39	19.69	36	28.8	0.2829
	Category 2	37	18.68	28	22.4	0.9926
	Category 3	23	11.61	22	17.6	0.4055
	Category 4	17	8.58	5	4	0.0690
Acute metritis		9	4.54	1	0.8	0.0475
Chronic metritis		4	2.02	3	2.4	1
Perimetritis		6	3.03	2	1.6	.04728
Pyometra		1	0.5	1	0.8	1
External cysts		0	0	1	0.8	.04226
Granomatous metritis		1	0.5	1	0.8	1
Haemangioma		1	0.5	1	0.8	1
Total		138	100	101	100	-

Table 2. Correlation of pathological lesions in the uterus of cows and Bacterial isolation.

Type of bacteria	Grade I Normal	Grade II	Grade III	Grade IV	Perimetritis	Total
<i>Bacillus coagulans</i>		1(8.33%)			1(33.3%)	2(5%)
<i>Staphylococcus Epidermidis</i>	1(14.28%)	2(16.66%)				3(7.5%)
<i>Corynebacterium Pyogen</i> (<i>Arcanobacterium Pyogen</i>)	2(16.66%)	2(16.66%)	3(37.5%)	4(0.1%)	1(33.3%)	12(30%)
<i>Escherichia coli</i>		1(8.33%)		2(0.5%)		3(7.5%)
<i>Arcanobacterium Pyogen</i> + <i>Microcococcus</i>	1(14.28%)					1(2.5%)
<i>Acinetobacter</i> + <i>Microcococcus</i>	1(14.28%)					1(2.5%)
<i>Escherichia coli</i> + <i>Microcococcus</i>	1(14.28%)					1(2.5%)
<i>Alkalifecalis</i> + <i>Microcococcus</i>			1(12.5%)			1(2.5%)
<i>Corynebacterium Pyogen</i> + <i>Escherichia coli</i>				1(0.25%)		1(2.5%)
<i>Escherichia coli</i> + <i>Staphylococcus saprophiticus</i>		1(8.33%)				1(2.5%)
<i>Escherichia coli</i> + <i>Pasturella</i>	1(14.28%)					1(2.5%)
<i>Pasturella haemolítica</i>		1(8.33%)				1(2.5%)
<i>Staphylococcus Epidemidis</i> + <i>pasturella</i> + <i>Microcococcus</i>			1(12.5%)	1(0.25%)		2(5%)
<i>Pasturella</i>				1(0.25%)	1(33.3%)	2(5%)
<i>Acinetobacter</i>		2(16.66%)	1(12.5%)			3(7.5%)
<i>Microcococcus spp.</i>		2(16.66%)	2(25%)	1(0.25%)		5(12.5%)
Total	7(100%)	12(100%)	8(100%)	10(100%)	3(100%)	40(100%)

Arcanobacterium pyogenes, *E.coli*, *Streptococcus* spp, *Staphylococcus* spp, *Pasteurella*, *Acinetobacter*, *Salmonella* and *Proteus mirabilis* (Tables 2 and 3).

Discussion

Endometritis ranked first among the uterine abnormalities which is in conformity with previous

reports. The lesions of endometritis observed in the present study correlate well with endometrial lesions described in repeat breeder cows. (Gonzalez et al., 1985; Schmidt et al., 2006). In the first 10 days after calving *Streptococcus* spp, *Staphylococcus* spp, and *Bacillus* spp, were mostly isolated from the cow uterus and showed no clinical signs of puerperal metritis, while *Arcanobacterium Pyogenes*, *Escherichia*

Table 3. Correlation of pathological lesions in the uterus of Buffaloes and Bacterial isolation.

Type of bacteria	Grade I Normal	Grade II	Grade III	Grade IV	Perimetritis	Total
<i>Acinetobacter</i>		2(15.38%)				2(4.79%)
<i>Aeromonas</i>	1(14.2%)					1(2.38%)
<i>Arcanobacterium pyogenes</i> (<i>Corynebacterium pyogenes</i>)	1(14.2%)		1(7.6%)	4(50%)		4(9.52%)
<i>Arcanobacterium pyogenes Pseudotuber cuosis</i>		1(7.6%)	1(7.6%)			2(4.79%)
<i>Corynebacterium Ulcerans</i>	1(14.2%)					1(2.38%)
<i>Corynebacterium equi</i>				1(12.5%)		1(2.38%)
<i>Escherichia coli</i>	1(14.2%)	1(7.6%)	3(23.7%)	2(25%)	1(100%)	8(19%)
<i>Enterobacter. Aerogenes</i>			1(7.6%)	1(12.5%)		2(4.79%)
<i>Enterobacter</i>		1(7.6%)				1(2.38%)
<i>Lacto bacillus</i>			1(7.6%)			1(2.38%)
<i>Proteus. Mirabilis</i>			1(7.6%)			1(2.38%)
<i>Pseudomonas.- Aeruginosa</i>		1(7.6%)				1(2.38%)
<i>Pseudomonas.</i>			1(7.6%)			1(2.38%)
<i>Maltophilia</i>						
<i>Micococcus</i>		1(7.6%)	1(7.6%)			2(4.79%)
<i>Staphylococcus Eepidermidis</i>	1(14.2%)					1(2.38%)
<i>Non haemolytic Staphylococcus</i>	2(28.5%)	2(15.38%)				4(9.52%)
<i>Non haemolytic Staphylococcus Aeromonas</i>		1(7.6%)				1(2.38%)
α haemolyticus <i>Streptococcus</i>		1(7.6%)				1(2.38%)
β haemolyticus <i>Streptococcus</i>		1(7.6%)				1(2.38%)
<i>Salmonella</i>		1(7.6%)				1(2.38%)
<i>Alkaligenes faecalis</i>			1(7.6%)			1(2.38%)
<i>Corynebacterium. Haemolyticum</i>			2(12.38%)			2(4.79%)
Total	7(100%)	13(100%)	13(100%)	8(100%)	1(100%)	42(100%)

coli and different Gram-negative obligate anaerobic bacteria were predominant in the uteri of clinically ill animals. (Huszenicza et al., 2004). At this time, there might be numerous bacteria in the uterus. In this respect, *A. pyogenes* and *E. coli* combined with certain Gram negative anaerobic bacteria are considered the main pathogens. This conclusion was drawn from many different studies: *A. pyogenes* (33-83%), Gram negative anaerobic (49-67%), and coliform (67-85%) were isolated in cows with puerperal metritis (Sheldon et al., 2004). In another study, the results of the bacterial culture of 159 endometrial biopsies of 97 dairy cows indicated some inflammatory changes. 11% of the biopsies were found positive for both aerobic and anaerobic culture. *Streptococci*, *Escherichia coli* and *Actinomyces pyogenes* were found to be the most common isolates (Bonnett et al., 1995). In 42 buffaloes, the most common predisposing factor causing metritis was placenta retention (52.4%), and the most prevalent bacteria in uterine lumen were *Escherichia coli* (18.5%), *Actinomyces pyogenes* (16.7%), *Staphylococcus aureus* (13.0%), and

Fusobacterium necrophorum (9.3%). High levels of polymorphonuclear cells were observed in buffaloes infected with *A. pyogenes* (62.1%) and gram-negative anaerobic bacteria (76.4%), which suggest that these bacteria play a role in causing gram-negative anaerobes and other facultative pathogens including *A. pyogenes* in severe uteri inflammations. A series of studies confirmed that most of the clinical and reproductive consequences might be attributed to the presence of certain non-specific pathogens, mainly *Actinomyces pyogenes*, either alone or in company with other bacteria like *E. coli* and Gram-negative obligate anaerobes (Azawi et al., 2007; Sheldon et al., 2004). *Actinomyces pyogenes* was the most common bacteria isolate and *Fusobacterium nucleatum*, *Proteus mirabilis* and *Bacterioides melaninogenicus* were also frequently observed in cows inflicted with metritis. The present findings are in agreement with the studies of various researchers (Sheldon and Dobson, 2004). In another study, uteri of 30 adult river buffaloes were studied during the luteal phase. The mast cells distribution at perimetrium

and myometrium were significantly higher than in the follicular phase. The distribution of these cells at deep, middle and superficial areas of the endometrium in the luteal phase were significantly higher than in the follicular phase (Shahrooz et al., 2005). Pyometra occurs as an aftermath of endometritis or metritis. The color and consistency of the exudates are viscid, brown and creamy yellow which results from the infliction of *Escherichia coli* and *Streptococcus*. The degenerative and infiltrative processes leads to an excessive damage of luminal and glandular epithelium, and may extend to the entire diameter of the uterine wall and even sometimes proceeding to the serosa and the suspensor ligaments (Sheldon et al., 2004; Foldi et al., 2006). In this study two animals, 1 cow (0.5%) and 1 buffalo (0.8%) were found negative in terms of Acid fast bacilli for miliary tuberculosis. Uterine neoplasm is not a common phenomenon among domestic animals and is mostly reported in the cow (McEntee, 1990). Lesions similar to cavernous haemangioma were described in 7 buffaloes and cows in the abattoir survey (Youssef et al., 1991). Although this study was carried out on animals with an unknown breeding history, comparing samples with repeat breeders was not possible. There is a possibility that the majority of animals showing endometritis in this survey were repeat breeders or infertile, as, usually, only infertile animals are sent to the slaughterhouse. Many researchers have suggested improvement in the breeding performance of animals with a low grade of endometritis, upon their treatment (Azawi et al., 2007; Bondurant et al., 1991). Conducting a clinical study on the infertile animals of this region is highly recommended to reduce and save farmers from economic losses.

Acknowledgement

I would like to express appreciation to Dr. Jamshidian, Mr. Ghalaympour and Mrs. M. Masbogh for their technical assistance. This study was supported by the Faculty of Veterinary Medicine, ShahidChamran University, Ahwaz, Iran.

References

1. Azawi, O.I., Omran, S.N., Hadad, J.J. (2007) Clinical, bacteriological and histopathological study of toxic metritis in Iraqi buffalo. *J. Dairy. Sci.* 90: 4654-4660.
2. Bondurant, R.H. (1991) Inflammation in bovine female reproductive tract. *J. Anim. Sci.* 77: 101-110.
3. Bonnett, B.N., Martin, S.W. (1995) Pathoanalysis of peripartum and postpartum events, rectal palpation findings, endometrial biopsy result and reproductive performance in Holstein-Friesian dairy cows. *Prev. Vet. Med.* 21: 279-288.
4. Fold, J.M., Kulcsar, A., Pecs, C., Huyghe, P., Lohuis, Huszenicza, G.Y. (2006) Bacterial complication of postpartum uterine involution in cattle. *Anim. Rep. Sci.* 96: 265-281.
5. Gonzalez, H.E., Crowell, W.A., Caudle, A.B., Thompson, F.N. (1985) Morphometric studies of the bovine uterus: microscopic lesions and retrospective history. *Anim. J. Vet. Res.* 46: 2588-2589.
6. Huszenicza, G., Janosi, S., Gaspard, A., Kulcsar, M. (2004) Endocrine aspects in pathogenesis of mastitis in postpartum dairy cows. *Anim. Rep. Sci.* 83:389-400.
7. Khan, M.Z. (1991) Prevalence and pathology of disease condition of ovaries of Nili-Ravi buffaloes. *Buff. J.* 7:215-223.
8. Kask, K., Gustafsson, H. (1998) Bacteriological and histological investigation of the postpartum bovine uterus in two Estonian dairy herds. *Acta. Vet. Scand.* 39: 423-432.
9. McEntee, K. (1990) The uterus: atrophic, metaplastic, and proliferative lesions. In: *Reproductive Pathology of Domestic Animals*. Academic Press. San Diego. USA. p. 167-190.
10. McGavin, M.D., Zachary, J.F. (2007) *Pathologic Basis of Veterinary Disease*. (4th ed.). Mosby. Elsevir. St. Louis, USA.
11. Murray, R.D., Allison, J.D., Gard, R.D. (1990) Bovine endometritis: comparative efficacy of alfaprostol and intrauterine therapies, and other factors influencing clinical success. *Vet. Rec.* 127: 86-90.
12. Schimdt, S., Gerber, D., Soley, J., Aire, T.A., Boos, A. (2006) Histo-morphology of the uterus and early placenta of the african buffalo (*Synceruscaffer*) and comparative placentome morphology of the african buffalo and cattle (*Bostaurus*). *Placent. J.* 27: 899-

911.

13. Shahrooz, R., Hasanzadeh, S., Mardani, K. (2005) Comparative study of the plasma cells and mast cells distribution in uterus at follicular and uterine phases of estrus cycle in the river buffalo. *Indian. J. Anim. Sci.* 75: 1253-1256.
14. Sheldon, M., Dobson, H. (2004) Postpartum uterine health in cattle. *Anim. Sci. Rep.* 82: 295-306.
15. Sheldon, M., Rycroft, A.N., Zhou, C. (2004) Association between postpartum pyrexia and uterine bacterial infection in dairy cattle. *Vet. Rec.* 154: 289-293.
16. Youssef, F.A., Hegazy, A.A., Shalash, M.R., Ismail, E.M. (1991) Studies of histopathological reproductive changes in buffalo cows. *Buff. J.* 1: 87-88.

بررسی مقایسه‌ای باکتریولوژی کوبا تو لوزیک بین رحم‌های گاو و گاو میش در منطقه اهواز - ایران

منصور سیاری^{۱*} محمد فرهنگ نیا^۲ شمس الدین قائم مقامی^۳ راویندانت شارما^۴

(۱) گروه پاتوبیولوژی، دانشکده دامپزشکی شیراز، شیراز، ایران.

(۲) سازمان دامپزشکی کشور، تهران، ایران.

(۳) عضو هیئت علمی موسسه تحقیقات کشاورزی و منابع طبیعی اراک، اراک، ایران.

(۴) گروه پاتوبیولوژی، دانشکده دامپزشکی، دانشگاه شهید چمران اهواز، اهواز، ایران.

(دریافت مقاله: ۱۱ خردادماه ۱۳۹۰، پذیرش نهایی: ۵ مهرماه ۱۳۹۰)

چکیده

زمینه مطالعه: عفونت‌های باکتریایی رحم عامل و مسئله مهم در مدیریت تولید است. **هدف:** بررسی ضایعات پاتولوژیک و تعیین عوامل باکتریایی در رحم گاو و گاو میش و مقایسه آنان در منطقه اهواز بوده است. **روش کار:** در بررسی ۱۳۸ و رحم گاو و ۱۰۱ رحم گاو میش بعد از ثبت ضایعات ماکروسکوپی یک بارش دادن از مسیر گردن جهت آزمایشات میکروبیولوژیکی نمونه برداری انجام گرفت سپس نمونه‌ها در فرمالین ۱۰٪ ثابت شدند و به روش پارافین مقاطع به ضخامت ۶ میکرون تهیه و بعد از رنگ آمیزی با هماتوکسیلین و ائوزین ضایعات پاتولوژیک ثبت گردید. در نهایت یافته‌های میکروبیولوژیک هر نمونه با ضایعات پاتولوژیک خودش مقایسه و مطابقت گردید. **نتایج:** شامل آندومتریس در ۴ گروه طبقه بندی گردید. طبقه بندی اول ۳۹ گاو (۱۹/۶۹٪)، ۳۶ گاو میش (۲۸/۸٪)، طبقه بندی دوم ۳۷ گاو (۱۸/۶۸٪)، ۲۸ گاو میش (۲۲/۴٪) طبقه بندی سوم ۲۳ گاو (۱۱/۶۱٪)، ۲۲ گاو میش (۱۷/۶٪)، طبقه بندی چهارم ۱۷ گاو (۸/۵۸٪)، ۵ گاو میش (۴٪). متریت حاد (۹ گاو، ۱ گاو میش)، متریت مزمن ۴ گاو (۲/۰۲٪)، ۳ گاو میش (۲/۴٪)، متریت گرانولوماتوزی ۱ گاو (۰/۵٪)، ۱ گاو میش (۰/۵٪)، پری متریت ۶ گاو (۳/۳٪)، ۲ گاو میش (۱/۶٪)، پیومتر ۱ گاو میش (۰/۵٪) کیست‌های خارجی ۱ گاو میش (۰/۸٪) همانژیوم ۱ گاو (۰/۵٪)، ۱ گاو میش (۰/۸٪). در مجموع ۴۰ نمونه از رحم‌ها در گاو دارای کشت مثبت باکتریایی بودند و در ۴۲ نمونه از رحم گاو میش با باکتری جدا گردید. طیف وسیعی از باکتری‌ها شامل کورینه باکتریوم، اشرشیا کلی، استافیلوکوک، استرپتوکوک، سالمونلا، پروتئوس، پاستورلا مشخص گردید. **نتیجه‌گیری نهایی:** عفونت پنهان وجود دارد و ضررهای اقتصادی ناشی از آن در چرخه تولید، با بررسی کلینیکی پاراکلینیکی در این ناحیه می‌تواند حداقل باشد.

واژه‌های کلیدی: رحم، گاو، گاو میش، ضایعه، میکروبیولوژی.

(* نویسنده مسؤول: تلفن: +۹۸(۷۱۱)۲۲۸۶۹۴۰، نمابر: +۹۸(۷۱۱)۲۲۸۶۹۵۰، Email: sayyari@shirazu.ac.ir