

Radiographic measurements of front feet of the sound Akhal-Teke horses

Masoudifard, M.^{1*}, Vajhi, A.R.¹, Mansouri, Sh.², Molazem, M.¹, Bahonar, A.R.³, Zehtabvar, O.⁴

¹Department of Surgery and Radiology, Faculty of Veterinary Medicine, University of Tehran, Tehran, Iran

²Private Veterinary Practitioner, Tehran, Iran

³Department of Food Hygiene and Quality Control, Faculty of Veterinary Medicine, University of Tehran, Tehran, Iran

⁴Department of Basic Sciences, Faculty of Veterinary Medicine, University of Tehran, Tehran, Iran

Key words:

Akhal-Teke horse, front feet, measurement, radiography

Correspondence

Masoudifard, M.

Department of Surgery and Radiology, Faculty of Veterinary Medicine, University of Tehran, Tehran, Iran

Tel: +98(21) 61117079

Fax: +98(21) 66438327

Email: mmfard@ut.ac.ir

Received: 24 December 2013

Accepted: 3 March 2014

Abstract:

BACKGROUND: The Akhal-Teke is an ancient horse originating from Asia where it was used by nomadic tribes and used as a warhorse. Lameness examinations require proper interpretation of clinical and radiographic findings. Therefore, understanding of normal radiographic findings of the foot is necessary. Although the radiographic appearance of the normal foot must be understood to recognize abnormalities, there are no studies examining the normal hoof and digital soft tissues in Akhal-Teke horses. **OBJECTIVES:** The purpose of the study reported here was to determine a normal radiographic appearance and morphometry of the distal phalanx and its related soft tissue in mature Akhal-Teke racehorses without any clinical signs of lameness and foot problems. **METHODS:** Radiography of the distal phalanx and associated soft-tissue structures of the front feet of 10 healthy pure Akhal-Teke horses were performed to determine normal radiographic appearance and morphometry. Lateromedial radiographic views of each front distal phalanx were used to measure important distances, angles and ratios of the hoof wall. All the measurements from lateromedial radiographs were multiplied by the magnification correction factor to gain the actual distances. **RESULTS:** Mean \pm SD thickness of the soft tissues dorsal to the middle aspect of distal phalanx was 18.3 ± 1.22 mm. There was not any significant difference between left and right digits for any radiographic determination. **CONCLUSIONS:** This study introduced S-Founder and CF-Founder as important criteria in evaluating laminitis and sinking of P3.

Introduction

The Akhal-Teke is an ancient horse originating from Asia where it was used by nomadic tribes and used as a warhorse. The Akhal-Teke is among the most elegant of the world's horses. The conformation of The Akhal-Teke can be favorably compared to the Persian Arab, another breed of ancient origin.

Lameness and prepurchase examination require

proper interpretation of clinical and radiographic findings. Therefore, understanding the normal radiographic findings of the foot is necessary. The most important disease of horses' limbs is laminitis which needs rapid diagnosis on the early taken radiographs. Radiography of the distal phalanx (DP) is necessary, so one must know the normal radio-graphic findings.

Although the radiographic appearance of the normal foot must be understood to recognize subtle abnormalities (Rendano and Grant, 1978), no study

has examined the normal hoof and digital soft tissues in Akhal-Teke horses. However, these findings were previously studied in Thoroughbred, Hanoverian, Pony, and Arab breeds horses. Bushe et al. (1988) have mentioned the relation between the third phalanx angle and coffin angle in sound horses. Qualitative and morphometric radiographic findings in the distal phalanx and digital soft tissue for sound and footsore thoroughbreds were compared by Linford (1987). The mean thickness of the soft tissue dorsal to the distal phalanx was measured and compared between the two groups. Linford et al. (1993) have also qualified distal phalanx and digital soft tissue findings of sound Thoroughbred racehorses and matched the data with their racing performance. Cripps and Eustace (1999) have measured the normal radiographic findings of the feet in normal horses with relevance to laminitis.

The purpose of the study reported here was to determine a normal radiographic appearance and morphometry of the distal phalanx and its related soft tissue in mature Akhal-Teke racehorses without any clinical signs of lameness and foot problems.

Materials and Methods

Case selection: A total of 10 healthy pure Akhal-Teke horses were selected from one of the stables in the east of Tehran. All the horses had their own history and certificates and they were approximately similar in size and weight. They included 5 males and 5 females and were 7.7 ± 3.3 (mean \pm SD) years old with the same diet and training management and also a same farrier. There was no history of lameness and limb abnormality for at least one year prior to the study. Each horse was observed trotting in circles to the left and right, and walking and trotting in a straight line.

Radiography: Radiographs were made using a portable 10 mAmp; 80 kVolt X-ray generator with variable timer. Care was taken to ensure straight lateromedial projections without obliquity by aligning the radiographic beam so that it passed perpendicularly to the sagittal plane through the foot while being centered in the middle of the hoof 3Cm proximal to the bearing surface. The hoof also was placed on a 7Cm thick wooden block so that the distance of the center of the beam to ground surface

was 10 Cm. To differentiate the bearing surface from the block a metal bar was placed on the block surface. The focus-film distance for each projection was 75Cm.

All horseshoes were removed and the frog sulci and the sole surface of the digits were cleaned prior to radiography. A layer of Barium Sulfate contrast agent with proper concentration was rubbed on the dorsal surface of hoof wall, sole surface, and frog sulci for better visualization of these parts on the radiographs. A metal marker was used to determine the amount of radiographic magnification as well as to delineate the coronary band at the lateromedial radiographs (Figure 1).

All the measurements from lateromedial radiographs were multiplied using the magnification correction factor (MCF) to gain the actual distances. The MCF was determined by dividing the actual metal marker length to the length of the radiographic image of the marker.

Morphometric analysis of the radiographs: In each obtained radiograph, 7 distances, 7 angles, and 3 ratios of the distal phalanx and the hoof wall were measured. The morphometric assessments were made as follows:

1. The hoof wall and its soft tissue thickness included 3 regions:

- a) Total soft tissue thickness dorsal to the distal aspect of the DP (STTD) (Figure 2 A),
- b) Total soft tissue thickness dorsal to the middle aspect of the DP (STTM) (Figure 2 B),
- c) Total soft tissue thickness dorsal to the proximal aspect of the DP (STTP) (Figure 2 C).

They were the shortest distance between the dorsal surface of the hoof wall and the dorsal cortex of DP.

2. Palmarocortical length (PCL) of the DP: The distance from the tip of the solar margin to the middle of the articulation between the phalanx and the navicular bone (Figure 2).

3. The ratios of the wall thickness to the PCL: These ratios assessed by proper thickness of STTD, STTM, and STTP expressed as a percentage.

4. Hoof wall axis (S-angle): The caudal angle formed between a line along the dorsal surface of the hoof wall and a line along the bearing surface of the hoof (Figure 2).

5. Distal phalanx axis (T-angle): The caudal angle

formed between a line along the dorsal cortex of the phalanx and a line along the bearing surface of the hoof wall (Figure 2).

6. The difference between S and T-angles (H-angle).

7. Middle phalanx axis (U-angle): The caudal angle formed between a line through the central axis of the middle phalanx and a line along the bearing surface of the hoof wall (Figure 2).

8. The difference between U and T-angle (R-angle).

9. D-Founder: The perpendicular distance from the horizontal line through the extensor process to the horizontal line through the coronary band (Figure 2).

10. S-Founder: The perpendicular distance from the horizontal line through the highest point of the sole surface which was robbed by contrast agent (Barium Sulfate) in front of the frog to the tip of the DP (Figure 2).

11. CF-Founder: The perpendicular distance from the horizontal line through the top point of the frog corium to the extensor process (Figure 2).

12. P-angle: A caudal angle formed between a line through the palmarocortical and a line through dorsal surface of the DP (Figure 2).

13. J-angle: A caudal angle formed between a line through the solar margin of the distal phalanx and a line along the bearing surface of the hoof.

Statistical evaluation: All the obtained data were analyzed by SPSS software (Ver. 11.5). The average, standard deviation, and minimum and maximum data were determined as standard measurements in Akhal-Teke horses. The paired T-test was also used to compare the measurements between males and females, right and left front feet.

Results

The result of the measurements of the distances, ratios, and angles of morphometric variables of distal phalanx and hoof in lateral radiographs of total, left and right front feet, and male and female Akhal-Teke horses are shown in tables 1 and 2.

In this research, there was no statistically significant difference ($p>0.10$) in measured parameters between the left and right fore limb radiographs. Data comparison of the distal phalanx and hoof box in male and female horses showed significant differences in

Table 1. Mean \pm Standard Deviation (SD) measurements of the distances and ratios of morphometric variables of distal phalanx and hoof in lateral radiographs of front feet of total, left and right front feet, and male and female Akhal-Teke horses.

Variables	Mean (SD) of total	Mean (SD) of Left & Right	Mean (SD) of Male & Female
STTD (mm)	18.0 (1.04)	L: 17.9 (1.16) R: 18.1 (0.97)	M: 17.5 (1.14) F: 18.4 (0.78)
STTM (mm)	18.3 (1.22)	L: 18.5 (1.39) R: 18.2 (1.08)	M: 17.9 (1.31) F: 18.8 (0.99)
STTP (mm)	18.5 (1.23)	L: 18.6 (1.41) R: 18.5 (1.09)	M: 17.8 (1.23) F: 19.3 (0.63)
PCL (mm)	64.3 (3.37)	L: 64.1 (3.75) R: 64.5 (3.15)	M: 62.5 (2.38) F: 66.1 (3.31)
STTD/PCL (%)	28.0 (1.80)	L: 27.9 (2.12) R: 28.1 (1.52)	M: 28.1 (1.23) F: 27.9 (2.30)
STTM/PCL (%)	28.5 (1.86)	L: 28.9 (1.98) R: 28.2 (1.77)	M: 28.6 (1.40) F: 28.5 (2.31)
STTP/PCL (%)	28.9 (1.51)	L: 29.0 (1.57) R: 28.7 (1.51)	M: 28.5 (1.07) F: 29.3 (1.82)
D-Founder (mm)	6.2 (2.93)	L: 6.8 (3.05) R: 5.6 (2.82)	M: 4.9 (3.42) F: 7.5 (1.62)
S-Founder (mm)	10.7 (3.65)	L: 10.6 (3.62) R: 10.8 (3.87)	M: 10.8 (4.38) F: 10.6 (2.98)
CF-Founder (mm)	48.6 (5.96)	L: 49.0 (7.54) R: 48.2 (4.20)	M: 45.2 (1.73) F: 52.0 (6.80)

Table 2. Mean \pm Standard Deviation (SD) measurements of the angles of morphometric variables of distal phalanx and hoof in lateral radiographs of front feet of total, left and right front feet, and male and female Akhal-Teke horses.

Variables	Mean (SD) of total	Mean (SD) of Left & Right	Mean (SD) of Male & Female
S-angle (Degree)	49.6 (7.33)	L: 51.5 (9.70) R: 47.6 (3.31)	M: 47.5 (2.99) F: 51.7 (9.73)
T-angle (Degree)	48.5 (2.47)	L: 48.7 (1.79) R: 48.3 (3.10)	M: 48.6 (2.02) F: 48.4 (2.97)
H-angle (Degree)	0.4 (2.58)	L: 0.2 (2.91) R: 0.6 (2.33)	M: 1.1 (2.66) F: -0.25 (2.44)
U-angle (Degree)	49.2 (6.23)	L: 47.0 (5.44) R: 51.4 (6.47)	M: 46.8 (6.31) F: 51.6 (5.40)
R-angle (Degree)	-0.2 (5.36)	L: 1.7 (5.21) R: -2.1 (5.05)	M: 1.8 (6.54) F: -2.2 (3.00)
P-angle (Degree)	36.8 (2.48)	L: 36.5 (2.17) R: 37.2 (2.83)	M: 37.2 (2.51) F: 36.5 (2.52)
J-angle (Degree)	3.6 (2.77)	L: 4.6 (1.42) R: 2.7 (3.49)	M: 2.4 (2.34) F: 4.9 (2.70)

STTP ($p<0.01$), PCL ($p<0.05$), J-angle ($p<0.05$), D-Founder ($p<0.05$), and CF-Founder ($p<0.01$).

Discussion

Since it is very important to reduce failure in measuring the DP and the middle phalanx for

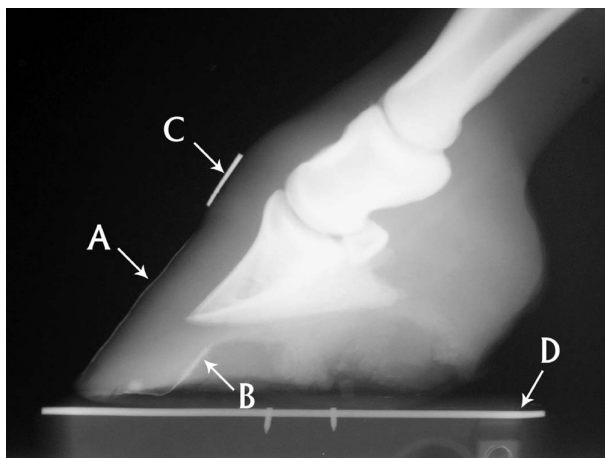


Figure 1. Lateromedial radiograph of the foot of an Akhal-Teke horse. A. Hoof wall, B. Sole surface, C. Metal marker, D. Metal bar was placed on the wooden block surface.

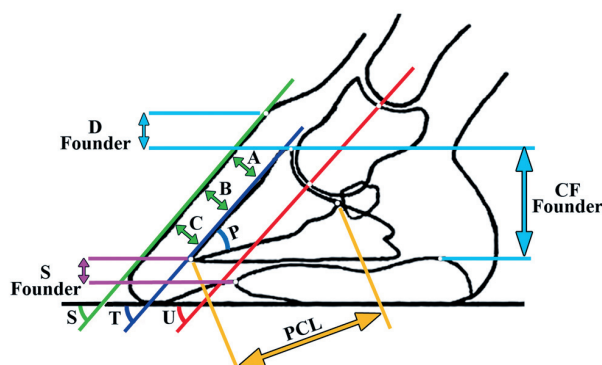


Figure 2. Schematic drawing of the foot illustrating measured distances and angles on lateromedial radiographs. PCL: Palmarocortical length, S-angle: Hoof wall, T-angle: Distal phalanx axis, U-angle: Middle phalanx axis, D-Founder: The perpendicular distance from the horizontal line through the extensor process to the horizontal line through the coronary band, S-Founder: The perpendicular distance from the horizontal line through the highest point of the sole surface which was robbed by contrast agent (Barium Sulfate) in front of the frog to the tip of the DP, CF-Founder: The perpendicular distance from the horizontal line through the top point of the frog corium to the extensor process, P-angle: A caudal angle formed between a line through the palmarocortical and a line through dorsal surface of the DP.

laminitis detection, the limb must be in an exact perpendicular position, and weight bearing is necessary too.

Linford et al. (1993) reported that the widest thickness at the hoof wall and its soft tissue was 18 mm. O'Brien and Baker (1986) stated that increasing in the hoof wall thickness and its related soft tissue to

more than 20 mm is the first radiographic sign of laminitis. This increase is due to the inflammation of the laminae and will be seen on lateromedial radiographs almost 48 to 72 hours after laminitis start to grow. None of the hoof wall and its related soft tissue thickness was more than 20 mm in the present study. There are some differences between hoof wall thickness and soft tissue measurements in this study and other studies, especially the Linford et al. (1993), Cripps and Eustace (1999) and Golshani (2000), which can be due to the differences in breeds, ages, hoof cares, sport activities, or the nutrition of the examined horses.

Linford et al. (1993) and Peloso et al. (1996) have reported the thickness of the hoof wall and its related soft tissue less than 30% of the palmarocortical length of the DP in sound horses, and they stated that a higher percent will be a sign for laminitis. In this study, the mean of this criterion was less than 30% in all three levels, although there were sporadic cases with a percent of more than 30% without evident of laminitis.

Cripps and Eustace (1999) and Baxter (1996) stated that measuring the D-Founder, which is the horizontal line through the extensor process to the coronary band, is a sinking diagnostic criterion in Laminitis. Since finding the coronary band location will be almost difficult when it is inflamed or sinker, in this study the CF-Founder and S-Founder criteria were introduced to measure the sinking occurrence more accurately. The average of D-Founder in this study was 6.2mm which seems to be more than the amount of the previous reports in other horse breeds (Baxter 1996, Cripps and Eustace 1999). It may be because of the larger hoof box size, the longer hoof wall, and more penetration of the distal phalanx into the hoof box in Akhal-Teke horses.

Significant differences in STTP, PCL, J-angle, D-Founder, and CF-Founder between female and male horses may be due to varieties in their amount of sport activities and pregnancy periods in females.

Linford et al. (1993) propounded that existence of palmarocortical resorption, which cause an obvious convexity on the palmarocortical region on the lateral radiographs, is a sign for laminitis and founder. In this relation, Golshani (2000) assessed a new criterion called P-angle. This criterion may be useful as an indicator of laminitis.

The results of the present study can be used as a reference in further laminitis investigations on Akhal-Teke horses.

Acknowledgements

The authors gratefully acknowledge the contributions and help of Dr. F. Adibhashemi and D. Faskhoodi.

References

1. Baxter, G.M. (1996) Diagnosing and treating acute laminitis. *Vet Med.* 91: 940-952.
2. Bushe, T., Turner, T.A., Poulos, P.W., Harwell, N.M. (1988) The effect of hoof angle on coffin, pastern and fetlock joint angles. *Proc Am Assoc Equine Practnrs.* 33: 729-738.
3. Cripps, P.J., Eustace, R.A. (1999) Radiological measurements from the feet of normal horses with relevance to laminitis. *Equine Vet J.* 31: 427-432.
4. Eliashar, E., McGuigan, M.P., Wilson, A.M. (2004) Relationship of foot conformation and force applied to the navicular bone of sound horses at the trot. *Equine Vet J.* 36: 431-435.
5. Linford, R.L., O'Brien, T.R., Trout, D.R. (1993) Qualitative and morphometric radiographic findings in the distal phalanx and digital soft tissue of sound thoroughbred racehorses. *Am J Vet Res.* 54: 38-51.
6. Peloso, J.G., Cohen, N.D., Walker, M.A., Watkins, J.P., Gayle, J.M., Moyer, W. (1996) Case-control study of risk factors for the development of laminitis in the contralateral limb in Equidae with unilateral lameness. *J Am Vet Med Assoc.* 209: 1746-1749.
7. Rendano, V.T., Grant, B. (1978) The equine third phalanx: its radiographic appearance. *J Am Vet Radiol.* 19: 125-135.
8. Riggs, C.M. (2006) Osteochondral injury and joint disease in the athletic horse. *Equine Vet Educ.* 18: 100-112.
9. Van Eps, A.W., Pollitt, C.C. (2006) Equine laminitis induced with oligofructose. *Equine Vet J.* 38: 203-208.
10. Van Eps, A.W., Pollitt, C.C. (2009) Equine laminitis model: Lamellar histopathology seven days after induction with oligofructose. *Equine Vet J.* 41: 735-740.

اندازه‌گیری‌های رادیوگرافی ناحیه سم اندام حرکتی پیشین در اسب‌های آخال تکه سالم

مجید مسعودی فرد^{۱*}، علیرضا وجهی^۱، شهرام منصور^۲، محمد ملازم^۱، علیرضا باهنر^۳، امید زهتاب ور^۴

(۱) گروه جراحی و رادیولوژی، دانشکده دامپزشکی دانشگاه تهران، تهران، ایران

(۲) دامپزشک بخش خصوصی، تهران، ایران

(۳) گروه بهداشت و کنترل مواد غذایی، دانشکده دامپزشکی دانشگاه تهران، تهران، ایران

(۴) گروه علوم پایه، دانشکده دامپزشکی دانشگاه تهران، تهران، ایران

(دریافت مقاله: ۳ دی ماه ۱۳۹۲، پذیرش نهایی: ۱۲ اسفند ماه ۱۳۹۲)

چکیده

زمینه مطالعه: آخال تکه یک نژاد اسب باستانی با خاستگاه آسیایی است که توسط قبایل چادرنشین به عنوان اسب جنگی استفاده می‌شده است. معاینات لنگش نیازمند تفسیر درست یافته‌های بالینی و رادیوگرافی هستند. بنابراین آشنایی با وضعیت طبیعی رادیوگرافی اندام حرکتی ضروری است. در عین حال، تاکنون گزارشی در خصوص نمای رادیوگرافی ناحیه سم سالم در اسب آخال تکه منتشر نشده است. هدف: این مطالعه با هدف مشخص کردن نمای طبیعی رادیوگرافی و مرفومتري بند آخر انگشت و بافت نرم مرتبط به آن در اسب نژاد آخال تکه بالغ بدون هیچگونه علائم لنگش و مشکلات اندام حرکتی، انجام شد. روش کار: برای مشخص کردن نمای طبیعی رادیوگرافی و مرفومتري، از ناحیه سم اندام حرکتی پیشین ۱۰ اسب سالم نژاد آخال تکه رادیوگراف تهیه شد. از نمای رادیوگرافی جانبی سم اندام پیشین برای اندازه‌گیری اندازه‌های مهم، زاویه‌ها و نسبت‌های دیواره سم استفاده شد. برای به دست آوردن اندازه‌های واقعی تمام اندازه‌گیری‌ها، در ضریب تصحیح بزرگنمایی ضرب می‌شد. نتایج: در این مطالعه میانگین و انحراف معیار ضخامت بافت نرم قسمت پشتی - میانی بند سوم $1/2 \pm 1/3$ mm به دست آمد. افزایش ضخامت دیواره سم اولین علامت رادیوگرافی لنگش حاد است. هیچ تفاوت معنی‌داری بین انگشتان راست و چپ وجود نداشت. نتیجه‌گیری نهایی: این مطالعه S-Founder و CF-Founder را به عنوان معیارهای مهم ارزیابی لنگش و فروافتادگی (sinking) بند سوم انگشت معرفی کرد.

واژه‌های کلیدی: اسب آخال تکه، سم، اندازه‌گیری، رادیوگرافی

*نویسنده مسؤول: تلفن: ۶۱۱۱۷۰۷۹ (۲۱) ۹۸+، شماره: ۶۶۴۳۸۳۲۷ (۲۱) ۹۸+، Email: mmfard@ut.ac.ir