

## Doppler echocardiographic findings in tissue engineered aortic valve in a sheep model

Mokhber Dezfouli, M.R.<sup>1,4</sup>, Tavanaeimanesh, H.<sup>1,4\*</sup>, Dehghan, M.M.<sup>2,4</sup>, Hayati, F.<sup>2</sup>, Sadeghian Chaleshtori, S.<sup>1,4</sup>, Akbarein, H.<sup>3</sup>, Pournaghi, P.<sup>5</sup>

<sup>1</sup>Department of Internal Medicine, Faculty of Veterinary Medicine, University of Tehran, Tehran, Iran

<sup>2</sup>Department of Surgery and Radiology, Faculty of Veterinary Medicine, University of Tehran, Tehran, Iran

<sup>3</sup>Department of Food Hygiene and Quality Control, Faculty of Veterinary Medicine, University of Tehran, Tehran, Iran

<sup>4</sup>Institute of Biomedical Research, Faculty of Veterinary Medicine, University of Tehran, Tehran, Iran

<sup>5</sup>Department of Biology, Payame Noor University, Tehran, Iran

### Key words:

echocardiography, heart, hemodynamic, tissue engineer, valve

### Correspondence

Tavanaeimanesh, H.

Department of Internal Medicine, Faculty of Veterinary Medicine, University of Tehran, Tehran, Iran

Tel: +98(21) 66431103

Fax: +98(21) 66933222

Email: hamidtavana@ut.ac.ir

Received: 11 January 2016

Accepted: 16 March 2016

### Abstract:

**BACKGROUND:** Heart valve diseases are considered a common disease in human and animals, and valve replacement is an option for treatment of valvular diseases. **OBJECTIVES:** In this study efficacy of a tissue engineered valve in thoracic aorta was evaluated with transthoracic echocardiography. **METHODS:** This study was undertaken on 6 male sheep. Echocardiography was performed on all sheep 24 hours before surgery and repeated 24 hours (D1), 2 weeks (W2) and 4 weeks (W4) after surgery. Right parasternal long axis view of left ventricular outflow tract (LVOT) was used to assess hemodynamic across new valve. **RESULTS:** Velocity time integral (VTI) significantly decreased from  $18.98 \pm 2.88$  before surgery to  $12.55 \pm 2.48$  one day after surgery (D1) ( $p < 0.05$ ). Mean Velocity (Vmean) decreased significantly from  $52.56 \pm 12.01$  to  $39.72 \pm 12.30$  at D1 ( $p < 0.05$ ). But maximum velocity (Vmax) was constant during study. There was not any statistical difference between mean Pressure gradient (Pgmean) or maximum pressure gradient (Pgmax) in comparison with pre-surgery and D1, W2 and W4. At D1, W2 and W4, time to peak (TTP) differed significantly from previous time. **CONCLUSIONS:** Our results demonstrated that this tissue engineered aortic valve (TEAV) could change some hemodynamic parameters, but heart could compensate some of them. Valve movement remained normal but the major complication was aneurism which seems to be the result of poor scaffold.

### Introduction

Prosthetic valve (PV) replacement is a common procedure in patients with cardiac valve dysfunction. Valvular replacement is the most prevalent method of treating advanced cardiac valves dysfunction. Over 80 models of pros-

thetic valves have been introduced and applied since 1950 (Cebotari et al. 2002). PVs are mainly mechanical or bioprosthetic. Mechanical valves are the oldest and long-lasting prosthetic valves. Biological prostheses span a range from porcine or bovine trileaflet valves and homografts (processed human ca-

daveric valves (Tobias and Frank 2010). One of the main concerns about prosthetic valve dysfunction is their life threatening potential. Transthoracic echocardiography (TTE) is a noninvasive diagnostic method for PVs evaluation. The accuracy, noninvasive nature, broad availability, and absence of exposure to ionizing radiation have established echocardiography/Doppler as the standard for the clinical assessment of heart valve function (Bonow et al. 2006; Vahanian et al. 2012) including the assessment of hemodynamics after aortic valve replacement (Bach 2010). This enables immediate evaluation of replaced valve soon after surgery and provides critical and specific information about hemodynamic status of the valves. Color Doppler and spectral Doppler are the main echocardiographic procedures for hemodynamic assessment. Flow velocities across PVs and peak and mean gradients should be assessed by continuous wave Doppler (CWD) as in a native valve (Tobias and Frank 2010). PVs may cause obstruction, especially in patient-prosthetic mismatch which will cause functional obstruction despite its good mechanical performance (Rahimtoola 1978). Regurgitation is another complication after PVs replacement which is often difficult to assess particularly in mechanical prosthetics (Tobias and Frank 2010).

The purpose of this study was TTE evaluation of tissue engineered aortic valve (TEAV) placed in thoracic aorta of sheep model and assessment of post-operative hemodynamic values TEAV.

## **Materials and Methods**

All of the procedures were performed in Critical Care Center of Experimental Medicine Institute of University of Tehran and approved by Research Council of Veterinary Faculty.

**Animals:** This study was undertaken on 6 male sheep between 45-55 kg in weight and 2-3 years of age. All sheep were considered

normal on clinical examination.

**Echocardiography:** Echocardiography was performed 24 hours before surgery. Sheep were prepared for echocardiography by clipping the region between 3<sup>rd</sup> and 5<sup>th</sup> intercostal spaces, washing with surgical spirit and covering the clipped area with acoustic coupling gel. Echocardiography was done in standing position. For aortic valve evaluation echocardiography (Micro Maxx: SonoSite Inc, Bothell, WA, USA with a phase array transducer 1-5 MHz) was performed from right parasternal window and left ventricular outflow tract (LVOT) view was used for assessment of both native aortic valve and TEAV. To evaluate hemodynamic status, color Doppler and pulse wave Doppler were used. Gate was placed distal to the native valve and TEAV. Echocardiography was repeated using the same procedure at 24 hours, 2 and 4 weeks after surgery. Echocardiograph machine with a phase array transducer (1-5 MHz) was used. Velocity time integral (VTI), time to peak (TTP), mean and maximum velocity ( $V_{\text{mean}}$  and  $V_{\text{max}}$ ) and mean and maximum pressure gradient (PG<sub>mean</sub> and PG<sub>max</sub>) were measured and data was compared statistically at the four mentioned times.

Statistical analysis. Repeated measures analysis and paired t test with 95% Confidence Interval were done by General Linear Model (GLM) procedure of the SPSS version 16.0. Data was expressed as Mean  $\pm$  SE. A P-value of less than 0.05 was considered statistically significant.

## **Results**

VTI significantly decreased from 18.98 $\pm$ 2.88cm before surgery to 12.55 $\pm$ 2.48cm one day after surgery (D1) ( $p < 0.05$ ). Two weeks after surgery (W2) this value increased and again 4 weeks after surgery (W4) decreased none of which was statistically significant (Table1).

The mean value of  $V_{\text{max}}$  was constant

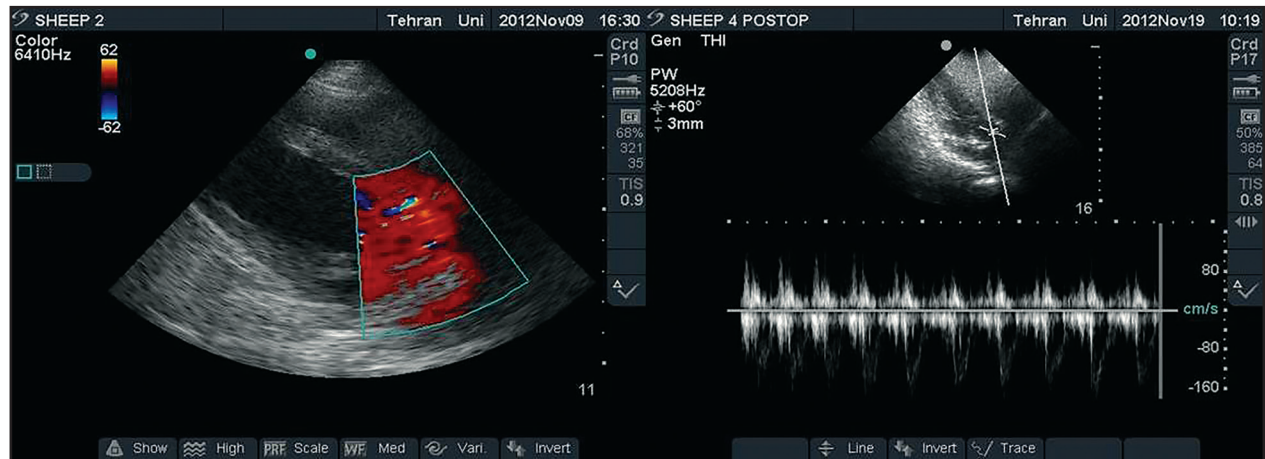


Figure 1. Collor (left) and spectral (right) Doppler of native aortic valve.

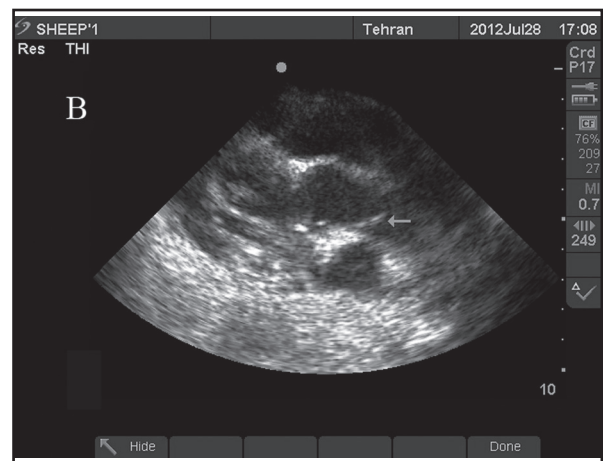
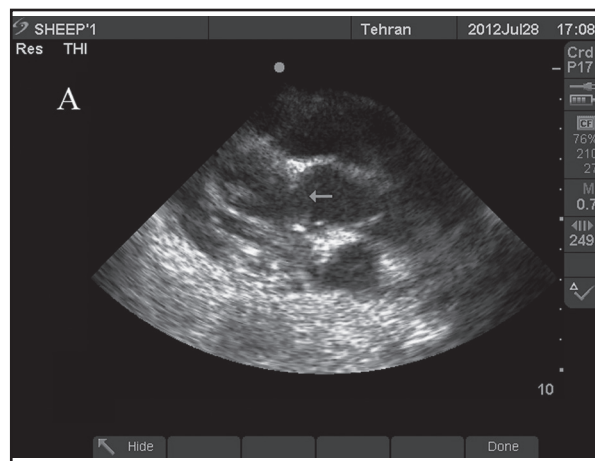


Figure 2. Tissue engineered aortic valve placed in thoracic aorta (arrow). A) Native valve B) Tissue engineered valve.

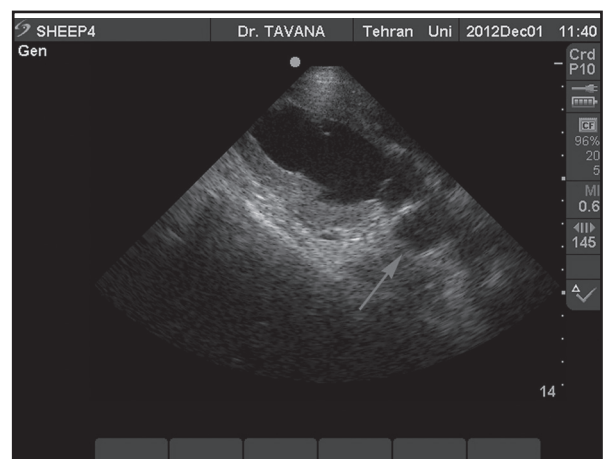
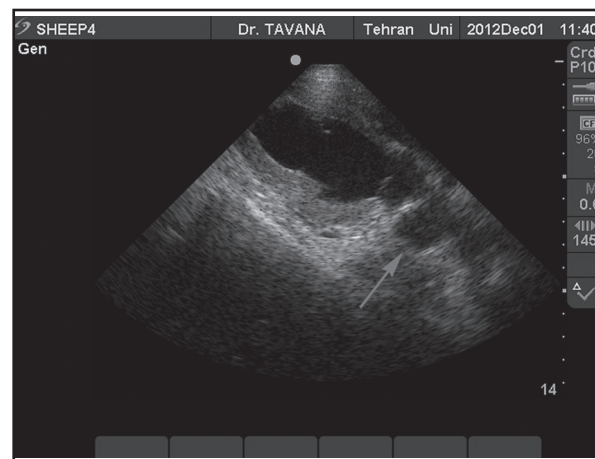


Figure 3. Aneurism 2 weeks after surgery in graft (arrow).

Figure 4. Aneurism 2 weeks after surgery in our graft which is shown on CT angiograph (arrow).

during the study and there were no significant changes at D1, W2 and W4 in comparison with previous time and pre-surgery. Vmean decreased significantly from  $52.56 \pm 12.01$  cm/s

to  $39.72 \pm 12.30$  cm/s at D1 ( $p < 0.05$ ). At W2 and W4 the Vmean value increased to  $41.26 \pm 8.78$  cm/s and  $52.26 \pm 4.40$  cm/s respectively, that was not significantly different from

Table 1-Hemodynamic parameters before surgery, one day (D1), 2 weeks (W2) and 4 weeks (W4), after surgery. Data are shown as mean  $\pm$  SE. §  $p < 0.05$  versus pre-surgery values. ‡  $p < 0.05$  versus previous time. VTI, velocity time integral; V<sub>max</sub>, maximum velocity; V<sub>mean</sub>, mean velocity; PG<sub>max</sub>, maximum pressure gradient; PG<sub>mean</sub>, mean pressure gradient; TTP, time to peak.

	Before	D1	W2	W4
VTI (cm)	18.98 $\pm$ 2.88	12.55 $\pm$ 2.48 § ‡	16.23 $\pm$ 3.60	14.50 $\pm$ 2.30
V <sub>max</sub> (cm/s)	103.56 $\pm$ 11.80	98.02 $\pm$ 14.71	94.46 $\pm$ 12.07	100.12 $\pm$ 5.58
PG <sub>max</sub> (mmHg)	4.20 $\pm$ 1.16	4.19 $\pm$ 1.40	3.96 $\pm$ 0.84	3.57 $\pm$ 0.16
V <sub>mean</sub> (cm/s)	52.56 $\pm$ 12.01	39.72 $\pm$ 12.30 § ‡	41.26 $\pm$ 8.78	52.26 $\pm$ 4.40
PG <sub>mean</sub> (mmHg)	1.19 $\pm$ 0.67	0.87 $\pm$ 0.52	0.84 $\pm$ 0.28	1.12 $\pm$ 0.17
TTP (ms)	195.40 $\pm$ 58.73	431 $\pm$ 32.57 § ‡	128 $\pm$ 28.53 ‡	138 $\pm$ 37.07 ‡

pre-surgery time and their previous time.

PG<sub>max</sub> had a decreasing trend, but there were not any statistical differences between specific times. PG<sub>mean</sub> had the same pattern as PG<sub>max</sub> but at W4 its value increased from 0.84 $\pm$ 0.28mmHg at W2 to 1.12 $\pm$ 0.17mmHg which was not significant.

At D1, W2 and W4 TTP differed significantly from previous time. The value increased from 195.40 $\pm$ 58.73ms (pre-surgery) to 431 $\pm$ 32.57ms (D1) and decreased to 128 $\pm$ 28.53ms at W2, it increased significantly again to 138 $\pm$ 37.07ms at W4. Just at D1 was the TTP value significantly higher than pre-surgery time.

Color Doppler finding was normal in our study and there was not any stenosis or regurgitation along any valves (Figure 1). Valves movement was normal and their morphology was maintained during the study (Figure 2), the only abnormal finding was aneurism in our graft; After 2 weeks 3 sheep and after 4 weeks another 2 sheep showed aneurism in acellular grafts (Figure 3). Finally CT angiography was done to evaluate the aneurism (Figure 4).

## Discussion

Previous studies focused on echocardiographic assessment of mechanical prosthetic valves (Vitarelli et al. 2004; Sadoshima et al. 1992) This study is the first one in veterinary medicine that has tried to evaluate the efficacy of TEAV placed in thoracic aorta. The aim of this case control study was evaluation of spec-

tral Doppler parameters to determine the practicality of this type of valve.

The early postoperative echocardiography is important in predicting the late outcomes (Corti et al, 2001). During the first week and months of valve replacement significant reduction of left ventricular size and myocardial function improvement appears (Gaasch et al. 1983; Fioretti et al. 1985). The general principles for evaluating the prosthetic valve function are similar to those of native valve stenosis (Parnell and Swanevelder 2009; Quiñones et al. 2002). The best parameter for assessment of AV hemodynamic is transvalvular gradient (Bach 2010). Increase in gradient across the replaced valve represents valvular stenosis and, according to Bernoulli equation, pressure gradient is in relation to velocity. So, when a constant volume of blood flows through a narrowed valve its velocity must increase, and increasing pressure gradient is expected.

Bernoulliequation:  $\Delta P = P_1 - P_2 = 4(V_2^2 - V_1^2)$

The greater the obstruction the greater the pressure difference between chamber and receiving vessel and also the greater the velocity. The peak difference between pressures is the maximum gradient, and average difference over the duration of flow is the mean gradient. Gorlin equation PG and valve area have a relationship. For constant valve orifice area, PG increases in high flow state like pain, anxiety, fever or anemia (Bach 2010) and decreases in low flow state, like dehydration. Systemic hypertension in patient with aortic stenosis may lead to decreasing left ventricle output follow-



ing reduction in transvalvular PG (Little et al. 2007; Bermejo 2005).

Gorlin equation: Aortic valve area= (cardiac output)/(systolic ejection period  $\times$  Heart rate $\times 44.3\sqrt{(\text{mean gradient})}$ )

PGmax is less reliable in comparison with PGmean because it is highly dependent on left ventricle contractility and transvalvular flow. Severe aortic stenosis in a native valve is defined as flow velocity more than 4.5 m/sec, PGmean more than 50 mmHg and PGmax more than 80mmHg. However, in newly implanted prosthetic valve Vmax, PGmean and PGmax more than 3.5 m/sec, 30mmHg and 50 mmHg respectively would be considered significant (Parnell and Swanevelter 2009).

The aortic VTI is an echocardiographic tool used to estimate cardiac output (Pees et al. 2013) and is independent of body surface area, inversely related to heart rate and not sex related (Evangelista et al. 1996). VTI is directly proportional to stroke volume (Darke 1992, Hatle 1985) and is representative of the distance a volume of blood travels through inflow or outflow tracts.

This study showed that TEAV placed in thoracic aorta at D1 caused significant reduction in VTI and Vmean and increased in TTP. PGmax and PGmean were not significantly different from pre-surgery values. There was a significant difference in TTP at W2 and W4 in comparison with their previous time but there was not a statistical difference from pre-surgery values. According to our finding, surgery VTI decreased one day after surgery as a result of new obstacle in flow path, in fact, it was an outcome of diminished velocity, so blood traveled a lesser distance in comparison to pre-surgery time. But this condition alleviates after 2 and 4 weeks, and could be a compensatory response of left ventricle by increasing contractility. PG was constant during the study, meaning that our TEAV did not cause any stenosis in aorta. TTP increased significantly one day after surgery and undoubtedly was a sub-

sequence of new obstacle in thoracic aorta that increased time span to reach the peak velocity; it decreased after 2 and 4 weeks, which could be the result of compensatory response of left ventricle by increasing contractility again.

Steinhoff used allogenic acellular valve in pulmonary artery of sheep model, the valves morphology remained normal in 5 sheep of a total 6 sheep, in echocardiography subvalvular calcification was seen in all sheep, and pulmonary regurgitation was seen only in one sheep (Steinhoff et al. 2000).

In another study valves produced from absorbable polymer were placed in 6 lambs. In echocardiography all valves were normal and there was no stenosis, thrombosis and aneurism, their movement was normal as well (Horerstrup et al. 2000).

In another research a cellular valve was used in sheep model and all echocardiographic findings were normal after 7 and 10 days and 3 months after surgery (Elkins et al. 2001).

**Conclusion:** According to the mentioned results the TEAV used in this study was functional except aneurism that appeared after two weeks, probably it was a result of weak scaffold, and we recommend using a durable scaffold in next study to obtain better results.

## Acknowledgments

We would like to show our gratitude to the Institute of biomedical research and also surgery department staff of faculty of veterinary medicine, university of Tehran, who provided insight and expertise to this research.

## References

1. Bach, D.S. (2010) Echo/Doppler evaluation of hemodynamics after aortic valve replacement: principles of interrogation and evaluation of high gradients. *JACC Cardiovasc Imaging*. 3: 296-304.
2. Bermejo, J. (2005) The effects of hypertension

- on aortic valve stenosis. *Heart*. 91: 280-282.
3. Bonow, R.O., Carabello, B.A., Chatterjee, K., de Leon, A.C., Jr, Faxon, D.P., Freed, M.D., Gaasch, W.H., Lytle, B.W., Nishimura, R.A., O'Gara, P.T., O'Rourke, R.A., Otto, C.M., Shah, P.M., Shanewise, J.S., Smith, S.C.Jr, Jacobs, A.K., Adams, C.D., Anderson, J.L., Antman, E.M., Fuster, V., Halperin, J.L., Hiratzka, L.F., Hunt, S.A., Lytle, B.W., Nishimura, R., Page, R.L., Riegel, B. (2006) ACC/AHA 2006 guidelines for the management of valvular heart disease: a report of the American College of Cardiology/American heart association task force on practice guidelines (writing committee to develop guidelines for the management of patients with valvular heart disease). *J Am Coll Cardiol*. 48: e1-e148.
  4. Cebotari, S., Mertsching, H., Kallenbach, K., Kostin, S., Repin, O., Batrinac, A., Kleczka C, Ciubotaru, A., Haverich, A. (2002) Construction of autologous human heart valves based on an acellular allograft matrix. *Circulation*. 106: I-63-I-68.
  5. Corti, R., Binggeli, C., Turina, M., Jenni, R., Lüscher, T.F., Turina, J. (2001) Predictors of long-term survival after valve replacement for chronic aortic regurgitation Is M-mode echocardiography sufficient?. *Eur Heart J*. 22: 866-873.
  6. Darke, P.G.G. (1992) Doppler echocardiography. *J Small Anim Pract*. 33: 104-112.
  7. Elkins, R.C., Dawson, P.E., Goldstein, S., Walsh, S.P., Black, K.S. (2001) Decellularized human valve allografts. *Ann Thorac Surg*. 71: S428-S432.
  8. Evangelista, A., García del Castillo, H., González-Alujas, T., Brotons, C., García-Dorado, D., Soler-Soler, J. (1996) Normal values of valvular flow velocities determined by Doppler echocardiography: relations with heart rate and age. *Rev Esp Cardiol*. 49: 189-195.
  9. Fioretti, P., Roelandt, J., Sclavo, M., Domenicucci, S., Haalebos, M., Bos, E., Hugenholtz, P.G. (1985) Postoperative regression of left ventricular dimensions in aortic insufficiency: a long-term echocardiographic study. *J Am Coll Cardiol*. 5: 856-861.
  10. Gaasch, W.H., Carroll, J.D., Levine, H.J., Criscitiello, M.G. (1983) Chronic aortic regurgitation: prognostic value of left ventricular endsystolic dimension and end-diastolic radius/thickness ratio. *J Am Coll Cardiol*. 1: 775-782.
  11. Hatle, L. (1985) Doppler ultrasound in cardiology. *Physical Principles And Clinical Applications*. (2<sup>nd</sup> ed.) Lippincott Williams and Wilkins. Philadelphia, USA.
  12. Hoerstrup, S.P., Sodian, R., Daebritz, S., Wang, J., Bacha, E.A., Martin, D.P., Moran, A.M., Guleserian, K.J., Sperling, J.S., Kaushal, S., Vacanti, J.P., Schoen, F.J., Mayer, J.E. (2000) Functional living trileaflet heart valves grown in vitro. *Circulation*. 102: III44-49.
  13. Little, S.H., Chan, K.L., Burwash, I.G. (2007) Impact of blood pressure on the doppler echocardiographic assessment of severity of aortic stenosis. *Heart*. 93: 848-855.
  14. Parnell, A., Swanevelter, J., (2009) High transvalvular pressure gradients on intraoperative transesophageal echocardiography after aortic valve replacement: what does it mean?. *HSR Proc Intensive Care Cardiovasc Anesth*, 1: 7-18.
  15. Pees, C., Glagau, E., Hauser, J., Michel-Behnke, I. (2013) Reference values of aortic flow velocity integral in 1193 healthy infants, children, and adolescents to quickly estimate cardiac stroke volume. *Pediatr Cardiol*. 34: 1194-1200.
  16. Quiñones, M.A., Otto, C.M., Stoddard, M., Waggoner, A., Zoghbi, W.A. (2002) Recommendations for quantification of doppler echocardiography: a report from the doppler quantification task force of the nomenclature and standards committee of the American Society of Echocardiography. *J Am Soc Echocardiogr*. 15: 167-184.
  17. Rahimtoola, S.H. (1978) The problem of valve prosthesis-patient mismatch. *Circulation*. 58: 20-24.
  18. Sadoshima, J., Koyanagi, S., Sugimachi, M.,

- Hirooka, Y., Takeshita, A. (1992) Evaluation of the severity of mitral regurgitation by transesophageal Doppler flow echocardiography. *Am Heart J.* 123: 1245-51.
19. Steinhoff, G., Stock, U., Karim, N., Mertsching, H., Timke, A., Meliss, R.R., Pethig, K., Haverich, A., Bader, A. (2000) Tissue engineering of pulmonary heart valves on allogenic acellular matrix conduits: in vivo restoration of valve tissue. *Circulation.* 102: III 50-III 55.
20. Tobias, P., Frank, A.F. (2010) Echocardiographic follow-up after heart valve replacement. *Heart.* 96: 75-85.
21. Vahanian, A., Alfieri, O., Andreotti, F., Antunes, M.J., Barón-Esquivias, G., Baumgartner, H., Borger, M.A., Carrel, T.P., De Bonis, M., Evangelista, A., Falk, V., Jung, B., Lancellotti, P., Pierard, L., Price, S., Schäfers, H.J., Schuler, G., Stepinska, J., Swedberg, K., Takkenberg, J., Von Oppell, U.O., Windecker, S., Zamorano, J.L., Zembala, M. (2012) Guidelines on the management of valvular heart disease (version 2012). *Eur Heart J.* 33: 2451-2496.
22. Vitarelli, A., Conde, Y., Cimino, E., Leone, T., D'Angeli, I., D'Orazio, S., Stellato, S. (2004) Assessment of severity of mechanical prosthetic mitral regurgitation by transoesophageal echocardiography. *Heart.* 90: 539-544.

## یافته‌های داپلر اکوکاردیوگرافی داپلر پس از کارگذاری دریچه آئورت مهندسی بافت شده، در آئورت پیوند شده در آئورت توراسیک مدل گوسفندی

محمد رضا مخبر دزفولی<sup>۱،۴</sup> حمید توانایی منش<sup>۱،۴\*</sup> محمد مهدی دهقان<sup>۲،۴</sup> فرزاد حیاتی<sup>۲</sup> سیروس صادقیان چالشتی<sup>۱،۴</sup> حسام‌الدین اکبرین<sup>۳</sup> پویا پورنقی<sup>۵</sup>

(۱) گروه بیماریهای داخلی، دانشکده دامپزشکی دانشگاه تهران، تهران، ایران

(۲) گروه جراحی و رادیولوژی، دانشکده دامپزشکی دانشگاه تهران، تهران، ایران

(۳) گروه بهداشت و کنترل مواد غذایی، دانشکده دامپزشکی دانشگاه تهران، تهران، ایران

(۴) پژوهشکده تحقیقات زیست پزشکی، دانشکده دامپزشکی دانشگاه تهران، تهران، ایران

(۵) گروه زیست‌شناسی، دانشگاه پیام نور، تهران، ایران

(دریافت مقاله: ۲۱ دی ماه ۱۳۹۴، پذیرش نهایی: ۲۶ اسفند ماه ۱۳۹۴)

### چکیده

**زمینه مطالعه:** بیماریهای دریچه از معمول‌ترین مشکلات قلبی هستند و پیوند دریچه گزینه اصلی درمان در موارد پیشرفته به حساب می‌آید. **هدف:** در این مطالعه از دریچه مهندسی بافت شده در آئورت توراسیک استفاده شد و کارایی آن با هدف ارزیابی خواص مکانیکی دریچه‌ها با اکوکاردیوگرافی ارزیابی شدند. **روش کار:** این مطالعه بر روی شش رأس گوسفند انجام شد. اکوکاردیوگرافی در همه گوسفندان ۲۴ ساعت قبل از جراحی پیوند دریچه، ۲۴ ساعت بعد (D1)، دو هفته بعد (W2) و چهار هفته بعد (W4) از جراحی انجام شد. از نمای طولی بطن چپ در سمت راست بدن برای ارزیابی وضعیت همودینامیک در طول دریچه آئورت استفاده شد. نتایج: انتگرال زمان سرعت (VTI) از  $18/98 \pm 2/88$  پیش از جراحی به  $12/55 \pm 2/48$  یک روز پس از جراحی رسید که تفاوت معنی‌داری را نشان داد. سرعت میانگین هم در روز اول کاهش معنی‌داری نسبت به پیش از جراحی نشان داد. ولی حداکثر سرعت در طول مطالعه ثابت باقی ماند. در هیچ زمانی گرادیان فشار تفاوت معنی‌داری را نشان نداد. **نتیجه‌گیری نهایی:** نتایج مطالعه حاضر نشان داد که دریچه مهندسی شده در این مطالعه بعضی از فاکتورهای همودینامیک خون را تغییر داد ولی حرکت دریچه طبیعی بود و عارضه معمول پس از استفاده از این دریچه آنوریسم بود که علت آن اسکافولد ضعیف دریچه بود.

**واژه‌های کلیدی:** اکوکاردیوگرافی، قلب، همودینامیک، مهندسی بافت، دریچه

\* نویسنده مسؤول: تلفن: +۹۸(۲۱) ۶۶۴۳۱۱۰۳ شماره: +۹۸(۲۱) ۶۶۹۳۳۲۲۲ Email: hamidtavana@ut.ac.ir