



## Protective Effect of Camel Milk on Gentamicin-induced Nephrotoxicity: From Renal Biomarkers to Histopathology Evidence

Fereshteh Arab<sup>1</sup>, Saeideh Naeimi<sup>\*2</sup>, Abbas Javaheri-Vayeghan<sup>3</sup>, Ahad Muhammadnejad<sup>4</sup>, Mahmood Ahmadi-hamedani<sup>5</sup>

<sup>1</sup> DVM Student, Faculty of Veterinary Medicine, Semnan University, Semnan, Iran

<sup>2</sup> Department of Basic Sciences, Faculty of Veterinary Medicine, Semnan University, Semnan, Iran

<sup>3</sup> Department of Pathobiology, Faculty of Veterinary Medicine, Semnan University, Semnan, Iran

<sup>4</sup> Cancer Biology Research Center, Cancer Institute of Iran, Tehran University of Medical Sciences, Tehran, Iran

<sup>5</sup> Department of Clinical Sciences, Faculty of Veterinary Medicine, Semnan University, Semnan, Iran

### Abstract

**BACKGROUND:** Gentamicin is an effective antibiotic with some important side effects, such as nephrotoxicity. There is evidence of renoprotective effects and antioxidant properties for camel milk.

**OBJECTIVES:** In this study, the impact of camel milk on the nephrotoxicity induced by gentamicin was evaluated.

**METHODS:** The present study was performed on four groups of six Wistar rats. Group 1 (C), as the control group, received exclusively normal saline injections and the rats in group 2 (GM) received intraperitoneal gentamicin injections at the dose of 100 mg/kg for the last ten days. The animals in group 3 (CM) were fed by 5 mL/rat/day of camel milk through gavage for 15 days. Group 4 (MGM) was fed camel milk only for the first five days followed by gentamicin injections for 10 days. Serum urea, creatinine, and superoxide dismutase (SOD) were measured and kidneys were studied histopathologically.

**RESULTS:** Increased concentrations of urea and creatinine along with the decreased level of SOD were found in the GM group. Histopathologic changes, such as eosinophilic casts in the tubular lumen, capillary congestion, glomerulonephritis, necrosis, interstitial nephritis, and edema were more common in the GM group, in comparison with the C, CM, and MGM groups ( $P < 0.05$ ). The elevations in serum urea and creatinine ( $P < 0.05$ ) were significantly prevented by the co-administration of camel milk and gentamicin. Moreover, a significant increase in the serum activity of SOD was revealed in the GM group ( $P < 0.05$ ). Camel milk significantly prevented tissue injury, in comparison with the GM group ( $P < 0.05$ ).

**CONCLUSIONS:** Our results demonstrated that gentamicin-induced histological and biochemical alterations in the kidney decreased significantly due to camel milk consumption.

**KEYWORDS:** Camel milk, Gentamicin, Nephrotoxicity, Oxidative Stress, Rat

### Correspondence

Saeideh Naeimi, Department of Basic Sciences, Faculty of Veterinary Medicine, Semnan University, Semnan, Iran  
Tel: +98 (023) 31532619, Fax: +98 (023) 2331532626, Email: [naeimis@semnan.ac.ir](mailto:naeimis@semnan.ac.ir)

Received: 2020-08-23

Accepted: 2020-10-26

Copyright © 2021. This is an open-access article distributed under the terms of the Creative Commons Attribution- 4.0 International License which permits Share, copy and redistribution of the material in any medium or format or adapt, remix, transform, and build upon the material for any purpose, even commercially.

### How to Cite This Article

Arab, F., Naeimi, S., Javaheri Vayeghan, A., Muhammadnejad, A., Ahmadi hamedani, M., A. (2021). Protective Effect of Camel Milk on Gentamicin-induced Nephrotoxicity: From Renal Biomarkers to Histopathology Evidence. *Iranian Journal of Veterinary Medicine*, 15(1), 79-92.

## Introduction

Gentamicin is an aminoglycoside antibiotic, which is used for some infections all around the world. Several significant side effects have been reported for the long-term usage of this antibiotic, two important of which are nephrotoxicity and ototoxicity. However, this medication is still effective against many gram-negative and gram-positive bacteria (Avent *et al.*, 2011). The prevalence of kidney failure has been estimated as about 30% among patients who received gentamicin (Adil *et al.*, 2016; Poulidakos and Falagas, 2013). Gentamicin induced nephrotoxicity following accumulation in the epithelial cells of renal tubules (Edwards *et al.*, 2020; Oztopuz *et al.*, 2019; Fujiwara *et al.*, 2009). Gentamicin caused apoptosis and necrosis in different *in vitro* and *in vivo* studies (Lopez-Novoa *et al.*, 2011). The nephrotoxicity induced by gentamicin is a complex situation involving diverse pathways, such as reduced renal blood flow, oxidative stress, inflammation, nitric oxide generation, lipid peroxidation, nuclear factor kappa B pathway, apoptosis, and the decreased efficiency of kidney antioxidant enzymes, including SOD, catalase, glutathione peroxidase, and reduced glutathione (GSH) (Ulu *et al.*, 2018; Amaral *et al.*, 2018). Therefore, it is necessary to find therapeutic substances for limiting this damage. There are some strategies, such as antibiotic time control, diet changing, and prescription of some other medicines (Balakumar *et al.*, 2010). As mentioned above, oxidative stress is one of the main reasons for renal damage. Antioxidant agents play an important role in preventing oxidative damage by neutralizing the effect of reactive oxygen metabolites on cellular components. Little attention has been paid to natural substances with antioxidant properties for protecting against nephrotoxic damage induced by gentamicin (Quiroset *et al.*, 2016; Boroushaki *et al.*, 2012) and eligible impacts of these substances have attenuated the damages caused by

gentamicin (Tavafi, 2013; Ali *et al.*, 2011; Ali, 2003).

Camel milk has some renoprotective (Althanaian *et al.*, 2013), hepatoprotective (Darwish *et al.*, 2012), and anticancer (Habib *et al.*, 2013) influences and is utilized for the treatment of some special diseases, namely autism (Al-Ayadhi and Elamin, 2013), diabetes (Mirmiran *et al.*, 2017; Khan *et al.*, 2013), and cow milk allergy (Maryniak *et al.*, 2018; Ehlayel *et al.*, 2011; El-Agamy *et al.*, 2009). Moreover, camel milk is traditionally applied for treating tuberculosis, hypertension, gastroenteritis, B hepatitis, and some autoimmune diseases (Kumar *et al.*, 2016<sup>a</sup>; Al-Ayadhi and Elamin, 2013) in Africa and the Middle East. Camel milk contains various protective proteins, water, and fat-soluble vitamins (Ismaili *et al.*, 2019; Khalesi *et al.*, 2017; Al-Ayadhi and Elamin, 2013; El-Hatmi *et al.*, 2007). The amount of vitamin C, as an essential antioxidant vitamin, is much higher in camel milk than cow milk (Legesse *et al.*, 2017; Yadav *et al.*, 2015). Therefore, it seems that camel milk can reduce the side effects of gentamicin.

In the present study, the objectives were to evaluate the effect of camel milk consumption on gentamicin-induced biochemical changes in laboratory rats by assessing serum urea creatinine, and SOD, as well as renal tissue alterations.

## Materials and Methods

### Medication and Camel Milk

Gentamicin vial of 2 mL containing 40mg/mL (Alborz Darou Pharmaceutical Company, Iran) was used. Camel milk was obtained manually every day from *Camelus dromedary*, Semnan province, Iran. Milk samples were collected in a sterile tube and transferred to the laboratory in cold flasks.

### Animals

A total of 24 Wistar rats (250-300 gr) were randomly selected from the Research Center of Veterinary Faculty, Semnan University. The

subjects were kept in the humidity of 60%-65%, temperature of 25°C, and 12 hour light/dark cycle ten days prior to the experiment. The rats were fed with a laboratory diet and had free access to freshwater. Animals were divided into four groups with six rats in each. The experiment was performed within 15 days.

The rats in group 1(C), as the control group, received intraperitoneal (IP) injections of 0.2 mL normal saline for 15 days. Group 2 (GM) was injected IP with 100mg/kg gentamicin on the last ten days of the experiment. The subjects in group 3(CM) received camel milk at the dose of 5 mL/rat/day orally for fifteen days. Group 4 (MGM) received 5 mL/rat/day of camel milk orally on the first 5 days of the experiment followed by IP injection of 100 mg/kg gentamicin for ten days.

#### **Ethical Approval**

The research was reviewed and approved by the Ethics in Research Committee of Semnan University, Iran with the ethics code of E19-95-01-30. The research was conducted following the World Medical Association Declaration of Helsinki.

#### **Collecting Blood Serum**

At the end of the experiment, rats were euthanized by deep anesthesia. A volume of 4 mL of blood samples was collected by cardiac puncture and the sera were separated and stored at -20°C until analysis.

#### **Biochemical Analysis**

Serum urea and creatinine were measured using commercial kits (Pars Azmun Co., Tehran, Iran), according to the instructions of the manufacturer. The SOD kit (ZellBio Co., CAT No. ZB-SOD-96A) converts superoxide anion to hydrogen peroxide and oxygen through enzymatic reactions. Finally, the product makes a

color, which is measured colorimetrically at 420 nm. The SOD is known as one of the most effective antioxidant enzymes in the body.

#### **Histopathologic Examination**

The right kidney was removed and fixed in 10% formalin. The tissues were processed and stained by hematoxylin and eosin to observe the tubular, glomerular, vascular, and interstitial alterations. These changes were classified as zero (absence of alteration), 1 (mild alteration), 2 (moderate alteration), and 3 (severe alteration).

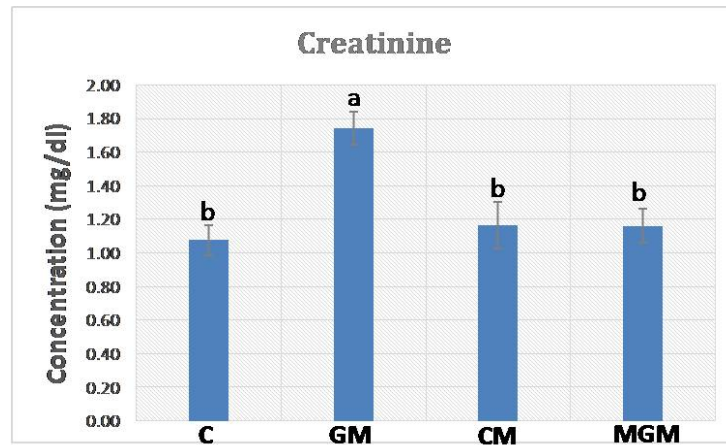
#### **Statistical Analysis**

Descriptive statistics were presented using the SPSS software version 15 (SPSS Inc., Chicago, Ill., USA). Two-way repeated measures analysis of variance (ANOVA) was used to evaluate significant changes in the groups. Bonferroni post-hoc test was applied as a correction for multiple comparisons. Histopathologic non-parametric data were analyzed by the Kruskal-Wallis test and the significant differences between the two groups were compared by the Mann-Whitney test. P-value < 0.05 was considered significant. The data are presented as mean ± SD.

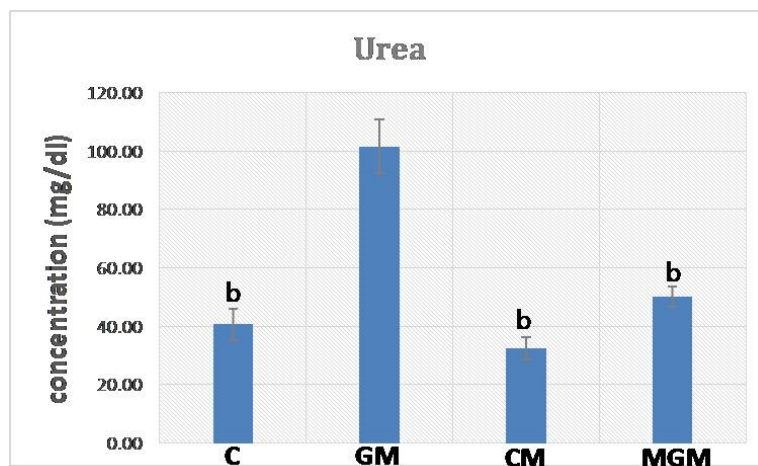
## **Results**

#### **Blood Biochemical Factors**

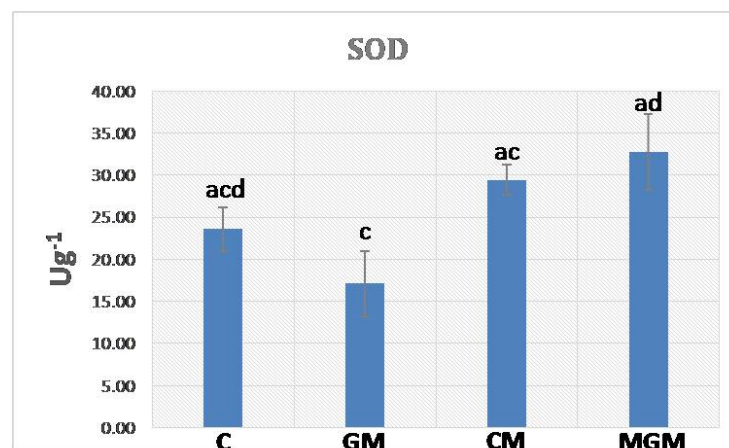
Serum creatinine and urea in the GM group were significantly higher than the C and CM groups ( $P < 0.05$ ) (Figures 1 and 2). There was a significant decrease in the urea and creatinine of the MGM group, in comparison with the GM group ( $P < 0.05$ ). The activity of SOD, as an antioxidant enzyme, diminished in the GM group. However, camel milk could increase the activity of this enzyme in the MGM group, compared to the GM group ( $P < 0.05$ ) (Figure 3).



**Figure 1.** Effect of camel's milk on gentamicin -induced renal dysfunction as measured by serum creatiniin. Data are expressed as means  $\pm$  SD for all groups. (n = 6). There are significant different between (a) and (b). C indicate control, GM indicate gentamicin alone, CM indicate camel's milk alone and MGM indicate gentamicin and camel's milk.



**Figure 2.** Effect of camel's milk on gentamicin -induced renal dysfunction as measured by serum urea. Data are expressed as means  $\pm$  SD for all groups. (n = 6). There are significant different between (a) and (b). C indicate control, GM indicate gentamicin alone, CM indicate camel's milk alone and MGM indicate gentamicin and camel's milk.

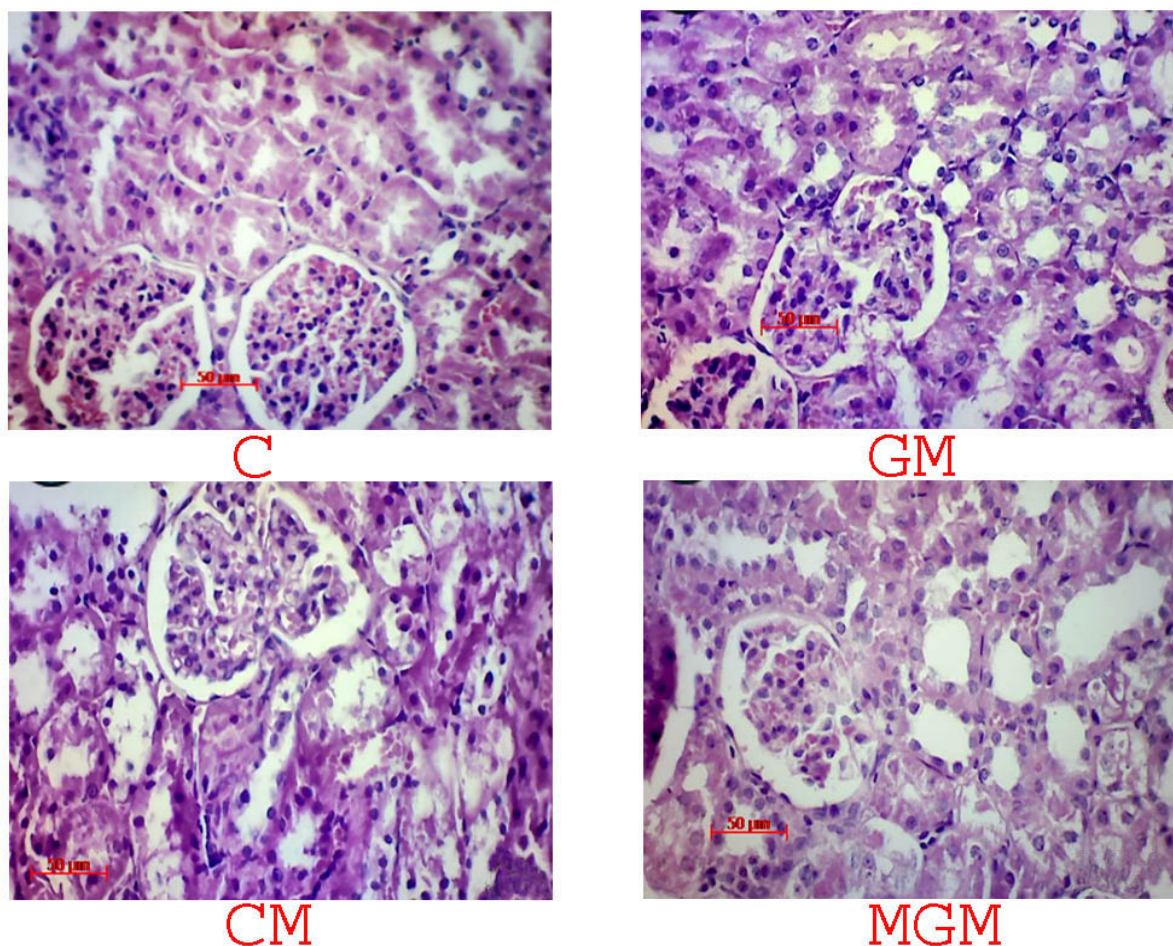


**Figure 3.** Effect of camel's milk on gentamicin -induced oxidative steres as measured by SOD. Data are expressed as means  $\pm$  SD for all groups. n = 6. There are significant different between (c) and (ad). C indicate control, GM indicate gentamicin alone, CM indicate camel's milk alone and MGM indicate gentamicin and camel's milk.

### Histopathology

Histopathological study revealed that gentamicin administration caused a marked injury in the renal tissue of the GM group. Moreover, the co-administration of camel milk and gentamicin in the MGM group led to reduced alterations (Figure 4 and Table 1). The rate of cellular degenerative changes, such as vacuolization and swelling in the GM group were significantly higher than the C and CM groups ( $P<0.05$ ). There were no significant differences in terms of degenerative alterations between the GM and MGM groups ( $P<0.05$ ). Significantly

elevated eosinophilic casts in the tubular lumen, capillary congestion, glomerulonephritis, and necrosis were observed in the GM and MGM groups, in comparison with the C and CM groups ( $P<0.05$ ). On the other hand, the rate of these histopathologic signs significantly diminished in the MGM group, compared to the GM group ( $P<0.05$ ). Furthermore, the occurrence of interstitial nephritis and edema significantly augmented in the GM group, in comparison with the C and CM groups ( $P<0.05$ ). The latter injuries were significantly inhibited in the MGM group, compared to the GM group ( $P<0.05$ ).



**Figure 4.** Effect of CM on GM-induced histopathological alteration. C indicate control, GM indicate gentamicin alone, CM indicate camel's milk alone and MGM indicate gentamicin and camel's milk. (H&E, 400x)

**Table 1.** Effects of camel milk administration on renal histopathological alterations induced by gentamicin

Groups	Degenerative alterations	Eosino-philic casts	Capillary congestion	Edema	Glomerulo-nephritis	Intersti-tial-nephritis	Necrosis
C	17.00 <sup>c</sup>	22.00 <sup>c</sup>	23.29 <sup>b</sup>	29.34 <sup>b</sup>	29.00 <sup>b</sup>	25.00 <sup>c</sup>	19.50 <sup>c</sup>
GM	52.83 <sup>ab</sup>	61.97 <sup>a</sup>	60.90 <sup>a</sup>	55.58 <sup>a</sup>	60.10 <sup>a</sup>	65.30 <sup>a</sup>	62.19 <sup>a</sup>
CM	22.25 <sup>c</sup>	23.64 <sup>c</sup>	27.60 <sup>c</sup>	29.15 <sup>b</sup>	30.58 <sup>b</sup>	26.70 <sup>c</sup>	19.50 <sup>c</sup>
MGM	53.92 <sup>b</sup>	38.39 <sup>b</sup>	43.92 <sup>b</sup>	41.72 <sup>b</sup>	35.17 <sup>b</sup>	38.22 <sup>b</sup>	44.81 <sup>b</sup>

Data are expressed as mean rank for all groups. Disparate characters indicate significant difference between groups ( $P < 0.05$ ). C indicate control, GM indicate gentamicin alone, CM indicate camel's milk alone and MGM indicate gentamicin and camel's milk.

## Discussion

According to the results of the present study, gentamicin administration at the dose of 100 mg/kg for 10 days caused some important renal tissue alterations, such as tubular necrosis, hyaline cast, edema, congestion, glomerulonephritis, and interstitial nephritis. Although various researches have been conducted on renal injury caused by gentamicin (Martínez-Salgado *et al.*, 2007), the exact mechanism of gentamicin-induced toxicity is not well known. However, it seems that the selective accumulation of this medication in renal cells causes stress, which is the main factor in apoptosis and necrosis (Randjelovic *et al.*, 2017; Quiros *et al.*, 2011; Denamur *et al.*, 2011). In this condition, the levels of reactive oxygen species (ROS) are higher than antioxidant enzymes (i.e., superoxide dismutase and glutathione peroxidase). As a result, biological cell processes are affected (Askari *et al.*, 2019; Truong *et al.*, 2017; Walker and Shah, 1988; Zorov, 2010) and biological molecules, such as proteins, lipids, and nucleic acids are destroyed (Balakumar *et al.*, 2010).

As mentioned, SOD is considered as one of the important defensive barriers against ROS (Priyamvada *et al.*, 2008). Moreover, ROS scavengers have been proved to be beneficial at reducing the development of renal damage induced by endotoxins and gentamicin. Specifically, the administration of antioxidants, including SOD or dimethylthiourea prevented

the reduction in glomerular filtration rate (GFR) induced by gentamicin. Treatment with SOD in gentamicin-treated rats is associated with an elevation in renal blood flow. Therefore, superoxide anion ( $O_2^-$ ) is proposed to be involved in gentamicin-induced renal vasoconstriction (Manshare *et al.*, 2018). Enhanced production of ROS has been consistently demonstrated to play role in the development of gentamicin-induced acute renal failure (Martínez-Salgado, 2007). Gentamicin causes an increase in  $O_2^-$  production and SOD activity. In addition, gentamicin-induced mesangial cell contraction and proliferation are inhibited by the intracellular ROS scavengers, namely SOD and catalase (Martínez-Salgado *et al.*, 2002) and by the antioxidant flavonoid trans-resveratrol (Manshare *et al.*, 2018; Morales *et al.*, 2005). Incubation with SOD and catalase, as a ROS scavenger system, can inhibited gentamicin-induced apoptosis (Martínez-Salgado *et al.*, 2004). The level of SOD activity in this research, similar to other recent studies (Manshare *et al.*, 2018; Hussain *et al.*, 2012; Yaman and Balikci, 2010) significantly decreased due to gentamicin administration in the GM group.

Along with injury progression, GFR declined because of mesenchymal cell construction, tubular obstruction, as well as the activation of the renin-angiotensin system and

vasoconstrictive factors (Stojiljkovic *et al.*, 2008). Acute renal failure occurred following the reduction in GFR (Abdelrahman, 2018; Hasanvand *et al.*, 2018; Guo and Nzerue, 2002; Cuzzocrea *et al.*, 2002). Therefore, serum urea and creatinine as renal function indicators raised after gentamicin administration in the GM groups, which is in line with the reports of other studies (Sun *et al.*, 2018; Raju *et al.*, 2011; Khan *et al.*, 2009; Karahan *et al.*, 2005).

These findings were confirmed based on the evidence in tissue sections from rats treated with gentamicin. Renal histopathological studies of the GM group indicated that the main kidney injury was tubular necrosis in proximal convoluted tubules, which is the first part of drug uptake and active transportation. Consequently, the medication accumulates in the cell organelles and destroys the phospholipid membrane that leads to apoptosis and necrosis (Alarifi *et al.*, 2012; Stojiljkovic *et al.*, 2008; Morin *et al.*, 1980).

In the current study, the infiltration of inflammatory cells in the glomerulus and interstitial tissue and hyperemia in renal histopathology was similar to previous investigations (Yarijani *et al.*, 2016). Inflammatory reactions start with oxidative stress and cell death expanding the damage (Lee *et al.*, 2013). In gentamicin nephrotoxicity, chemical mediators increase and the migration of neutrophils and lymphocytes causes interstitial nephritis and glomerulonephritis (Lopez-Novoa *et al.*, 2011; Balakumar *et al.*, 2010; Bledsoe *et al.*, 2006). Hyaline casts in convoluted tubules, interstitial edema, in addition to vacuolization and swelling of collecting tubules and tubular epithelial cells were observed. The mentioned changes may occur as the result of cell membrane disturbances following gentamicin administration (Alarifi *et al.*, 2012; Stojiljkovic *et al.*, 2008).

Our findings revealed that camel milk could significantly decrease the toxic effects of gentamicin. The SOD was augmented in the MGM

group, which was similar to the other researches that used camel milk as an antioxidant (Al-Asmari *et al.*, 2014). Furthermore, it has been proved that compounds with antioxidant properties have the potential for reducing gentamicin-induced nephrotoxicity through enhancing renal endogenous antioxidant activity (Al-kuraishy *et al.*, 2019). Kadkhodae *et al.* (2007) showed that gentamicin caused significant nephrotoxicity as demonstrated by diminished SOD activity, compared to controls. These authors indicated that the combination of vitamins C and E significantly preserved enzyme activities and could prevent a reduction in SOD activity. Among the antioxidants, SOD is the first and most important line of defense against ROS and antioxidant vitamins play role in the preservation of renal endogenous antioxidants, namely SOD, in gentamicin-induced nephrotoxicity (Kadkhodae *et al.*, 2007). Serum urea and creatinine were close to the normal levels and several researchers demonstrated that serum urea and creatinine levels elevated due to gentamicin-induced nephrotoxicity and reduced by antioxidant compounds (Shamim *et al.*, 2018; Ghaznaviet *et al.*, 2017; Al-Majed *et al.*, 2002; Vijay Kumar *et al.*, 2000;). Furthermore, renal histopathological alterations, such as necrosis and inflammation, were improved by camel milk. Similar results were reported in other researches that applied antioxidant compounds (Hafez *et al.*, 2019; Srivastava *et al.*, 2018; Aiswarya *et al.*, 2018; Stojiljkovic *et al.*, 2012; Parlakpinar *et al.*, 2005; Maldonado *et al.*, 2003). Camel milk contains vitamins A, B, C, and E that have antioxidant activities (Maryniak *et al.*, 2018; Ehlayel *et al.*, 2011; El-Agamy *et al.*, 2009). The level of ascorbic acid in camel milk has been reported to be higher than cow milk and can act as a protective factor that repairs renal structure and function by restoring the antioxidant capacity of tissues. Moreover, it has been shown to effectively prevent the destruction of cellular enzymatic defenses and weakness

caused by gentamicin-induced oxidative stress (Stojiljkovic *et al.*, 2012). In addition, the casein of camel milk is lysed rapidly and has diverse free radical scavenging peptides that can inhibit the activity of free radicals (Kumar *et al.*, 2016<sup>b</sup>; Kumar *et al.*, 2016<sup>c</sup>;Jrad *et al.*, 2014<sup>a</sup>; Jrad *et al.*, 2014<sup>b</sup>; Salami *et al.*, 2011; Salami *et al.*, 2008). Our results are consistent with other similar studies in the world (Rodrigues *et al.*, 2014; Moreira *et al.*, 2014).

## Conclusion

According to the findings of the present investigation, camel milk can reduce the side effects of gentamicin. Information concerning camel milk antioxidant effects and its exact mechanism is relatively low. Further researches with particular parameters are

necessary to understand the ingredients and influences of camel milk.

## Acknowledgments

We would like to thank Dr. Samad Muhammadnejad for his excellent technical assistance throughout this study and also for comments that greatly improved the manuscript.

## Conflict of Interest

The authors declared no conflict of interest.

## References

- Abdelrahman, R. S. (2018). Protective effect of apocynin against gentamicin-induced nephrotoxicity in rats. *Hum Exp Toxicol.* 37(1), 27-37. [DOI:10.1177/0960327116689716] [PMID]
- Adil, M., Kandhare, A. D., Dalvi, G., Ghosh, P., Venkata, S., Raygude, K. S., & Bodhankar, S. L. (2016). Ameliorative effect of berberine against gentamicin-induced nephrotoxicity in rats via attenuation of oxidative stress, inflammation, apoptosis and mitochondrial dysfunction. *Ren Fail.* 6049, 1–11.
- Aiswarya, N., Chandran, V., Teerthanath, S., & Rakesh, K. B. (2018). Nephroprotective effect of aqueous extract of *Pimpinella anisum* in gentamicin induced nephrotoxicity in wistar rats. *Pharmacogn J.* 10(3). [DOI:10.5530/pj.2018.3.66]
- Al-Asmari, A. K., Abbasmanthiri, R., Al-Elewi, A. M., Al-Omani, S., Al-Asmary, S., & Al-Asmari, S. A. (2014). Camel milk beneficial effects on treating gentamicin induced alterations in rats. *J Toxicol.* 1-7. [DOI:10.1155/2014/917608] [PMID] [PMCID]
- Al-Ayadhi, L.Y., Elamin, N.E. (2013). Camel milk as a potential therapy as an antioxidant in autism spectrum disorder (ASD). *Evid Based Complement Alternat Med.* 1-8. [DOI:10.1155/2013/602834] [PMID] [PMCID]
- Al-Majed, A.A., Mostafa, A.M., Al-Rikabi, A.C., Al-Shabanah, O.A. (2002). Protective effects of oral arabic gum administration on gentamicin-induced nephrotoxicity in rats. *Pharmacol Res.* 46(5), 445–451. [DOI:10.1016/S1043661802001251] [PMID]
- Al-Kuraishy, H. M., Al-Gareeb, A. I., & Rasheed, H. A. (2019). Antioxidant and anti-inflammatory effects of curcumin contribute into attenuation of acute gentamicin-induced nephrotoxicity in rats. *Asian J Pharm Clin Res.* 12(3), 466-468. [DOI:10.22159/ajpcr.2019.v12i3.30875]
- Alarifi, S., Al-Doaiss, A., Alkahtani, S., Al-Farraj, S.A., Al-Eissa, M.S., Al-Dahmash, B., Al-yahya, H., Mubarak, M. (2012). Blood chemical changes and renal histological alterations induced by gentamicin in rats. *Saudi J Biol Sci.* 19 (1), 103–110. [DOI:10.1016/j.sjbs.2011.11.002] [PMID] [PMCID]



- Ali, B.H. (2003). Agents ameliorating or augmenting experimental gentamicin nephrotoxicity: Some recent research. *Food Chem Toxicol.* 41(11), 1447–1452. [DOI:10.1016/S0278-6915(03)00186-8]
- Ali, B. H., Al Za'abi, M., Blunden, G., & Nemmar, A. (2011). Experimental gentamicin nephrotoxicity and agents that modify it: a mini-review of recent research. *Basic Clin Pharmacol Toxicol.* 109 (4), 225–232. [DOI:10.1111/j.1742-7843.2011.00728.x] [PMID]
- Ali, B.H. (1995). Gentamicin nephrotoxicity in humans and animals: Some recent research. *Gen Pharmacol.* 26 (7), 1477–1487. [DOI:10.1016/0306-3623(95)00049-6]
- Althnaian, T., Albokhadaim, I., & El-Bahr, S. M. (2013). Biochemical and histopathological study in rats intoxicated with carbontetrachloride and treated with camel milk. *Springer Plus.* 2(1), 57. [DOI:10.1186/2193-1801-2-57] [PMID] [PMCID]
- Amaral, L. S. D. B., Souza, C. S., Volpini, R. A., Shimizu, M. H. M., de Bragança, A. C., Canale, D., ... & Soares, T. D. J. (2018). Previous exercise training reduces markers of renal oxidative stress and inflammation in streptozotocin-induced diabetic female rats. *J Diabetes Res.* [DOI:10.1155/2018/6170352] [PMID] [PMCID]
- Askari, H., Zeinali, F., Haghi-Aminjan, H., Hafizi, S. M., & Alirezaei, A. (2019). The protective effects of *Ocimum basilicum* extract against gentamicin-induced nephrotoxicity in male rats; an anti-inflammatory, anti-oxidative and anti-apoptotic action. *Immunopathologia Persa,* 5(2), e21-e21. [DOI:10.15171/ipp.2019.21]
- Avent, M. L., Rogers, B. A., Cheng, A. C., & Paterson, D. L. (2011). Current use of aminoglycosides: indications, pharmacokinetics and monitoring for toxicity. *Int Med J,* 41(6), 441–449. [DOI:10.1111/j.1445-5994.2011.02452.x] [PMID]
- Balakumar, P., Rohilla, A., & Thangathirupathi, A. (2010). Gentamicin-induced nephrotoxicity: do we have a promising therapeutic approach to blunt it? *Pharmacol Res,* 62(3),179–186. [DOI:10.1016/j.phrs.2010.04.004] [PMID]
- Bledsoe, G., Crickman, S., Mao, J., Xia, C. F., Murakami, H., Chao, L., & Chao, J. (2006). Kallikrein/kinin protects against gentamicin-induced nephrotoxicity by inhibition of inflammation and apoptosis. *Nephrol Dial Transplant.* 21 (3), 624–633. [DOI:10.1093/ndt/gfi225] [PMID]
- Borouhaki, M.T., Asadpour, E., Sadeghnia, H.R, Dolati, K. (2012). Effect of pomegranate seed oil against gentamicin-induced nephrotoxicity in rat. *J Food Sci Technol.* 51 (11), 3510–3514. [DOI:10.1007/s13197-012-0881-y] [PMID] [PMCID]
- Cuzzocrea, S., Mazzon, E., Dugo, L., Serraino, I., Di Paola, R., Britti, D., ... & Salvemini, D. (2002). A role for superoxide in gentamicin-mediated nephropathy in rats. *Eur J Pharmacol,* 450(1), 67-76. [DOI:10.1016/S0014-2999(02)01749-1]
- Darwish, H.A., Abd Raboh, N.R., Mahdy, A. (2012). Camel's milk alleviates alcohol-induced liver injury in rats. *Food Chem Toxicol.* 50(5), 1377–1383. [DOI:10.1016/j.fct.2012.01.016] [PMID]
- Denamur, S., Tyteca, D., Marchand-Brynaert, J., Van Bambeke, F., Tulkens, P.M., Courtoy, P.J., Mingeot-Leclercq, M.P. (2011). Role of oxidative stress in lysosomal membrane permeabilization and apoptosis induced by gentamicin, an aminoglycoside antibiotic. *Free Radic Biol Med.* 51(9),1656–1665. [DOI:10.1016/j.freeradbiomed.2011.07.015] [PMID]
- Edwards, J., Kowal, M., VanDreel, A., Lamar, P., & Prozialeck, W. (2020). A Method for the Evaluation of Site-Specific Nephrotoxic Injury in the Intact Rat Kidney. *Toxics,* 8(1), 4. [DOI:10.3390/toxics8010004] [PMID] [PMCID]
- Ehlayel, M., Bener, A., Abu Hazeima, K., & Al-Mesaifri, F. (2011). Camel milk is a safer choice than goat milk for feeding children with cow milk allergy. *International Scholarly Research Notices,* 2011. [DOI:10.5402/2011/391641] [PMID] [PMCID]
- El-Agamy, E.I., Nawar, M., Shamsia, S.M., Awad, S., Haenlein, G.F.W. (2009). Are camel milk proteins convenient to the nutrition of cow milk allergic children? *Small Rumin Res.* 82(1), 1–6. [DOI:10.1016/j.smallrumres.2008.12.016]

- El-Hatmi, H., Girardet, J.M., Gaillard, J.L., Yahyaoui, M.H., Attia, H. (2007). Characterisation of whey proteins of camel (*Camelus dromedarius*) milk and colostrum. *Small Rumin Res.* 70(2–3), 267–271. [DOI:10.1016/j.small-rumres.2006.04.001]
- Fujiwara, K., Shin, M., Matsunaga, H., Saita, T., Larsson, L.I. (2009). Light-microscopic immunocytochemistry for gentamicin and its use for studying uptake of the drug in kidney. *Anti-microb Agents Chemother.* 53, 3302–3307. [DOI:10.1128/AAC.01627-08] [PMID] [PMCID]
- Ghaznavi, H., Fatemi, I., Kalantari, H., Hosseini Tabatabaei, S. M. T., Mehrabani, M., Gholamine, B., Goudarzi, M. (2018). Ameliorative effects of gallic acid on gentamicin-induced nephrotoxicity in rats. *J Asian Nat Prod Res.* 20(12), 1182–1193. [DOI:10.1080/10286020.2017.1384819] [PMID]
- Guo, X., Nzerue, C. (2002). How to prevent, recognize, and treat drug-induced nephrotoxicity. *Cleaveland Clin J Med.* 69(4), 289–312. [DOI:10.3949/ccjm.69.4.289] [PMID]
- Habib, H.M., Ibrahim, W.H., Schneider-Stock, R., Hassan, H.M. (2013). Camel milk lactoferrin reduces the proliferation of colorectal cancer cells and exerts antioxidant and DNA damage inhibitory activities. *Food Chem.* 141(1), 148–152. [DOI:10.1016/j.foodchem.2013.03.039] [PMID]
- Hafez, L. O., Ali, F. A., El-Ghoneimy, A. A., & Abdel-Aziz, M. I. (2019). Nephro-Protective effect of wheat germ oil on gentamicin-induced acute nephrotoxicity in wistar albino rat. *SVU-International Journal of Veterinary Sciences,* 2(1), 51–67. [DOI:10.21608/svu.2019.23582]
- Hasanvand, A., Kharazmkia, A., Mir, S., Khorramabadi, R. M., & Darabi, S. (2018). Ameliorative effect of ferulic acid on gentamicin-induced nephrotoxicity in a rat model; role of antioxidant effects. *J Ren Inj Prev.* 7(2), 37–77. [DOI:10.15171/jrip.2018.18]
- Hussain, T., Gupta, R.K., Sweetey, K., Eswaran, B., Vijayakumar, M., Rao, C.V. (2012). Nephroprotective activity of *Solanum xanthocarpum* fruit extract against gentamicin-induced nephrotoxicity and renal dysfunction in experimental rodents. *Asian Pac J Trop Med.* 5 (9), 686–691. [DOI:10.1016/S1995-7645(12)60107-2]
- Ismaili, M. A., Saidi, B., Zahar, M., Hamama, A., & Ezzaier, R. (2019). Composition and microbial quality of raw camel milk produced in Morocco. *J Saudi Soc,* 18(1), 17–21. [DOI:10.1016/j.jssas.2016.12.001]
- Jrad, Z., Girardet, J.M., Adt, I., Oulahal, N., Degraeve, P., Khorchani, T., El-Hatmi, H. (2014). Antioxidant activity of camel milk casein before and after in vitro simulated enzymatic digestion. *Mljekarstvo.* 64(4), 287–294. [DOI:10.15567/mljekarstvo.2014.0408]
- Jrad, Z., El Hatmi, H., Adt, I., Girardet, J.M., Cakir-Kiefer, C., Jardin, J., Degraeve, P., Khorchani, T., Oulahal, N. (2014). Effect of digestive enzymes on antimicrobial, radical scavenging and angiotensin I-converting enzyme inhibitory activities of camel colostrum and milk proteins. *Dairy Sci Technol.* 94 (3), 205–224. [DOI:10.1007/s13594-013-0154-1]
- Kadkhodae, M., Khastar, H., Arab, H.A., Ghaznavi, R., Zahmatkesh, M., Mahdavi-Mazdeh, M. (2007). Antioxidant vitamins preserve superoxide dismutase activities in gentamicin-induced nephrotoxicity. *Transplant. Proce.* 39(4), 864–865. [DOI:10.1016/j.transproceed.2007.02.038] [PMID]
- Karahan, I., Ateşşahin, A., Yilmaz, S., Çeribaşı, A.O., Sakin, F. (2005). Protective effect of lycopene on gentamicin-induced oxidative stress and nephrotoxicity in rats. *Toxicology.* 215(3), 198–204. [DOI:10.1016/j.tox.2005.07.007] [PMID]
- Khalesi, M., Salami, M., Moslehishad, M., Winterburn, J., & Moosavi-Movahedi, A. A. (2017). Biomolecular content of camel milk: A traditional superfood towards future healthcare industry. *Trends Food Sci Technol.* 62, 49–58. [DOI:10.1016/j.tifs.2017.02.004]
- Khan, A.A., Alzohairy, M.A., Mohieldein, A.H. (2013). Antidiabetic effects of camel milk in streptozotocin-induced diabetic rats. *Am J Biochem Mol Biol.* 3(1), 151–158. [DOI:10.3923/ajbmb.2013.151.158]
- Khan, S.A., Priyamvada, S., Farooq, N., Khan, S., Khan, M.W., Yusufi, A.N.K. (2009). Protective effect of green tea extract on gentamicin-induced nephrotoxicity and oxidative damage in rat kidney. *Pharmacol Res.* 59 (4), 254–262. [DOI:10.1016/j.phrs.2008.12.009] [PMID]

- Kumar, D., Verma, A.K., Chatli, M.K, Sing, R., Kumar, P., Mehta, N., Malav, O.P. (2016). Camel milk: alternative milk for human consumption and its health benefits. *Nutr Food Sci.* 46(2), 217–227. [DOI:10.1108/NFS-07-2015-0085]
- Kumar, D., Chatli, M. K., Singh, R., Mehta, N., & Kumar, P. (2016). Antioxidant and antimicrobial activity of camel milk casein hydrolysates and its fractions. *Small Rumin Res.* 139, 20-25. [DOI:10.1016/j.smallrumres.2016.05.002]
- Kumar, D., Chatli, M. K., Singh, R., Mehta, N., & Kumar, P. (2016). Enzymatic hydrolysis of camel milk casein and its antioxidant properties. *Dairy Sci Technol.* 96(3), 391-404. [DOI:10.1007/s13594-015-0275-9]
- Lee, K. E., Kim, E. Y., Kim, C. S., Choi, J. S., Bae, E. H., Ma, S. K., ... & Kim, S. W. (2013). Macrophage-stimulating protein attenuates gentamicin-induced inflammation and apoptosis in human renal proximal tubular epithelial cells. *Biochem Biophys Res Commun.* 434(3), 527-533. [DOI:10.1016/j.bbrc.2013.03.108] [PMID]
- Legesse, A., Adamu, F., Alamirew, K., & Feyera, T. (2017). A comparative study on the physico-chemical parameters of milk of camel, cow and goat in Somali Regional State. Ethiopia. *Chem Sci J*, 8(4), 171.
- Lopez-Novoa, J. M., Quiros, Y., Vicente, L., Morales, A. I., & Lopez-Hernandez, F. J. (2011). New insights into the mechanism of aminoglycoside nephrotoxicity: an integrative point of view. *Kidney Int.* 79(1), 33-45. [DOI:10.1038/ki.2010.337] [PMID]
- Maldonado, P. D., Barrera, D., Medina-Campos, O. N., Hernández-Pando, R., Ibarra-Rubio, M. E., & Pedraza-Chaverrí, J. (2003). Aged garlic extract attenuates gentamicin induced renal damage and oxidative stress in rats. *Life Sci.* 73(20), 2543-2556. [DOI:10.1016/S0024-3205(03)00609-X]
- Manshare, K., Anand, A., Mahajan, S., Satija, S., Sharma, N., Khurana, N., ...& Mehta, M. (2018). Evaluation of Nephroprotective Activity of Gallic Acid in Gentamicin-induced rat Model of Nephrotoxicity. *Int J Green Pharm.* 48-52.
- Martinez-Salgado, C., López-Hernández, F. J., & López-Novoa, J. M. (2007). Glomerular nephrotoxicity of aminoglycosides. *Toxicol Appl Pharmacol.* 223(1), 86-98. [DOI:10.1016/j.taap.2007.05.004] [PMID]
- Maryniak, N. Z., Hansen, E. B., Ballegaard, A. R., & Bøgh, K. L. (2018, August). Immunogenicity and allergenicity of camel and cow's milk: a comparative study in brown Norway rats. In *Allergy* Wiley, NJ, USA, Vol.73, pp 253-254.
- McGlynn, H., & Ryan, M. P. (1993). In vitro mechanisms and models of gentamicin nephrotoxicity. *Toxicol In Vitro.*7(4), 407-410. [DOI:10.1016/0887-2333(93)90037-6]
- Mirmiran, P., Ejtahed, H. S., Angoorani, P., Eslami, F., & Azizi, F. (2017). Camel milk has beneficial effects on diabetes mellitus: A systematic review. *Int J Endocrinol Metabol.* 15(2). [DOI:10.5812/ijem.42150] [PMID] [PMCID]
- Moreira, M. A., Nascimento, M. A., Bozzo, T. A., Cintra, A., da Silva, S. M., Dalboni, M. A., ... & Higa, E. M. (2014). Ascorbic acid reduces gentamicin-induced nephrotoxicity in rats through the control of reactive oxygen species. *Clin Nutr.* 33(2), 296-301. [DOI:10.1016/j.clnu.2013.05.005] [PMID]
- Morin, J. P., Viotte, G., Vandewalle, A., Van Hoof, F., Tulkens, P., & Fillastre, J. P. (1980). Gentamicin-induced nephrotoxicity: a cell biology approach. *Kidney Int.* 18(5), 583-590. [DOI:10.1038/ki.1980.176] [PMID]
- Öztopuz, Ö., Türkön, H., Sehitoglu, M. H., Büyük, B., Uzun, M., Ovali, M. A., & Demir, U. (2019). Hyperbaric oxygen treatment ameliorates gentamicin-induced nephrotoxicity and expression of kidney injury molecule 1 in the rat model. *Undersea & hyperbaric medicine: journal of the Undersea and Hyperbaric Medical Society, Inc*, 46(2), 125-133. [DOI:10.22462/04.06.2019.5]
- Parlakpınar, H. A. K. A. N., Tasdemir, S. E. D. A., Polat, A. L. A. A. D. İ. N., Bay-Karabulut, A., Vardi, N. İ. G. A. R., Ucar, M. U. H. A. R. R. E. M., & Acet, A. (2005). Protective role of caffeic acid phenethyl ester (CAPE) on gentamicin-induced acute renal toxicity in rats. *Toxicology.* 207(2), 169-177. [DOI:10.1016/j.tox.2004.08.024] [PMID]

- Poulikakos, P., & Falagas, M. E. (2013). Aminoglycoside therapy in infectious diseases. *Expert Opin Pharmacother.* 14(12), 1585-1597. [DOI:10.1517/14656566.2013.806486] [PMID]
- Priyamvada, S., Priyadarshini, M., Arivarasu, N. A., Farooq, N., Khan, S., Khan, S. A., ... & Yusufi, A. N. K. (2008). Studies on the protective effect of dietary fish oil on gentamicin-induced nephrotoxicity and oxidative damage in rat kidney. *Prostaglandin Leukot Essent Fatty Acids*, 78(6), 369-381. [DOI:10.1016/j.plefa.2008.04.008] [PMID]
- Quiros, Y., Vicente-Vicente, L., Morales, A. I., López-Novoa, J. M., & López-Hernández, F. J. (2011). An integrative overview on the mechanisms underlying the renal tubular cytotoxicity of gentamicin. *Toxicol Sci.* 119(2), 245-256. [DOI:10.1093/toxsci/kfq267] [PMID]
- Quirós, Y., Blanco-Gozaño, V., Sanchez-Gallego, J. I., López-Hernandez, F. J., Ruiz, J., de Obanos, M. P. P., & López-Novoa, J. M. (2016). Cardiotrophin-1 therapy prevents gentamicin-induced nephrotoxicity in rats. *Pharmacol Res.* 107, 137-146. [DOI:10.1016/j.phrs.2016.02.025] [PMID]
- Raju, S., Kavimani, S., Reddy, K. S., & Kumar, G. V. (2011). Floral extract of *Tecoma stans*: A potent inhibitor of gentamicin-induced nephrotoxicity in vivo. *Asian Pac J Trop Med.* 4(9), 680-685. [DOI:10.1016/S1995-7645(11)60173-9]
- Randjelovic, P., Veljkovic, S., Stojiljkovic, N., Sokolovic, D., & Ilic, I. (2017). Gentamicin nephrotoxicity in animals: Current knowledge and future perspectives. *EXCLI journal*, 16, 388.
- Rodrigues, F. A., Prata, M. M., Oliveira, I. C., Alves, N. T., Freitas, R. E., Monteiro, H. S., ... & Havt, A. (2014). Gingerol fraction from *Zingiber officinale* protects against gentamicin-induced nephrotoxicity. *Antimicrob Agents Chemother.* 58(4), 1872-1878. [PMCID] [DOI:10.1128/AAC.02431-13] [PMID]
- Salami, M., Moosavi-Movahedi, A. A., Moosavi-Movahedi, F., Ehsani, M. R., Yousefi, R., Farhadi, M., ... & Haertlé, T. (2011). Biological activity of camel milk casein following enzymatic digestion. *J Dairy Res.* 78(4), 471. [DOI:10.1017/S0022029911000628] [PMID]
- Salami, M., Yousefi, R., Ehsani, M. R., Dalgalarondo, M., Chobert, J. M., Haertlé, T., ... & Moosavi-Movahedi, A. A. (2008). Kinetic characterization of hydrolysis of camel and bovine milk proteins by pancreatic enzymes. *Int Dairy J.* 18(12), 1097-1102. [DOI:10.1016/j.idairyj.2008.06.003]
- Shamim, S., Rana, M. A., Arshad, N., Kumar, A., & Islam, C. N. (2018). Evaluation of nephroprotective effect of ethanolic extract of leaves of *aloe barbadensis* against gentamicin induced nephrotoxicity in rats. *Clin Res.* 4(4), 70-73.
- Srivastava, P., Rao, R., Shenoy, P. J., Poornima, A. M., Teerthanath, S., & Bhuvaneshwari, S. (2018). Nephroprotective effect of *Anethum graveolens* in a murine model of gentamicin induced nephrotoxicity. *Young Pharm.* 10(2), 155. [DOI:10.5530/jyp.2018.10.35]
- Stojiljkovic, N., Stoilkovic, M., Randjelovic, P., Veljkovic, S., & Mihailovic, D. (2012). Cytoprotective effect of vitamin C against gentamicin-induced acute kidney injury in rats. *Exp Toxicol Pathol.* 64(1-2), 69-74. [DOI:10.1016/j.etp.2010.06.008] [PMID]
- Stojiljkovic, N., Mihailovic, D., Veljkovic, S., Stoilkovic, M., & Jovanovic, I. (2008). Glomerular basement membrane alterations induced by gentamicin administration in rats. *Exp Toxicol Pathol.* 60(1), 69-75. [DOI:10.1016/j.etp.2008.02.007] [PMID]
- Sun, H., Yang, H., Ruan, H., Li, W., He, X., Wang, L., ... & Zhang, J. (2018). The protective effect of sika deer antler protein on gentamicin-induced nephrotoxicity in vitro and in vivo. *Cell Physiol Biochem.* 50(3), 841-850. [DOI:10.1159/000494471] [PMID]
- Tavafi, M. (2013). Protection of renal tubules against gentamicin induced nephrotoxicity. *J Renal Inj Prev.* 2(1), 5-6.
- Truong, V. L., Jun, M., & Jeong, W. S. (2018). Role of resveratrol in regulation of cellular defense systems against oxidative stress. *Biofactors.* 44(1), 36-49. [DOI:10.1002/biof.1399] [PMID]
- Ulu, R., Gozel, N., Tuzcu, M., Orhan, C., Yiğit, İ. P., Dogukan, A., ... & Juturu, V. (2018). The effects of *Mucunapuriens* on the renal oxidative stress and transcription factors in high-fructose-fed rats. *Food Chem Toxicol.* 118, 526-531. [DOI:10.1016/j.fct.2018.05.061] [PMID]

- Kumar, K. V., Shifow, A. A., Naidu, M. U. R., & Ratnakar, K. S. (2000). Carvedilol: a beta blocker with antioxidant property protects against gentamicin-induced nephrotoxicity in rats. *Life Sci.* 66(26), 2603-2611. [[DOI:10.1016/S0024-3205\(00\)00594-4](https://doi.org/10.1016/S0024-3205(00)00594-4)]
- Walker, P. D., & Shah, S. V. (1988). Evidence suggesting a role for hydroxyl radical in gentamicin-induced acute renal failure in rats. *J Clin.* 81(2), 334-341. [[PMID](#)] [[PMCID](#)] [[DOI:10.1172/JCI113325](https://doi.org/10.1172/JCI113325)]
- Yadav, A. K., Kumar, R., Priyadarshini, L., & Singh, J. (2015). Composition and medicinal properties of camel milk: A Review. *Asian Journal of Dairy and Food Research.* 34(2), 83-91. [[DOI:10.5958/0976-0563.2015.00018.4](https://doi.org/10.5958/0976-0563.2015.00018.4)]
- Yaman, İ., & Balikci, E. (2010). Protective effects of *Nigella sativa* against gentamicin-induced nephrotoxicity in rats. *Exp Toxicol Pathol.* 62(2), 183-190. [[PMID](#)] [[DOI:10.1016/j.etp.2009.03.006](https://doi.org/10.1016/j.etp.2009.03.006)]
- Yarijani, Z. M., Najafi, H., & Madani, S. H. (2016). Protective effect of crocin on gentamicin-induced nephrotoxicity in rats. *Iran J Basic Med Sci,* 19(3), 337.
- Zorov, D. B. (2010). Amelioration of aminoglycoside nephrotoxicity requires protection of renal mitochondria. *Kidney Int.* 77(10), 841-843. [[DOI:10.1038/ki.2010.20](https://doi.org/10.1038/ki.2010.20)] [[PMID](#)]

## اثر محافظتی شیر شتر بر نفروتوکسیسیتی ناشی از جنتامیسین؛ از بیومارکرهای کلیوی تا شواهد هیستوپاتولوژی

فرشته عرب<sup>۱</sup>، سعیده نعیمی<sup>۲\*</sup>، عباس جواهری وایقان<sup>۳</sup>، احد محمدنژاد<sup>۴</sup>، محمود احمدی همدانی<sup>۵</sup>

<sup>۱</sup> دانشجوی دکتری عمومی دامپزشکی، دانشکده دامپزشکی، دانشگاه سمنان، سمنان، ایران

<sup>۲</sup> گروه علوم پایه، دانشکده دامپزشکی، دانشگاه سمنان، سمنان، ایران

<sup>۳</sup> گروه پاتوبیولوژی، دانشکده دامپزشکی، دانشگاه سمنان، سمنان، ایران

<sup>۴</sup> مرکز تحقیقات بیولوژی سرطان، انستیتو کنسر ایران، دانشگاه علوم پزشکی تهران، تهران، ایران

<sup>۵</sup> گروه علوم درمانگاهی، دانشکده دامپزشکی، دانشگاه سمنان، سمنان، ایران

(دریافت مقاله: ۰۲ شهریور ماه ۱۳۹۹، پذیرش نهایی: ۰۵ آبان ماه ۱۳۹۹)

**زمینه مطالعه:** جنتامیسین یک آنتی‌بیوتیک موثر بوده اما اثرات جانبی مهمی از جمله مسمومیت کلیه دارد. شواهدی وجود دارد که نشان می‌دهد شیر شتر دارای اثرات محافظت کلیوی و اثرات آنتی‌اکسیدانتی است.

**هدف:** در این مطالعه، اثر شیر شتر بر مسمومیت کلیوی ناشی از جنتامیسین ارزیابی شده است.

**روش کار:** ۲۴ قطعه موش صحرایی نژاد ویستار به چهار گروه مساوی تقسیم شدند: گروه ۱: گروه کنترل (دریافت‌کننده نرمال سالین)، گروه ۲: دریافت‌کننده جنتامیسین (۱۰۰ mg/kg)، گروه ۳: دریافت‌کننده شیر شتر (۵ میلی‌لیتر در روز به مدت ۱۵ روز، خوراکی) و گروه ۴: تجویز جنتامیسین و شیر شتر (۵ روز اول شیر شتر و سپس ۱۰ روز جنتامیسین ۱۰۰ mg/kg). پس از اتمام دوره درمان، نمونه سرم اخذ و میزان اوره، کراتینین و سوپراکسید دسموتاز (SOD) اندازه‌گیری شد. سپس برای بررسی تغییرات پاتولوژی، از کلیه‌ها مقاطع هیستوپاتولوژی تهیه و بررسی شدند.

**نتایج:** جنتامیسین موجب افزایش اوره، کراتینین و کاهش SOD شد. تغییرات معنی‌داری نیز در هیستوپاتولوژی مانند کست‌های انوزینوفیلی در لومن توبولی احتقان مویرگی، گلوومرولونفریت، نکروز، نفریت بینابینی و ادم در کلیه‌ها مشاهده شد ( $P < 0.05$ ). اوره و کراتینین سرم به‌طور معنی‌داری توسط تجویز هم‌زمان شیر شتر کاهش یافت ( $P < 0.05$ ). یک افزایش معنی‌دار در فعالیت SOD سرم در مقایسه با گروه دوم مشاهده شد ( $P < 0.05$ ). همچنین شیر شتر به‌طور معنی‌داری موجب جلوگیری از آسیب بافتی کلیه در مقایسه با گروه دوم شد.

**نتیجه‌گیری نهایی:** نتایج مطالعه حاضر نشان داد که شیر شتر می‌تواند موجب کاهش معنی‌دار تغییرات بیوشیمیایی و هیستوپاتولوژی ناشی از جنتامیسین در کلیه شود.

**واژه‌های کلیدی:** شیر شتر، مسمومیت کلیه، جنتامیسین، استرس اکسیداتیو، موش صحرایی