

Sheep abomasal phytobezoariasis: the effect of breed, season and age with histopathological observations

Azizi, S.^{1*}; Farshid, A.A.²; Mardani, K.³ and Farzaneh, H.⁴

¹Department of Clinical Sciences, Faculty of Veterinary Medicine, Urmia University, Urmia, Iran. ²Department of Pathobiology, Faculty of Veterinary Medicine, Urmia University, Urmia, Iran. ³Department of Food Hygiene and Quality Control, Faculty of Veterinary Medicine, Urmia University, Urmia, Iran. ⁴Veterinary Private Practitioner, Urmia, Iran.

Key Words:

Sheep; abomasal phytobezoariasis; breed and season.

Correspondence

Azizi, S.,
Department of Clinical Sciences,
Faculty of Veterinary Medicine, Urmia
University, P.O. Box: 57153-1177,
Urmia, Iran.
Tel.: +98(441)2772193
Fax: +98(441)2777099
E-mail: s.azizi@mail.urmia.ac.ir

Received 14 February 2009,

Accepted 24 October 2009

Abstract

The prevalence of the latent form of sheep abomasal phytobezoariasis and the effect of husbandry management on this condition were determined in a survey in and industrial abattoir in Urmia from June 2005 to July 2006. The effect of different age groups and seasons on the prevalence of sheep abomasal phytobezoariasis was also determined. Furthermore, the histological changes in the affected abomasal tissue were also verified. The breeds and ages of the sheep were identified prior to slaughter. In the post-mortem, the abomasum was examined for foreign bodies, including bezoars. Tissue specimens were taken from the abomasal body in the affected cases. The annual prevalence of sheep abomasal phytobezoariasis was 1.95%. The prevalence was highest in the Makuei breed and the lowest in Ghezel sheep. The prevalence was higher in winter compared to other seasons. The number of phytobezoars per abomasums ranged from one to four. The histopathological changes in the affected cases included leukocytic infiltration in the mucosal layer, edema, glandular hyperplasia and cystic spaces.

Introduction

West Azerbaijan is a major sheep farming province in Iran. In addition, sheep husbandry is one of the most important farming activities of rural and tribal communities in this province. Sheep are mainly reared in transhumance systems. Ghezel, Makuei, Herrick and Afshari are the most important fat-tailed ecotypes or breeds.

Bezoars are recognized as a form of concretion, which develop within the gastrointestinal tract of animals and humans. Based on their composition, bezoars are further categorized into five subtypes that include phytobezoars, trichobezoars, lactobezoars, medicinal or pharmacobezoars, and concretions (Anderson and St-Jean, 2002; Kishan *et al.*, 2003; Ku, 1996). However, trichobezoars, phytobezoars, and a mixture of both, which are named phytotrachobezoars, are the most common subtypes reported in veterinary medicine (Oehme and Prier, 1986). Overall, the formation of bezoars appears to be most prevalent in ruminants, particularly in small ones. Gastrointestinal phytobezoars are also reported in humans (Holloway *et al.*, 1980), horses (Mealey *et al.*, 1995; Cummings *et al.*, 1997), cattle (Radostits *et al.*, 2000), sheep, and goats (Bath, 1978; Bath *et al.*, 1992; Oehme and Prier, 1986).

The results of a field study (Azizi and Mirza-

Aghazadeh, 2007) and clinical observations have shown that abomasal phytobezoariasis is one of the most common causes of death in Herrick sheep during 1998 to 2003 in Urmia, Iran. In the affected patients, phytobezoars are formed within the abomasum over a period of a few months. There are limited clinical manifestations in the latent phase. Then, due to gradual loss of appetite and the abomasal impaction, the affected sheep becomes progressively weak, which finally causes emaciation and death if the animal is not treated surgically. In Iran, sheep abomasal impaction due to phytobezoariasis has not been reported to date. The abomasal impaction is only observed in Herrick sheep and not in other breeds in Urmia. The purposes of this abattoir study were to determine the prevalence of the latent form of sheep abomasal phytobezoariasis and to assess the effect of husbandry management, the different ages of the sheep and seasons on this condition. Furthermore, the histological changes in the affected abomasal tissues were also verified.

Materials and Methods

The prevalence of abomasal phytobezoariasis was determined by post-mortem examination on 5,781 sheep carcasses (Ghezel: 1,514; Herrick: 2,692; Afshari: 808; and Makuei: 767) in an industrial abattoir

in Urmia between June 2005 to July 2006. In this cross-sectional observational study, the types of bezoars with or without abomasal impaction were distinguished by the different ecotypes or breeds, the different age groups of the animals, and the season at the time of examination. Tissue specimens were also collected from the affected sheep to determine the histopathological changes.

In the slaughterhouse, the sheep were examined three days in a week, twice a month, throughout all four seasons. The type of ecotype or breed was identified according to phenotypic characteristics (Saadat-Nouri and Siaah-Mansour, 1996; Mirza-Aghazadeh, 2007), the case history and the managerial types of the flocks. The animals were categorized into four breeds: Ghezel, Makuei, Herrick and Afshari.

Ante-mortem examinations were carried out on apparently healthy sheep. The ages of the animals were determined by the dental formula (Oehme and Prier, 1986; Saadat-Nouri and Siaah-Mansour, 1996). The forestomach and abomasum were examined in the post-mortem inspection to find out any gross pathological changes, presence of foreign bodies, bezoars and any impaction. A tissue specimen was taken from the ventral part of the body if the abomasum carried one or more bezoars. Tissue samples of 1.5 x 2 cm were fixed in 10% buffered formalin.

The abomasal bezoars were collected and left to dry at room temperature. The phytobezoars were identified according to their physical characteristics (Anderson and St-Jean, 2002; Jubb *et al.*, 1985; Sastry and Rao, 2001), reaction with iodine solution (Makkar, 2003), and microscopic examination by a simple modified hematoxylin and eosin (H&E) stain. The tissue samples were prepared for histopathological study using routine processes and stained with H&E. The prevalence of abomasal phytobezoariasis was calculated and the obtained data was analyzed using the MINITAB statistical package (Version 14 Minitab Inc. USA). Fisher's exact test was used to compare the prevalence of phytobezoariasis in different ecotypes or breeds and in different seasons for each managerial type. A value of $p < 0.05$ was considered significant.

Results

A total number of 5,781 sheep abomasums were examined and 145 phytobezoars were identified from 113 carcasses (Ghezel: 18; Herrick: 49; Afshari: 20; and Makuei: 26). The annual prevalence of abomasal phytobezoariasis in sheep was 1.95%. Table 1 displays the distribution of abomasal phytobezoariasis in different ecotypes or breeds during the study period. Overall, the prevalence was highest in the Makuei breed and lowest in Ghezel sheep. Abomasal phytobezoariasis was higher in winter compared to other seasons.

The prevalence of abomasal phytobezoariasis in yearlings was less than in sheep that were approximately two years old (11.5% vs. 88.5%; $p < 0.001$). Also, only one phytobezoar per case were identified in the yearlings. In adults, the minimum number was one phytobezoar per case and maximum number was four, which was found in Herrick sheep.

The prevalence of sheep abomasal phytobezoariasis in different ecotypes or breeds and seasons were statistically analyzed (Tables 2 and 3). There was significant difference between the prevalence of abomasal phytobezoariasis in Ghezel sheep in comparison to Makuei and Afshari. The prevalence was higher in Makuei sheep in comparison to Herrick sheep. There was significant difference between the prevalence of sheep abomasal phytobezoariasis in winter in comparison to autumn, summer and spring. In addition, the prevalence was higher in autumn in comparison to spring.

Macroscopically, the phytobezoars were a thick spherical to oval in shape, gray to dark brown in color, smooth in surface; they were so hard that it was not possible to incise them using a sharp instrument. When moist, the phytobezoars were still very firm and difficult to break. The phytobezoars ranged from 10 x 8 x 12 mm to a maximum of 42 x 38 x 39 mm in diameter with a mean size of 26 x 28 x 35 mm.

In macroscopic examinations, the abomasums that contained single bezoars did not show gross abnormalities, but when the number of the bezoars increased there was a mild congestion of the mucosa and thickening of the abomasal body. A total number of 15 tissue specimens were examined by light microscopy. The most important histopathological findings were leukocytic infiltration in the mucosal layer (Figure 1), edema, glandular hyperplasia and cystic spaces (Figure 2). In almost all cases, focal leukocytic infiltrations were seen, but in one case, diffuse infiltration that extended into muscular and serosal layers was evident. Some hyperplastic changes of mucosal cells were observed in several cases.

Discussion

The annual prevalence of sheep abomasal phytobezoariasis in the present study was 1.95%. There were no documented reports about the prevalence of sheep abomasal phytobezoariasis in the literature. The occurrence of abomasal phytobezoariasis in ruminants is rare and, usually, it occurs in the sporadic form (Ravikumar *et al.*, 1989; Sargison *et al.*, 1995; Sherman, 1981). However, large numbers of sheep and goats could be affected simultaneously by the disease due to some particular management circumstances (Bath *et al.*, 1992; Oehme and Prier, 1986). An enzootic-like occurrence of abomasal phytobezoariasis has been observed among Herrick sheep flocks in

Table 1: Distribution of sheep abomasal phytozoariasis in different ecotypes/ breeds in an industrial abattoir in Urmia from June 2005 to July 2006.

Breed \ Season	Summer	Autumn	Winter	Spring	Total number observed
Herrick Affected No.	11	7	22	9	2692
Makuei Affected No.	5	6	14	1	767
Afshari Affected No.	3	6	10	1	808
Ghezel Affected No.	3	4	9	2	1514
Total Affected No.	22	23	55	13	113
Total number observed	1522	1286	1462	1511	5781

Table 2: Comparison of the percentage of abomasal phytozoariasis in different ecotypes/ breeds of sheep in an industrial abattoir in Urmia from June 2005 to July 2006.

Ecotype /Breed	Percentage
Ghezel	1.19 ^a
Herrick	1.82 ^a
Afshari	2.47 ^b
Makuei	3.39 ^b

^{a,b} Values with different superscripts are significantly different ($p < 0.05$). The values for all sheep breeds were compared to each other.

Table 3: Comparison of the percentage of sheep abomasal phytozoariasis in different seasons in Urmia industrial abattoir from June 2005 to July 2006.

Percentage	Season
Spring	0.86 ^a
Summer	1.44 ^a
Autumn	1.78 ^{ab}
Winter	3.76 ^c

^{a,b,c} Values with different superscripts are significantly different ($p < 0.05$).

Urmia (Azizi and Mirza-Aghazadeh, 2008).

Phytozoars in ruminants are documented poorly (Sargison *et al.*, 1995). These are mainly formed in the abomasum (Mealey *et al.*, 1995). Abomasal phytozoariasis are unlikely to cause apparent clinical signs unless the number and magnitude of the foreign bodies are severe (Nadaliyan, 2002; Radostits *et al.*, 2000; Sherman, 1981). Furthermore, pyloric obstruction or small intestinal (mostly duodenal and jejunal) obstruction could cause abdominal distention and colic due to phytozoar movement during the sudden ration alteration to fresh wet roughages (Anderson and St-Jean, 2002; Jubb *et al.*, 1985; Nadaliyan, 2002; Oehme and Prier, 1986; Radostits *et al.*, 2000).

In a unique form of abomasal impaction caused by numerous phytozoar accumulation, as observed among Herrick sheep flocks in Urmia, clinical manifestation in the latent phase of disease is limited. However, when the impaction is suspected, abomasotomy is mandatory to save the life of the affected sheep (Azizi and Mirza-Aghazadeh, 2008; Newmand, 2003; Torkamani, 2003).

Figure 1: Abomasum of sheep with phytozoars showing leukocytic infiltration in between the mucosal glands (H&E x400).

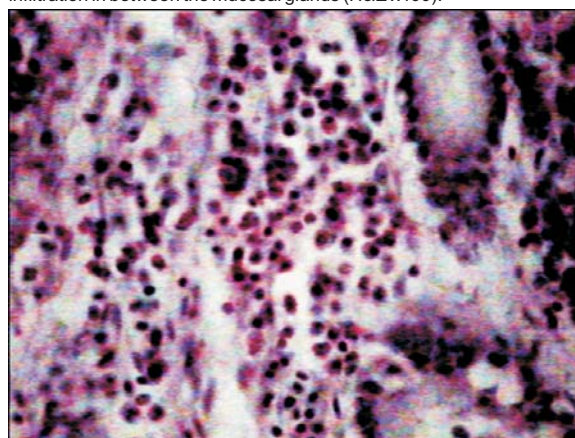
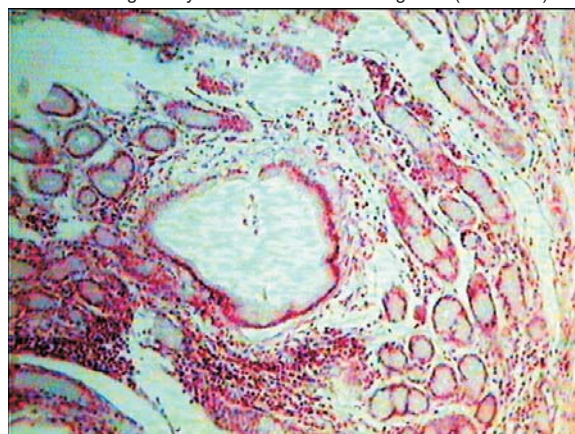


Figure 2: Abomasum of sheep with phytozoars showing leukocytic infiltration along with cystic dilatation of mucosal glands (H&E x100).



There are no special paraclinical or ancillary tests found in the literature to diagnose abomasal phytozoars in sheep. However, plain lateral radiography could help diagnose substantial abomasal phytozoars or the use of contrast media with barium sulfate, as performed in the residual technique, might lead to the diagnosis of abomasal foreign bodies in Herrick sheep (Torkamani, 2003). However, the latter technique requires an extensive period of time.

The low prevalence of abomasal phytozoariasis in the Ghezel breed in comparison to Makuei and Afshari sheep might be related to the different management types of these sheep in the study area. Ghezel flocks are generally managed as a farm sheep. The flocks of this breed are mainly kept in rural areas with limited access to natural countryside pastures and basically fed with agricultural by-products. They usually have access to drinking water throughout the grazing period, starting from the beginning of the spring until the late dry period.

The prevalence of phytozoariasis was higher in

Makuei sheep compared with Herrick sheep. However, the impaction form of abomasal phytobezoariasis was high in Herrick sheep, which is compatible with the course of disease history that was observed in field studies (Azizi and Mirza-Aghazadeh, 2008). It seems that the lack of the abomasal impaction form found in Ghezel, Makuei and Afshari sheep in the present study gives us an acceptable management of these flocks for this condition. The occurrence of numerous phytobezoars in many sheep might be related to the low quality of their diets.

The higher prevalence of abomasal phytobezoariasis in winter compared with other seasons and the higher prevalence of affected sheep in autumn compared with spring in the present study is consistent with the course of abomasal phytobezoar formation in autumn and winter (Nadaliyan, 2002; Oehme and Prier, 1986; Radostits *et al.*, 2000).

The low prevalence of abomasal phytobezoariasis in yearlings in the present study is concurrent with the results of Sargison (1995), which shows that phytobezoars, in contrast with trichobezoars, are very rare in young ruminants. This may be due in part to sheep of this age being usually under well-established management treatment for meat production.

The number of phytobezoars in young and adult ruminants usually is very low, one per case, but a large amount of phytobezoars might result from problems in nutritional management, as has been found in Herrick sheep in Urmia (Azizi and Mirza-Aghazadeh, 2008) and sheep and goats of the arid zones of Africa (Bath, 1978, Oehme and Prier, 1986).

The relationship between abomasal trichobezoars and perforating abomasal ulcers in unweaned beef calves has been investigated in one study (Jelinski, *et al.*, 1996), but young ruminants are usually affected by rumen trichobezoariasis. The lack of roughage in diet, high stocking density, pruritis (itchiness of skin) due to heavy mite or lice infestation, or some unknown dietary deficiency might cause of excessive ingestion of hair or wool in the young ruminants (Anderson and St-Jean, 2002; Jubb *et al.*, 1985; Sastry and Rao, 2001). These factors usually cause rumen trichobezoariasis in young ruminants.

The maximum number of abomasal phytobezoars in the present study was four per each sheep, which was observed in Herrick sheep. However, this could rise to 18 in number in abomasal impaction (Torkamani, 2003). The phytobezoars varied in weight and size. In the present study the maximum diameter of phytobezoar was nearly four centimeters but it can increase to 13 cm (Torkamani, 2003) or 15 cm (Bath, 1978) in an impaction situation.

The physical structure of the phytobezoar in the present study was similar to the findings of Bath *et al.* (1992) and Jubb *et al.* (1985). The color change in phytobezoars to dark brown might result from

polymerization of plant fibers in the presence of tannic acid and abomasal secretions (Kellam *et al.*, 2000; Min *et al.*, 2003).

Inflammation of the abomasums, which manifested in leukocytic infiltration in the mucosal layer, along with edema, cystic changes of glands and glandular hyperplasia, could be due to either physical irritation caused by the bezoars as a foreign body or the effect of parasitic infestation of the abomasum causing similar lesions (Farshid *et al.*, 2006; Jubb *et al.*, 1985). It has been well documented that chronic irritation of foreign bodies in the abomasum would bring about hyperplasia and hypertrophy of mucosal glands and is a defense mechanism against mechanical factors (Jubb *et al.*, 1985).

In conclusion, the prevalence of abomasal phytobezoariasis is rare in sheep in Urmia and this could be affected by season, breed, age and the types of animal management. Abomasal phytobezoariasis might cause mucosal thickness and hypertrophy. Abomasal phytobezoariasis should be considered in surgical exploration of the gastrointestinal tract of sheep.

References

1. Anderson, E.D.; St-Jean, G. (2002) Intraluminal Intestinal Obstruction: Trichobezoar, phytobezoar, and Enterolith. In: Current Veterinary Therapy "Food Animal Practice. Howard, J.M. and Smith, R.A., W. B. Saunders Co., Philadelphia. pp: 535-537.
2. Azizi, S.; Mirza-Aghazadeh, A. (2008) Determination of some epidemiological factors in abomasal phytobezoariasis in Herrick sheep. Report of project No. 008/D/82, 2008, Urmia University (In Persian).
3. Bath, G. F. (1978) Abomasal Phytobezoariosis of goats and sheep. J. South Afric. Vet. Ass. 49: 133.
4. Bath, G. F.; Botha, P.; Vorster, H. V. and Cross, R. H. M. (1992) Physical structure and chemical composition of abomasal phytobezoars of goat and sheep. J. South Afric. Vet. Ass. 63: 103-107.
5. Cummings, A. C.; Copedge, K. J. and Confer, W. A. (1997) Equine gastric impaction, ulceration and perforation due to persimmon (*Diospyros virginiana*) ingestion. J. Vet. Diagn. Invest. 9: 311-313.
6. Farshid, A. A.; Naem, S., and Banaie-Alipour R. (2006) Pathological changes of abomasum in naturally infected makoyee sheep with *Teladorsagia circumcincta*, Pakistan J. Bio. Sci. 9: 2145-2148.
7. Holloway, W. D.; Lee, S.P. and Nicholson, G. I. (1980). The Composition and Dissolution of Phytobezoars. Arch. Pathol. Lab. Med., 104, March: 159-161.
8. Jelinski, M. D.; Ribble, C. S.; Campbell, J. R. and Janzen E. D. (1996) Investigating the relationship between abomasal hairballs and perforating abomasal ulcers in unweaned beef calves. Can. Vet. J. 37: 23-26.
9. Jubb, C.; Kennedy, P. and Palmer, N. (1985) Pathology of

- Domestic Animals. 3rd edition, Vol. (2), Academic Press INC., San Diego. pp: 37-51,163-169,
10. Kellam, L. L.; Johnson, J. P. H.; Kramer, J. and Keegan, K. G. (2000) Gastric impaction and obstruction of the small intestine associated with persimmon phytobezoar in a horse. *J. Am. Vet. Med. Ass.* 216: 1279-1281.
 11. Kishan, A. S. N.; Kadli, N. K.; Ponnappa, B. G.; Korath, M. P. and Jagadeesan, K. (2003) Bezoars. [http:// www. bhj.org/journal/](http://www.bhj.org/journal/) pp: 1-8.
 12. Ku, T. M. (1996) Bezoars. *Clin. Toxi. Rev.* 18: 1-4.
 13. Makkar, H. P. S. (2003) Effects and fate of tannins in ruminant animals, adaptation to tannins, and strategies to overcome detrimental effects of feeding tannin-rich feeds, *Small Rum. Res.* 49: 241-256.
 14. Mealey, R. H.; Chaffin, M. K.; Peloso, J. G. and Crabill, M. R. (1995) Colonic Phytobezoar and volvulus in a colt. *Vet. Med.* 90: 982-984.
 15. Min, B. R.; Barry, T. N.; Attwood, G. T. and McNabb, W. C. (2003). The effect of condensed tannins on the nutrition and health of ruminants fed fresh temperate forages: a review. *Anim. feed sci. Tech.* 106: 3-19.
 16. Mirza-Aghazadeh, A. (2007) A Research in Herrick sheep agricultural system in West Azerbaijan Province, No. 1338, Report of National Research Program, Agricultural Commission (In Persian). pp: 90-127
 17. Nadaliyan, M. (2002) The Alimentary Tract Diseases (Diseases of mouth, pharynx, esophagus, proventriculus, and abomasum) Nso. 2289, 2nd edition, Tehran University Press, Tehran (In Persian). pp: 306-321.
 18. Newmand, M. (2003) Histopathological study of abomasal body in abomasal phytobezoariasis in Herrick sheep. DVM Thesis, No. 672, Faculty of Veterinary Medicine, Urmia University (In Persian).
 19. Oehme, W. F.; Prier, E. J. (1986) Text Book of Large Animal Surgery, 3rd edition, Williams and Welkins Company, London. pp: 451-459
 20. Radostits, O. M.; Gay, C. C.; Blood, D. C. and Hinchcliff, K. (2000) The textbook of the disease of cattle, sheep, pigs, goats, and horses. 9th edition, W.B. Saunders LTD, Philadelphia. pp: 280-346.
 21. Ravikumar, S. B.; Nanjappa, M. A. and Gajendraged, M. R. (1989) Rare Cases of Phytobezoars in Sheep. *Indian Vet. J.* 66: 361.
 22. Saadat-Nouri, M.; Siaah-Mansour, S. (1996) Sheep Husbandry, 7th edition, Ashrafi Press, Tehran (In Persian). pp: 70-105.
 23. Sargison, N. D.; Scott, P. R. and Dun, K.A. (1995) Intestinal obstruction in a blue faced Leicester ram associated with a phytobezoar lodged at the pelvic inlet. *Vet. Rec.* 137: 222.
 24. Sastry, A. G.; Rao, P. R. (2001) Veterinary Pathology, 7th edition, CBS publisher & Distributor, India. pp: 15-21.
 25. Sherman, D. M. (1981). Duodenal obstruction by a phytobezoar in goat. *J. Am. Vet. Med. Ass.* 178: 139-140.
 26. Torkamani, D. (2003) Radiographical detection of abomasal phytobezoars in sheep. DVM Thesis, No. 776,

Faculty of Veterinary Medicine, Urmia University (In Persian).