

A case of perosomus elumbis concurrent with visceral abnormalities in a Holstein calf

Eslami, M.¹, Gharagozloo, F.^{2*}, Rahimi Feyli, P.³, Vojgani, M.², Soroori, S.⁴

¹Department of Theriogenology and Poultry, Faculty of Veterinary Medicine, University of Urmia, Urmia, Iran

²Department of Theriogenology, Faculty of Veterinary Medicine, University of Tehran, Tehran, Iran

³Department of Clinical Sciences, Faculty of Veterinary Medicine, Razi University, Kermanshah, Iran

⁴Department of Surgery and Radiology, Faculty of Veterinary Medicine, University of Tehran, Tehran, Iran

Key words:

congenital abnormality, Holstein calf, perosomus elumbis, vertebral column

Correspondence

Gharagozloo, F.
Department of Theriogenology,
Faculty of Veterinary Medicine,
University of Tehran, Tehran, Iran
Tel: +98(21) 61117164
Fax: +98(21) 66933222
Email: faramarz@ut.ac.ir

Received: 10 November 2013

Accepted: 22 January 2014

Abstract:

Perosomus elumbis is an occasional congenital anomaly of cattle, swine, sheep, and dogs with unknown etiology. This congenital abnormality occurs in both sexes. A dead Holstein calf characterized by musculoskeletal and external genitalia abnormalities was referred to the large animal hospital of University of Tehran. Radiographic evaluation and subsequent dissection revealed that the vertebral column was truncated at the level of first lumbar vertebra (L1). Moreover, L2-L5, sacrum and coccygeal vertebrae were absent. The dorsum of the lumbosacral region contained only soft tissues. Urogenital tract was incomplete, and it contained agenesis of the ovaries, uterine tubes, cervix, and vulva concurrent with unilateral umbilical artery agenesis. Small and large intestine contained blind-ended sacs. No testes, scrotum, and penis were found. The intact ureter was attached to a thin-walled fluid fill sac. The laboratory finding showed that the pH of the fluid was 6 and contained hemoglobin, white blood cells, bacteria, a few red blood cells, oxalate crystalline, and epithelial cells. It was concluded that the collected fluid was urine. This is the first report of perosomus elumbis in a Holstein calf having a lot of visceral abnormalities in Iran.

Case History

Perosomus elumbis, which occurs in ruminants and swines, is characterized by hypoplasia or aplasia of the spinal cord, which ends in the thoracic region. The regions of the body including the hindlimbs, which are normally supplied by the lumbar and sacral nerves, exhibit muscular atrophy, and joint movement does not develop. The rigidity of the posterior limbs may then cause dystocia (Noakes et al, 2009). This abnormality is a fairly common congenital defect in cattle (Roberts, 1986). It usually includes arthrogryposis of the hind limbs, characterized by ankylosis of the joints, with associated malformations of the musculature (Roberts, 1986). This

abnormality occurs in both sexes (Jones, 1999). Perosomus elumbis in a calf was first reported in the veterinary literature in 1832 by Ernst Gurlt, and since then cases have been reported (Jones, 1999). Congenital abnormalities may cause obstetrical problems and economic losses; hence, reporting more of these cases accompanied with other defects may help us to identify the exact etiology and prevent this complication in the future.

Perosomus elumbis with visceral abnormalities is less reported worldwide. This paper describes the clinical, necropsy, and radiographic evaluation of perosomus elumbis concurrent with a lot of visceral abnormalities in a Holstein calf.

Clinical Presentation

A dead Holstein calf characterized by angular hind limb and lumbar deformities, atresia of anus, rectum, vulva, and tail, and distended abdomen was referred to the animal hospital of University of Tehran (Figure 1). The calf was born alive but died after 2 days. The calf's birth weight was 27.3 kg.

Diagnostic Testing

Radiographic analysis and subsequent necropsy revealed that the vertebral column was truncated at the first lumbar (L1) level (Figure 2) with attached iliac wings, narrowed pelvic canal, and agenesis of the L2-L5, sacral and coccygeal vertebrae (Figure 3). The femurs were malformed. Spinal cord continued until L1. Thoracic vertebrae and ribs were normal. The back of the lumbosacral region was composed of only soft tissues.

Abdominal dissection showed a plenty of abnormalities. Agenesis of the ovaries, uterine tubes, cervix, and vulva concurrent with unilateral agenesis of renal and adrenal gland, ureter and umbilical artery were observed (Figure 4). No testes, scrotum, and penis were found. The intact ureter was attached to a thin-walled sac. The sac was instead of the urinary bladder and was passed by a vestibule like structure through the narrowed pelvic canal then fused to perianal region to excrete the urine. The fluid inside the sac was evacuated to analyze its component. The laboratory finding showed that the pH of the fluid was 6 and contained hemoglobin, white blood cells (WBC), bacteria, a few red blood cells (RBC), oxalate crystalline, and epithelial cells. As a result, the collected fluid was considered urine, as was expected.

The spiral and distal colon composed of moderately distended thin-walled blind-ending sacs. The blind sacs fused with narrow connective tissue to each other and filled with brown-yellow materials. The distal portion of the distal colon was dead-ended and the calf showed anal and rectal atresia.

Assessments

Congenital defects can result from disruptive



Figure 1. A Perosomus Elumbis calf with angular hind limb and lumbar deformities.

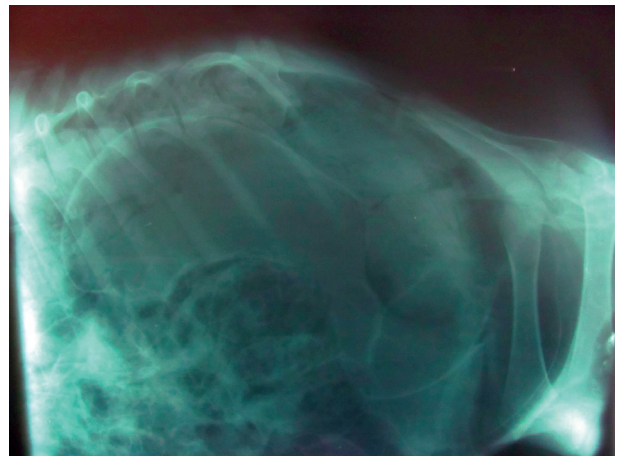


Figure 2. Radiographic region of vertebrae indicating the lack of L2-L5 lumbar vertebrae.

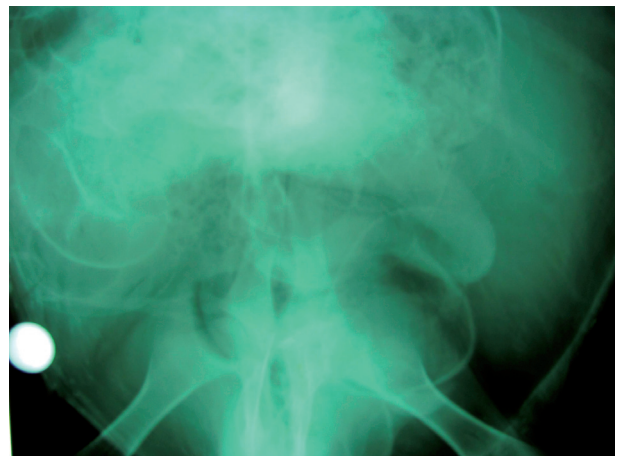

Figure 3. Ventrodorsal radiograph showing narrowed pelvic canal with attached iliac wings.

events at one or more stages during the complex transitions of embryonic and fetal development (Greene, 1973). Bovine inbreeding has increased the percentage of congenital defects in this species

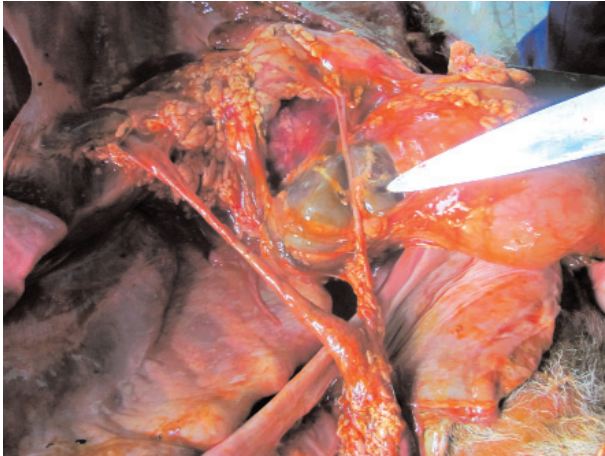


Figure 4. Unilateral aplasia of kidney, ureter and umbilical artery.

compared to the others. Although heredity has been shown to contribute to a number of well documented defects, environmentally induced defects can and do occur in any genotype (Jones, 1999).

Malformation or improper migration of the neural tube during the tail-bud stage, accompanied by partial agenesis of the caudal spinal cord, appears to be the cause of this abnormality (Gentile, 2006). Abnormal development usually occurs when a threshold of genetic and environmental insults is attained and the fetal compensatory mechanisms are overcome. Thus, purely genetic defects can originate from the dam, the sire or both, and environmental teratogens are usually numerous, as are nutritional imbalances, chemicals, drugs, and biotoxins (Rousseaux and Ribble, 1998). However, the accurate etiology of purely genetic defects is still unknown.

The laboratory finding showed that the pH of fluid evacuated from the sac (instead of the bladder) was 6 and contained hemoglobin, WBC, bacteria, a few RBC, oxalate crystalline, and epithelial cells. The collected fluid was found to be urine contaminated with blood and/or the presence of ascending infection in the incomplete urinary system after birth.

To the authors' best knowledge, anal atresia, Cryptorchidism, testicular agenesis (Williams, 1931), unilateral, intestinal malformation, vaginal and uterine malformation (Hirago, 1983), and bilateral renal agenesis (Gurlt, 1832) have been reported in perosomus elumbis cases; however, unilateral umbilical artery agenesis concurrent with all of these abnormalities has not been reported yet.

Acknowledgement

The authors would like to express their sincere gratitude to Mr. Noshahri for his kind assistance.

References

1. Gentile, A., Testoni, S. (2006) Inherited disorders of cattle: A selected review. *Slov Vet Res.* 43: 17-29.
2. Greene, H.J., Leipold, H.W., Huston, K., Noordsy, J.L., Dennis, S.M. (1973) Congenital defects in cattle. *Iran Vet J.* 27: 37-45.
3. Gurlt, E.F. (1832) *Lehrbuch der pathologischen Anatomie der Haus-Säugethiere*, 2. Teil, Atlas. plate IV, no. 1. G. Reimer, Berlin, Germany. p. 88-91.
4. Hirago, T., Abe, M. (1983) A case of perosomus elumbis in a calf. *J Jap Vet Med Assoc.* 36: 277-279.
5. Jones, C.J. (1999) Perosomus elumbis (vertebral agenesis and arthrogryposis) in a stillborn Holstein calf. *Vet Pathol.* 36: 64-70.
6. Noakes, D.E., Parkinson, T.J., England, G.C.W. (2009) *Veterinary Reproduction and Obstetrics*. (9th ed.) Elsevier, Saunders. Edinburg, London, UK.
7. Roberts, S.J. (1986) *Veterinary Obstetrics and Genital Diseases (Theriogenology)*. Roberts, S.J. (ed.). (3rd ed.) Woodstock, Vermont. USA.
8. Rousseaux, C.G., Ribble, C.S. (1998) Developmental anomalies in farm animals. II. Defining etiology. *Can Vet J.* 29: 30-40.
9. Williams, W.L. (1931) Studies in teratology. *Cornell Vet.* 21: 25-53.

گزارش یک مورد گوساله هلشتاین مبتلا به عارضه پروسموس الومبیس همراه با نواقص احشایی

محسن اسلامی^۱ فرامرز قراگزلو^{۲*} پیمان رحیمی فیلی^۳ مهدی وجگانی^۲ سارنگ سروری^۴

(۱) گروه مامایی و طیور، دانشکده دامپزشکی دانشگاه ارومیه، ارومیه، ایران

(۲) گروه مامایی و بیماریهای تولید مثل، دانشکده دامپزشکی دانشگاه تهران، تهران، ایران

(۳) گروه علوم درمانگاهی، دانشکده دامپزشکی دانشگاه رازی، کرمانشاه، ایران

(۴) گروه جراحی و رادیولوژی، دانشکده دامپزشکی دانشگاه تهران، تهران، ایران

(دریافت مقاله: ۱۹ آبان ماه ۱۳۹۲، پذیرش نهایی: ۲ بهمن ماه ۱۳۹۲)

چکیده

پروسموس الومبیس یک نقص مادرزادی با عامل نامشخص می باشد که در گاو، خوک، گوسفند و سگ گاهاً اتفاق می افتد. این نقص مادرزادی در هر دو جنس اتفاق می افتد. یک گوساله هلشتاین مرده که دارای نقص در قسمت های استخوانی و عضلانی سیستم حرکتی و دستگاه تناسلی خارجی بود به بیمارستان دام بزرگ دانشکده دامپزشکی دانشگاه تهران ارجاع داده شد. بررسی عکس های رادیولوژی و کالبدگشایی نشان داد که ستون مهره ها تا مهره اول کمری وجود داشته و مهره های دوم تا پنجم، استخوان خاجی و مهره های دمی وجود نداشتند. قسمت پشتی ناحیه کمری و خاجی فقط از بافت عضلانی و همبند تشکیل شده بود. دستگاه ادراری تناسلی دچار نقصهایی شامل عدم تشکیل تخمدان ها، رحم، واژن و لبه های خارجی فرج بوده، همچنین شریان نافی طرف راست هم وجود نداشت. روده های بزرگ و کوچک دارای ته کیسه های متعدد و مملو از مواد غذایی و مدفوع بودند. بیضه، کیسه بیضه و آلت تناسلی مشاهده نشد. همچنین میزنای به یک کیسه نازک مملو از مایعات اتصال داشت. یافته های آزمایشگاهی نشان دادند که، PH مایع جمع آوری شده ۶ بوده و حاوی هموگلوبین، گلبول های سفید خون، باکتری و تعداد کمی گلبول های قرمز خون، کریستالهای اگزالات و سلول های اپیتلیال بود. به نظر می رسد که مایعات جمع آوری شده همان ادراری می باشد. این اولین گزارش از پروسموس الومبیس در یک گوساله هلشتاین دارای نقص های متعدد در محوطه بطنی در ایران می باشد.

واژه های کلیدی: نقص مادرزادی، گوساله هلشتاین، پروسموس الومبیس، ستون فقرات

* نویسنده مسؤول: تلفن: ۶۱۱۱۷۱۶۴ (۲۱) ۹۸+ نمابر: ۶۶۹۳۳۲۲۲ (۲۱) ۹۸+ Email: faramarz@ut.ac.ir