

Comparative Study of Micro Ostrich Eggshell and Hydroxyapatite on the Healing of Bone Defect Created in the Rat Calvarium

Sara Habibnezhad Arabi¹, Hamid Reza Moslemi^{1*}, Sahar Ghafari Khaligh²

¹ Department of Clinical Sciences, Faculty of Veterinary Medicine, Semnan University, Semnan, Iran

² Department of Pathobiology, Faculty of Veterinary Medicine, Semnan University, Semnan, Iran

Abstract

BACKGROUND: Fracture healing is one of the important issues in medicine and veterinary. Therefore, finding new techniques with fewer side effects and faster healing is taken into consideration.

OBJECTIVES: This study was conducted to evaluate the effect of the composites of micro ostrich eggshell (μ -OES) and hydroxyapatite (HA) composite on the healing of bone defect in rat calvarium.

METHODS: Defects of 7 mm were made by a trephine in the calvaria of 45 male Wistar rats. The animals were divided into three groups and the defects in each group were filled with micro-composites that contained ostrich eggshell or HA or were left empty. The animals were euthanized at three different time points of 14, 28, and 42 days post-operation. Histological and serological assessments, such as measuring alkaline phosphatase were carried out at the same time points.

RESULTS: Significant differences were observed in the granulation tissue formation of the treatment and control groups 14 days post-operation ($P \leq 0.05$). The difference between μ -OES and HA treatment groups was not statistically significant ($P > 0.05$). On days 28 and 42, there were no significant differences between the groups. However, in the center of the defect, the mean of healing in the μ -OES group was higher than the two other groups.

CONCLUSIONS: In conclusion, the results of this study indicated the potential efficacy of μ -OES as a bone substitute in a rat calvarial defect model.

KEYWORDS: Calvarium, Hydroxyapatite, Histopathology, Micro ostrich eggshell, Rat

Correspondence

Hamid Reza Moslemi, Department of Clinical Sciences, Faculty of Veterinary Medicine, Semnan University, Semnan, Iran

Tel: +98 (023) 33654214, Fax: +98 (023) 33654215, Email: h.moslemi@semnan.ac.ir

Received: 2020-08-22

Accepted: 2020-12-15

Copyright © 2021. This is an open-access article distributed under the terms of the Creative Commons Attribution- 4.0 International License which permits Share, copy and redistribution of the material in any medium or format or adapt, remix, transform, and build upon the material for any purpose, even commercially.

How to Cite This Article

Habibnezhad Arabi, S., Moslemi, H., Ghafari Khaligh, S., A. (2021). Comparative Study of Micro Ostrich Eggshell and Hydroxyapatite on the Healing of Bone Defect Created in the Rat Calvarium. *Iranian Journal of Veterinary Medicine*, 15(1), 16-26.

Introduction

Bone defect and functional problems have turned into a critical worldwide health and hygiene issue (Grote, Reinhardt, Zhang & Wang, 2019; Van Der Spoel, Van Vliet & Van Heemst, 2019). Moreover, bone restoration is a complex process in closed and compound fractures that involve a bone-tissue loss of more than 3 cm. In comminuted fractures with more than 6 cm of tissue loss, the chances of deformity, shortening, recurrence of fractures due to non-union, and deformity resulting from malunion or asymmetric healing increase significantly (Mitchel, Keating & Robinson, 2010). At the same time, complications spawning from the application of conventional methods have advocated a strong shift towards developing three-dimensional (3D) scaffolds from regenerated biomaterials. The 3D scaffolds from regenerated biomaterials reduce the possibility of nonunion or asymmetric healing by improving cell delivery, elevating cellular support on fracture edges, and enhancing growth and regeneration in the fracture region.

In bone-tissue engineering, scaffold structures must be porous and of a composition purely identical to the bone HA provides stronger and more rapid bone tissue repair and can be considered as a preferable alternative to conventional bone grafting techniques (Angelin Jeba Kala & Asaithambi, 2018; Oberbek *et al.*, 2018).

Avian eggshell, with mineral constituents highly resembling those of marine sponge, has found its way in orthognathic surgery as a potential bone-replacement material. Consequently, in recent years, extensive research has been conducted to improve the functioning power of HA. More recently, several reports have recommended the incorporation of hen or other avian eggshells in microparticle form on local delivery or hydrothermal basis with or without other bone grafting materials. Nevertheless, the findings

were contradictory in terms of the quantity and quality of the bone generated (Srisubut *et al.*, 2007; Lozano-Carrascal *et al.*, 2017).

Dupoirieux *et al.* (2000) compared pericranium and eggshell as void fillers in the guided repair of bones and reported no sign of bone repair in any of the groups in the first 15 days. On day 30, they observed bone regeneration solely in the control group that had received no void filler. On day 90, complete bone regeneration occurred in 3-5 of the cases in the control group. There was no indication of osteogenic activity in the pericranium group, while in the third group, non-resorbable hen eggshell powder failed to express osteoconductive characteristics. In another investigation, Yadao *et al.* (2004) used ostrich eggshell as an implant and bone replacement graft to treat bone fracture on the floor of rabbit's orbit. They reported positive effects of this material on the healing process. Yadegari *et al.* (2015) based their study on the radiographic examination of the efficacy of hen eggshell powder on the healing of defected tibia bone in dogs. They reported an increase in bone density on days 30 and 60 that was associated with this material. Alternately, Park *et al.* (2008) assessed the bone repair process in rat calvaria using hen eggshell and compared the results with allograft transplantation in a cow. Findings underlined the potential characteristic of hen eggshell particles as a bone graft in the treatment of rat calvarial defect. Abdulrahman *et al.* (2014) perceived the high generating potential of HA and demonstrated how HA extraction from eggshell would prove to be cost-effective in terms of bone-repair costs. This is due to the low costs of extracting calcium carbonate from avian eggshell, its high accessibility, and its biodegradable nature as a primary material for bone grafting. Nevertheless, none of the studies specifically quantified the effect of these particles on improved local bone regeneration.

The natural bone matrix is made of bio-ceramics (i.e. HA) and polymers (i.e. collagen). Consequently, obtaining natural and synthetic

biomaterials in the form of natural and synthetic polymers, compounds, and biological ceramic substances to produce bone scaffolds seems to be possible. Preparation of porous nano- and micro-fibers is amongst the most recent procedures (Rezwan *et al.*, 2006). The effectiveness of tissue scaffolds has rendered μ -OES scaffolds worthy of consideration in improving bone healing. Exploring methods to accelerate healing is a crucial demand. With this background in mind, the present study experimentally investigated rat calvarial bone, while comparing the efficacy of μ -OES scaffolds and HA scaffolds in accelerating bone tissue repair.

Materials and Methods

Animals

Forty-five male Wistar rats weighing 250-300 g were used in this study. The rats were housed for two weeks at the facility for acclimatization. All animals were housed individually in light- and temperature-controlled facilities and were fed pellets specifically prepared for laboratory animals. In addition, these rats had free access to water during the study. This study was approved by the Ethics Committee of the School of Veterinary Medicine, Semnan University (approval no. 43-17/7/96).

Surgical Procedure

The μ -OES composite was prepared according to the method described by Sanosh *et al.* in 2009 (6). The rats were anaesthetized intraperitoneally with 50 mg/kg of 10% ketamine hydrochloride (0.05 mL/100 g) and 5 mg/kg xylazine hydrochloride (0.025 mL/100 g).

The dorsal part of the cranium was shaved and disinfected. Surgical sites were exposed with a skin incision and the periosteum at the midline of the calvaria. After the calvarium was exposed, a 7 mm circular full-thickness bone defect was created using a trephine bur on the midline without damaging the underlying dura mater (Figure 1). All calvarial defects were trephined under irrigation with 0.9% saline

solution. The animals were randomly divided into three groups with 15 animals per group for experimental periods of 14, 28, and 42 days.

In the HA and μ -OES groups, the defects were filled with HA and micro-particles of ostrich eggshell, respectively. The rats in the control group received no HA or μ -OES therapy. The soft tissues were sutured with 4-0 monofilament nylon to achieve primary closure. To prevent postoperative infection, cefazoline was administered to the animals as intramuscular injections for 3 days (30 mg/kg). Flunixin (Razak Co. Iran) as an analgesic was injected (2.5 mg/kg) intramuscularly.

Specimen Preparation and Histological Evaluation

Animals were euthanized with a lethal dose of thiopental (150 mg/kg), at post-operative periods of 14, 28, and 42 days. The skin was dissected and the area of the original surgical defect was removed en bloc with the surrounding tissues from the animals' calvarium bone and was immediately submerged in 10% neutral buffered formalin for 48 h. Afterwards, it was rinsed with water and demineralized in 10% formic acid. Following decalcification, each specimen was divided longitudinally into two blocks in the sagittal direction and the blocks were embedded in paraffin. Serial sections were cut longitudinally beginning at the center of the surgical defect. The sections were stained with hematoxylin and eosin for analysis. In the histopathologic evaluation, the progression of bone defect healing was investigated in three regions, including two edges and the center of the defect in each sample. The levels of granulation tissue formation, fibrosis tissue, immature bone tissue, and adult ossification were evaluated to obtain healing rates in different samples. For each sample, three slides were prepared and each slide was investigated by two pathologists who were blind about the samples. Two edges and the central region of calvarial slides were studied by $\times 100$

magnification of light microscope in three different fields for each region. Bone healing was

scored according to Allen's grading system (Deniza *et al.*, 2015).

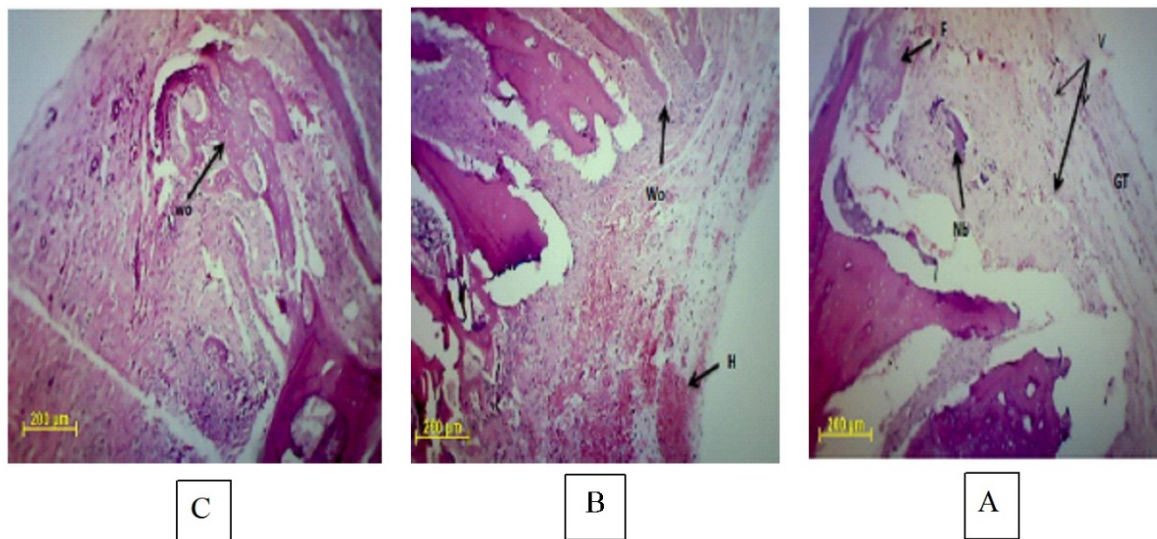


Figure 1. Photomicrograph of all groups at day 14 post operation. A: in the control group, a granulation tissue that is accompanied with fresh vascularization, edema, and bone-matrix formation, develops on the edge of defect. B: in the HA group, the immature bone tissue was seen. C: a slight immature-bone formation occurs on the μ -OES group μ -OES: Micro ostrich eggshell, HA: Hydroxyapatite, Co: Control, Wo: Woven, L: Lamellar, H: Hematoma, NB: new bone ossification, V: Vessel, GT: granular tissue, F: Fibrous (H&E, $\times 100$).

Measurement of Alkaline Phosphatase Activity

Blood samples were taken from the heart of animals 14, 28, and 42 days post-operation, as well as before euthanasia. After separating serum, alkaline phosphatase (ALP) activity was assessed using a colorimetric ALP activity assay kit (Pars Azmun, Iran).

Statistical Analysis

Statistical analysis was performed by the Kruskal-Wallis test using the SPSS software version 16 (SPSS Inc, Chicago, Ill., USA). Descriptive statistics of the data are expressed as mean \pm standard deviation (SD). Differences were considered significant when P -value < 0.05 .

Results

[Table 1](#) presents the results of histopathological studies. Based on the results of day 14, a significant difference was observed in the edge and center of the defect between the two experimental groups, compared to the control group ($P \leq 0.05$). However, the difference between the two test groups was not significant in this regard. In the control group, a granulation tissue accompanied by fresh vascularization, edema, and bone matrix formation developed on the edge of the defect. In the HA group, contrary to the control group, a slight immature bone formation occurred on the same day in the same area. A similar pattern was observed on a larger scale in the μ -OES group ([Figure 1](#)).

Table 1. The Mean ± SD of the histopathological changes in all groups.

Days	Defect site	μ-OES	HA	Control
14	Margins	8 ± 1.78 ^a	9.8 ± 0/45 ^a	4.75 ± 2.87 ^b
	Center	6 ± 2.19 ^a	6.8 ± 0.83 ^a	2.66 ± 1.15 ^b
28	Margins	7.5 ± 1.3	8.75 ± 0.95	7.8 ± 0.83
	Center	5.25 ± 0.95	4.25 ± 1.26	4 ± 2.34
42	Margins	9.2 ± 0.83	9.2 ± 0.83	9 ± 0.54
	Center	7 ± 0.7	6.4 ± 1.13	6.2 ± 1

There was no significant difference between the same letters in each row, but significant difference was observed between the non-identical letters.

μ-OES: Micro ostrich eggshell, HA: hydroxyapatite.

On day 28, no significant difference was observed in the edge and center of the defect in either group. At this time, bone matrix and immature bone formation persisted in the control group. In the HA group, bone matrix formation was distinguishable from the immature bone formation as the bone regeneration continued.

At the same time, in the μ-OES group, bone regeneration and the formation of parallel arrays of mature lamellar bone were observed. In this group, in the center of bone defect, the granulation tissue advanced towards fibrosis on day 14. Bone matrix deposition on day 28 became distinct, compared to the other two groups (Figure 2).

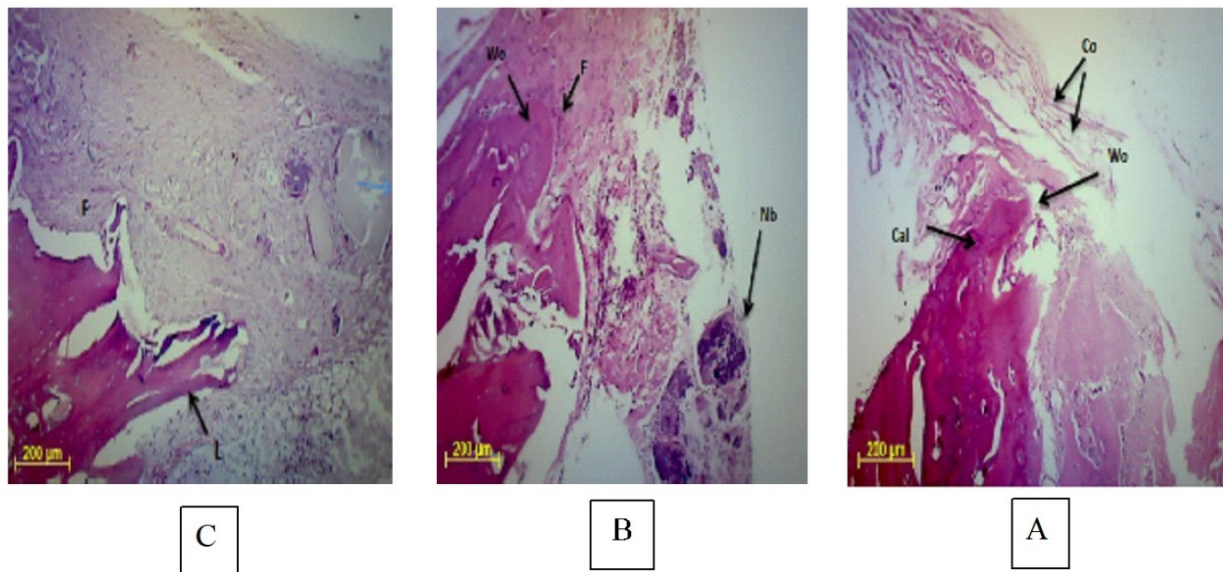


Figure 2. Photomicrograph of all groups at day 28 post operation. A: The bone-matrix and immature-bone formation persisted in the control group. B: In the HA group, bone-matrix formation was distinguishable from immature-bone formation as the bone regeneration continued. C: in the μ-OES group, bone regeneration and formation of parallel arrays of mature lamellar bone pursued.

μ-OES: Micro ostrich eggshell, HA: Hydroxyapatite, Co: Control, Wo: Woven, L: Lamellar, H: Hematoma, NB: new bone ossification, V: Vessel, GT: granular tissue, F: Fibrous (H&E, ×100).

On day 42, no other significant difference was revealed in the edge and center of the defect in

either group. In the control group, repair progress towards dense fibrosis was accompanied

by the formation of thick collagen fibers. In addition to immature bone tissue, trace mature parallel bone was distinguished on the edge of the defect. On the edge of the defect in the HA group, immature bone completely regenerated and the extent of development of mature parallel bone arrays on this day exceeded that of the

control group. As for the μ -OES group, the formation of parallel arrays of bone tissue was observed and reported. In the center of the defect, progress from fibrous tissue to the deposition of underlying bone material and formation of new immature bone was significantly greater in the μ -OES group, compared to the other two groups (Figure 3).

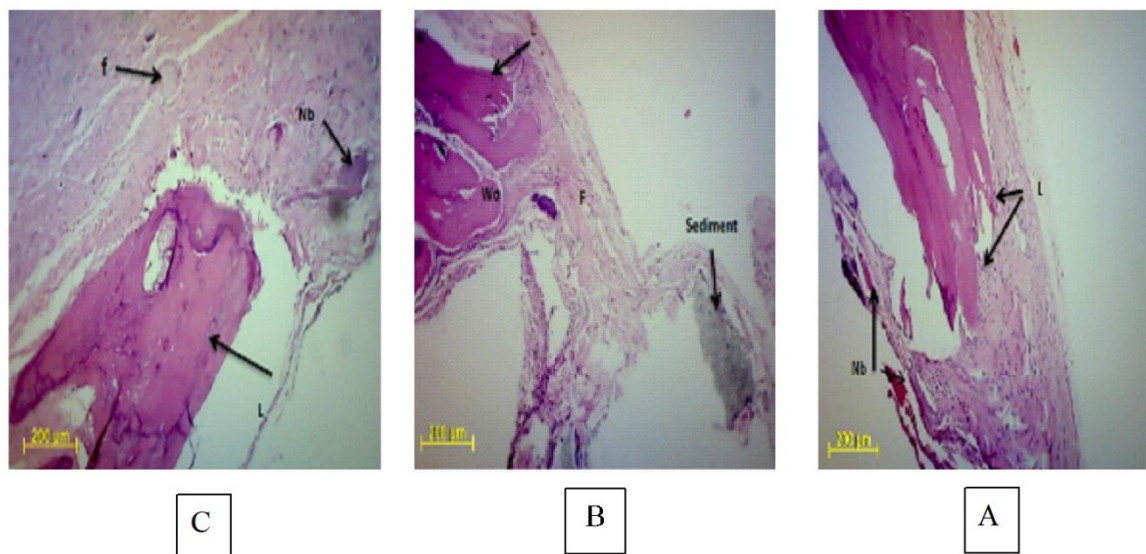


Figure 3. Photomicrograph of all groups at day 42 post operation. A: The progression of defect healing was seen towards dense fibrosis along with thickened collagen fibers and a small amount of lamellar mature bone in the control group. B: In the HA group, the immature and irregular bone was formed on the edge of defect; and the parallel and blade mature bone formation was seen. C: In the N-OES group, both edges of defect site were reaching together by a new bone tissue.

μ -OES: Micro ostrich eggshell, HA: Hydroxyapatite, Co: Control, Wo: Woven, L: Lamellar, H: Hematoma, NB: new bone ossification, V: Vessel, GT: granular tissue, F: Fibrous (H&E, $\times 100$).

In terms of ALP activity, the results of the present study indicated that the applied treatments increased the serum levels of ALP indicating an improvement in healing trends in the tested groups. A reduction was reported exclusively in

the HA group on day 28, in comparison with day 14. This difference was not significant and could be due to a type II statistical error, small sample size, and higher standard deviation in the data of this group (Table 2).

Table 2. The Mean \pm SD of the ALP changes in all groups.

Days	μ -OES	HA	Control
14	543.04 \pm 51.68	545.01 \pm 51.84	304.74 \pm 10.64
28	537.15 \pm 58.36	467.43 \pm 116.98	380.23 \pm 57.25
42	536.17 \pm 36.8	515.56 \pm 77.74	413.42 \pm 103.36

μ -OES: Micro ostrich eggshell, HA: hydroxyapatite

Discussion

As a vital body tissue, bone can frequently self-heal after traumatic injuries. However, this might not apply to severe traumas. Bone regeneration requires great contemplation with regards to the extensive presence of varying bone diseases, including bone infections, bone tumors, and traumatic bone losses.

Bone defects have multiple causes and create serious social, economic, and medical problems for society. Treatment of bone defects using mixed techniques has been a concern for a long time. Bone grafting and filling techniques for recovering the shape and function of the lost bone face some limitations, such as bone graft rejection, limiting factors, increased surgery time, infection, pain, and possible mortality. On the other hand, the use of metal implants to repair bone defects is accompanied by the release and accumulation of lethal ions in different parts of the body that elevates the risk of cancer. Furthermore, the components of recent commercially manufactured materials and products are relatively costly. For this reason, researchers are showing increased concern for discovering alternative material and approaches, namely biodegradable biomaterials and tissue engineering to address these issues (Sharma, Mujawar & Kaushik, 2019).

Numerous structural and chemical similarities of HA and its calcium phosphate ceramic derivatives with the bone phase have made HA a priority to be considered as a major alternative for hard-tissue repair (Pushpakanth *et al.*, 2008).

In the course of this study, the edge and center of the defect were examined histopathologically on days 14, 28, and 42 post-surgery. On day 14, the extent of healing in these two regions for HA and μ -OES groups was significantly higher than the control group. However, the extent of healing was not significantly different between the two intervention groups. At the same time, on

days 28 and 42, despite the absence of a significant difference in the extent of healing between the three study groups, the mean extent of healing in the center of the defect in the μ -OES group exceeded that of the HA and control groups. The latter finding can well signify the effectiveness of μ -OES on the extent of healing. Over time, the extent of healing in this group exceeded that of the HA and control groups. The lack of significant difference in the extent of healing between the three groups on these two days could be attributed to type II statistical error, small sample size, and/or the high standard deviation of data. On the other hand, the difference between the two test groups could result from the unique origins of these substances and their particle size.

Several studies showed that HA powder extracted from avian eggshell may be of higher tissue-friendly value with a more prominent bone generation-stimulating effect and minimize inflammatory reaction and infection. On the other hand, the synthetic HA derivatives that are principally made of marine products and sponges impose a lower healing effect (Dupoirieux, Pourquier & Souyris, 1995; Aroni, *et al.*, 2019).

Lee *et al.* (2014) compared the influences of eggshell-derived HA with that extracted from marine products on the healing progress of parietal bone in rats. According to their findings, the extent of healing in both intervention groups was larger than control with the extent of bone formation in the eggshell-derived HA group exceeding that of marine-extracted HA. The latter result is in line with the histopathological findings of the present study. Moreover, they discovered eggshell-derived HA to contain a higher level of magnesium (Mg) than the HA extracted from marine products. This could be considered as an additional factor adding to the efficacy of eggshell-derived HA on the process

of bone healing. Several studies have demonstrated the relation of Mg with bone metabolism and bone regeneration (Gauthier, Bouler & Weiss, 1999; Witte, Ulrich & Rudert, 2007). Crespi *et al.* (2012) investigated the impacts of applying Mg-enriched HA implants on tibia bone defects in pigs and demonstrated the greater impact of these Mg-rich bone implants on bone regeneration, compared to other groups.

Grigolato *et al.* (2015) used Mg-enriched HA as bone filler for a 63-year old male patient with ameloblastoma in the lower jaw. They monitored the course of treatment and discovered a higher degree of tissue adaptation and bone integrity in the patient jaw.

In addition, particle size is considered a determining factor in the rate of absorption of these materials (Hench, 1991). In this study, the used ostrich eggshell particles were of micro-scale, while the size of HA particles was 1-5 mm. Therefore, the difference in the healing progress may result from the difference in size.

Our results revealed that the treatments applied in this study increased the level of serum ALP, which could be considered as an additional cause of improved healing. Reduced ALP level was solely recorded in the HA group and only on day 28, compared to day 14. However, this was not statistically significant, which

might be due to type II statistical error, small sample size, and/or the high standard deviation of data.

Findings of the present investigation suggested that the specific enzymes and proteins released in blood in the course of bone regeneration reflect the activity of bone-forming cells known as "osteoblasts" and the strength and stability of the callus formed during repair (Shetty *et al.*, 2016; Kuo & Chen, 2017). The ALP, as the most accurate bone-synthesized serum marker, is involved in the hydrolysis of phosphomonoesters and release of mineral phosphate, which has a major role in bone mineralization. Bone mineralization augments significantly after injury (Muljadic *et al.*, 2013; Yoon & Yu, 2018).

Acknowledgments

This study was financially supported by the Research Council of Veterinary Faculty Semnan University, Semnan, Iran.

Conflict of Interest

The authors declared no conflict of interest.

References

- Abdulrahman, I., Tijani, H. I., Mohammed, B. A., Saidu, H., Yusuf, H., Jibrin, M. N., & Mohammed, S. (2014). From garbage to biomaterials: an overview on egg shell based hydroxyapatite. *J Mater*, 2014, 802467. [DOI:10.1155/2014/802467]
- Angelin Jeba Kala, B., Asaithambi, T. (2018). Preparation and characterization of precipitated nano hydroxyapatite. *Aust J Basic Appl Sci*, 12(2), 10-14.
- Aroni, M., Costa Neto, P., Oliveira, G., Marcantonio, R., Marcantonio Junior, E. (2019). Bone repair induced by different bone graft substitutes in critical-sized defects in rat calvaria. *Rev Odontol UNESP*, 48, 1-11. [DOI:10.1590/1807-2577.04119]
- Crespi, R., Cappare, P., Addis, A., & Gherlone, E. (2012). Injectable magnesium-enriched hydroxyapatite putty in peri-implant defects: a histomorphometric analysis in pigs. *Int J Oral Maxillofac Implant*, 27(1). [PMID]

- Deniza E, Arslana A, Dikerb N, Olgac V, Kilic E. (2015). Evaluation of light-emitting diode photobiomodulation on bone healing of rat calvarial defects. *Biotechnol Biotechnol Equip*, 29(4), 758-765. [DOI:10.1080/13102818.2015.1036774]
- Daneshvar, N., Salari, D., & Khataee, A. R. (2004). Photocatalytic degradation of azo dye acid red 14 in water on ZnO as an alternative catalyst to TiO₂. *Journal of photochemistry and photobiology A: chemistry*, 162(2-3), 317-322. [DOI:10.1016/S1010-6030(03)00378-2]
- Dupoirieux, L., Neves, M., Pourquier, D. (2000). Comparison of pericranium and eggshell as space fillers used in combination with guided bone regeneration: an experimental study. *J Oral Maxillofac Surg*, 58(1), 40-46. [DOI:10.1016/S0278-2391(00)80013-0]
- Gauthier, O., Bouler, J. M., Weiss, P. (1999). Short-term effects of mineral particle sizes on cellular degradation activity after implantation of injectable calcium phosphate biomaterials and the consequences for bone substitution. *Bone*, 25(2), 71S-74S. [DOI:10.1016/S8756-3282(99)00137-4]
- Grigolato, R., Pizzi, N., Brotto, M., Corrocher, G., Desando, G., Grigolo, B. (2015). Magnesium-enriched hydroxyapatite as bone filler in an ameloblastoma mandibular defect. *Int J Clin Exp Med*, 8(1), 281-288.
- Grote, C., Reinhardt, D., Zhang, M., Wang, J. (2019). Regulatory mechanisms and clinical manifestations of musculoskeletal aging. *J Orthop Res*, 37(7), 1475-1488. [PMID] [DOI:10.1002/jor.24292]
- Hench, L. L. (1991). Bioceramics: From concept to clinic. *J Am Ceram Soc*, 74(7), 1487-1510.
- Kuo, T., Chen, C. (2017). Bone biomarker for the clinical assessment of osteoporosis: recent developments and future perspectives. *Biomark Res*, 5(18), 1-9. [DOI:10.1186/s40364-017-0097-4] [PMID] [PMCID]
- Lee, S.W., Balazsi, C., Balazsi, K., Seo, D., Kim, H.S., Kim, C.H., Kim, S.G. (2014). Comparative Study of Hydroxyapatite Prepared from Seashells and Eggshells as a Bone Graft Material. *Tissue Eng Regen Med*, 11(2), 113-120. [DOI:10.1007/s13770-014-0056-1]
- Lozano-Carrascal, N., Salomo-Coll, O., Hernandez-Alfaro, F., Gehrke, S., Gargallo-Albiol, J., Calvo-Guirado, J. (2017). Review Do topical applications of bisphosphonates improve bone formation in oral implantology? A systematic review. *Med Oral Patol Oral Cir Bucal*, 22(4), 512-519. [DOI:10.4317/medoral.21887] [PMID] [PMCID]
- Mitchel, S. E., Keating, J. F., Robinson, C. M. (2010). The treatment of open femoral fractures with bone loss. *J Bone Joint Surg Br*, 92(12), 1678-1684. [DOI:10.1302/0301-620X.92B12.25190] [PMID]
- Muljagic, A., Poljak-Guberina, R., Zivkovic, O., Bilic, V., Guberina, M., Crvenkovic, D. (2013). Course and rate of post-fracture bone healing in correlation with bone-specific alkaline phosphatase and bone callus formation. *Coll Antropol*, 37(4), 1275-1283.
- Oberbek, P., Bolek, T., Chlanda, A., Hirano, S., Kusnieruk, S., Rogowska-Tylman, J., Nechyporenko, G., Zinchenko, V., Swieszkowski, W., Puzyn, T. (2018). Characterization and influence of hydroxyapatite nanopowders on living cells. *Beilstein J Nanotechnol*, 9, 3079-3094. [DOI:10.3762/bjnano.9.286] [PMID] [PMCID]
- Park, J. W., Bae, S. R., Suh, J. Y., Lee, D. H., Kim, S. H., Kim, H. (2008). Evaluation of bone healing with eggshell-derived bone graft substitutes in rat calvaria: A pilot study. *J Biomed Mater Res A*, 87(1), 203-214. [DOI:10.1002/jbm.a.31768] [PMID]
- Pushpakanth, S., Srinivasan, B., Sreedhar, B., Sastry, T. P. (2008). An in situ approach to prepare nanorods of titania-hydroxyapatite (TiO₂-HAp) nanocomposite by microwave hydrothermal technique. *Mater Chem Physics*, 107, 492-498. [DOI:10.1016/j.matchemphys.2007.08.029]
- Rezwan, K., Chen, Q. Z., Blaker, J. J., Boccaccini, A. R. (2006). Biodegradable and bioactive porous polymer/inorganic composite scaffolds for bone tissue engineering. *Biomaterials*, 27(18), 3413-3431. [DOI:10.1016/j.biomaterials.2006.01.039] [PMID]

- Sharma, K., Mujawar, M., Kaushik, A. (2019). State-of-Art Functional Biomaterials for Tissue Engineering. *Front Mater*, 6(172), 1-10. [DOI:10.3389/fmats.2019.00172]
- Shetty, S., Kapoor, N., Bondu, J., Thomas, N., Vizhalil Paul, T. (2016). Bone turnover markers: Emerging tool in the management of osteoporosis. *Indian J Endocrinol Metabol*, 20(6), 846-852. [DOI:10.4103/2230-8210.192914] [PMID] [PMCID]
- Srisubut, S., Teerakapong, A., Vattraphodes, T., Taweechaisupapong, S. (2007). Effect of local delivery of alendronate on bone formation in bioactive glass grafting in rats. *Oral Surg Oral Med Oral Pathol Oral Radiol Endod*, 104(4), 11-16. [DOI:10.1016/j.tripleo.2007.04.022] [PMID]
- Van Der Spoel, E., Van Vliet, N. A., Van Heemst, D. (2019). Viewpoint on the role of tissue maintenance in aging: focus on biomarkers of bone, cartilage, muscle, and brain tissue maintenance. *Ageing Res Rev*, 56, 100964. [DOI:10.1016/j.arr.2019.100964] [PMID]
- Witte, F., Ulrich, H., Rudert, M., & Willbold, E. (2007). Biodegradable magnesium scaffolds: Part 1: appropriate inflammatory response. *Journal of biomedical materials research Part A*, 81(3), 748-756. [DOI:10.1002/jbm.a.31170] [PMID]
- Yadao, R., Lim, G., Pe, L., Valdez, A., Cristobal, S., Sunico, A., Romero, H. (2004). Ostrich eggshell as an onlay bone-graft substitute for orbital blow-out fractures. *Philipp J Ophthalmol*, 29(3), 127-130.
- Yadegari, M., Karimi, M., Sheishi, P., Derakhshan, S. (2015). A radiographic survey of eggshell powder effect on tibial bone defect repair tested in dog. *HVM Bioflux*, 7(4), 392-396.
- Yoon, B., Yu, W. (2018). Clinical Utility of Biochemical Marker of Bone Turnover: Fracture Risk Prediction and Bone Healing. *J Bone Metabol*, 25, 73-78. [DOI:10.11005/jbm.2018.25.2.73] [PMID] [PMCID]

مقایسه تاثیر میکرو ذرات پوسته تخم شترمرغ و هیدروکسی آپاتیت بر التیام نقیصه استخوانی ایجاد شده در کالواریوم رت

سارا حبیب نژاد عربی^۱، حمید رضا مسلمی^{۱*}، سحر غفاری خلیق^۲

^۱ گروه علوم درمانگاهی، دانشکده دامپزشکی دانشگاه سمنان، دانشگاه سمنان، سمنان، ایران

^۲ گروه پاتوبیولوژی، دانشکده دامپزشکی دانشگاه سمنان، دانشگاه سمنان، سمنان، ایران

(دریافت مقاله: ۱۰ شهریور ماه ۱۳۹۹، پذیرش نهایی: ۲۵ آذر ماه ۱۳۹۹)

زمینه مطالعه: درمان شکستگی یکی از مباحث مهم و مورد توجه در علم پزشکی و دامپزشکی است و همواره یافتن یک تکنیک جدید که بتواند حداقل عوارض جانبی را داشته باشد و سرعت التیام شکستگی را افزایش دهد، مورد توجه بوده است.

هدف: در این تحقیق با مطالعه تجربی روی استخوان کالواریوم رت میزان تاثیر میکروپوسته تخم شترمرغ و مقایسه آن با هیدروکسی آپاتیت در تسریع روند ترمیم استخوان ارزیابی شد.

روش کار: تعداد ۴۵ قطعه رت از نژاد ویستار انتخاب و با استفاده از ترفاین به قطر هفت میلی متر، یک حفره روی استخوان کالواریوم ایجاد گردید. سپس رت‌ها به سه گروه تقسیم شدند. در گروه اول، حفرات با میکروپوسته تخم شترمرغ و در گروه دوم با هیدروکسی آپاتیت پر شد. در گروه سوم به عنوان کنترل از هیچ درمانی استفاده نشد. حیوانات در روزهای ۱۴، ۲۸ و ۴۲ بعد از جراحی به روش انسانی آرام‌کشی شدند. ارزیابی‌های هیستولوژی و سرولوژی (ALP) در روزهای مورد مطالعه انجام گرفت.

نتایج: بر اساس یافته‌های به دست آمده در روز ۱۴، میزان التیام در دو گروه درمانی نسبت به گروه کنترل به طور معناداری بالاتر بود ($P \leq 0.05$). در حالی که در این روز میزان التیام بین دو گروه میکروپوسته تخم شترمرغ و هیدروکسی آپاتیت اختلاف معنی داری را نشان نداد ($P > 0.05$). در روزهای ۲۸ و ۴۲ بعد از جراحی، میزان التیام در گروه‌های مورد مطالعه اختلاف معنی داری نداشت ولی میانگین میزان التیام در مرکز ضایعه در گروه میکروپوسته تخم شترمرغ نسبت به دو گروه هیدروکسی آپاتیت و کنترل بالاتر بود.

نتیجه‌گیری نهایی: بنابراین مشخص گردید که به کارگیری میکرو پوسته تخم شترمرغ می‌تواند روند التیام را در نقیصه ایجاد شده در استخوان کالواریوم رت بهبود بخشد.

واژه‌های کلیدی: کالواریوم، هیدروکسی آپاتیت، هیستوپاتولوژی، میکروپوسته تخم شترمرغ، رت