

Evaluation of Serum Alkaline Phosphatase Changes and TGF- β Expression in the Liver of Cholestatic Rats Treated with Ethanolic Extract of *Plantago Ovata*

Maede Rafiee¹, Pejman Mortazavi^{2*}, Ahmad Asghari³

¹ Graduated from the Faculty of Veterinary Medicine, Science and Research Branch, Islamic Azad University, Tehran, Iran

² Department of Pathobiology, Faculty of Veterinary Medicine, Science and Research Branch, Islamic Azad University, Tehran, Iran

³ Department of Clinical Sciences, Faculty of Veterinary Medicine, Science and Research Branch, Islamic Azad University, Tehran, Iran

Abstract

BACKGROUND: Induction of cholestasis is one of the methods of liver fibrosis which causes the development of oxidative stress, increased expression of fibrogenic markers, excessive deposition of extracellular matrix, and finally the incidence of fibrosis. *Plantago ovata* is known as a rich source of various secondary metabolites such as phenolic compounds, flavonoids, alkaloids, trypanoids, and ascorbic acid.

OBJECTIVES: the present study, the expression of TGF- β as a fibrotic marker and serum alkaline phosphatase (ALP) changes in cholestatic rats treated with *P. ovata* extract were evaluated.

METHODS: In this study, 48 adult Wistar rats were used. The rats were randomly divided into eight groups of six animals each as follows: (1) healthy control group without bile duct ligation (BDL) surgery and treatment; (2–4) three healthy experimental plus *P. ovata* groups: rats without BDL, treated with *P. ovata* at dose levels of 100, 200, and 400 mg/kg body weight, respectively; (5) the BDL group: rats with BDL and treated with distilled water; and (6–8) the BDL plus *P. ovata* groups: rats with BDL and treated with *P. ovata* at dose levels of 100, 200, and 400 mg/kg body weight, respectively. The rats were treated with *P. ovata* extract for 45 consecutive days (once per day). After euthanasia and serum isolation, ALP enzyme level was measured. Moreover, the rat liver was fixed in 10% formalin buffer solution. The immunohistochemical study was performed by TGF- β antibody. Data analysis was performed using the One-way ANOVA and Kruskal-Wallis test and the Prism statistical program ($P < 0.0001$).

RESULTS: The results showed a significant increase in the serum levels of ALP enzyme and TGF- β expression in BDL group. Treatment with *P. ovata* extract was able to significantly improve these changes in a dose-dependent manner.

CONCLUSIONS: The results of this study showed that *P. ovata* extract probably due to its phenolic compounds and its antioxidant effect has a protective effect on the liver and subsequently improves the increased serum ALP level and also reduced TGF- β expression.

KEYWORDS: Alkaline phosphatase, Cholestasis, *Plantago ovata*, Rats, TGF- β

Correspondence

Pejman Mortazavi, Department of Pathobiology, Faculty of Veterinary Medicine, Science and Research Branch, Islamic Azad University, Tehran, Iran Tel: +98 (021) 44865119, Fax: +98 (021) 44865121, Email: spmortazavi@srbiau.ac.ir

Received: 2020-11-01

Accepted: 2021-02-03

Copyright © 2021. This is an open-access article distributed under the terms of the Creative Commons Attribution- 4.0 International License which permits Share, copy and redistribution of the material in any medium or format or adapt, remix, transform, and build upon the material for any purpose, even commercially.

How to Cite This Article

Rafiee, M., Mortazavi, P., Asghari, A. (2021). Evaluation of Serum Alkaline Phosphatase Changes and TGF- β Expression in the Liver of Cholestatic Rats Treated with Ethanolic Extract of *Plantago Ovata*. *Iranian Journal of Veterinary Medicine*, 15(3), 358-368.

Introduction

Cholestasis refers to the inhibition of bile flow, which leads to the retention of all bile elements in the blood, and if left untreated, leads to liver fibrosis and eventually cirrhosis (Tomur *et al.*, 2011).

Bile duct ligation (BDL) is a model for the induction of cholestasis in laboratory animals that induces cholestasis in rats with greater intensity and less mortality than other methods (Tag *et al.*, 2015).

Fibrosis is characterized by the excessive accumulation of extracellular matrix in the damaged tissue, which often leads to the destruction of its natural architecture and dysfunction of organs (Biernacka *et al.*, 2011).

BDL causes increased bile pressure, mild inflammation, and secretion of cytokines from bile epithelial cells, leading to the increased expression of fibrogenic markers including Transforming Growth Factor- β (TGF- β), α -Smooth Muscle Actin (α -SMA), collagen 1, Reactive Oxygen Species (ROS), and eventually liver damage (Yanguas *et al.*, 2016). In other words, cholestasis promotes oxidative stress in the liver, and antioxidants are compounds that protect biological tissues against free radicals (Chen *et al.*, 2009).

Hepatic enzymes can be broadly divided into two categories: hepatocellular leakage enzymes and induced (or cholestatic) enzymes. Liver induced enzymes include alkaline phosphatase (ALP) with a lifespan of 3 days and various isoenzymes that act in alkaline environments, mainly in hepatocytes and bile duct epithelial cells. ALP is typically membrane-bound. Increased serum ALP activity is the result of enzyme induction usually due to cholestasis, drugs, or typically as a result of cholestasis, drug, or hormonal effects. Intrahepatic or extrahepatic cholestasis causes a marked increase in ALP activity, which is predominately a hepatic isoenzyme. In cholestatic syndrome, bile acid retention in the liver is likely to induce ALP synthesis at the translational level. Increased ALP activity is a sensitive indicator of cholestasis (Latimer, 2011).

Stellate cells (fibroblastic cells) are the main cells in the process of fibrogenesis of liver tissue. TGF- β is an important regulator of the phenotype and function of fibroblasts, which are produced in many cells

and are involved in a wide range of cellular functions; they regulate tissue homeostasis, are involved in repair, immune and inflammatory responses, extracellular matrix deposition, and differentiation and cell growth. In mammals, there are three structural isoforms similar to TGF- β , including TGF- β 1, TGF- β 2, and TGF- β 3, which are encoded by three different genes. Although all three isoforms are expressed in fibrotic tissues, the development of tissue fibrosis is primarily attributed to TGF- β 1 (Biernacka *et al.*, 2011).

After TGF- β stimulation, fibroblasts are activated and transformed into myofibroblasts- cells that are affected by fibrotic conditions. The myofibroblast phenotype is characterized by the formation of perforated joints and the acquisition of a contractile apparatus with associated contractile proteins such as α -SMA and non-muscle myosin. The synthesis of α -SMA induced by TGF- β not only requires Smad3 pathway, but also demands FAK, JNK, TAK, and PI3 kinase/Akt pathways (Biernacka *et al.*, 2011).

In addition to differentiation of fibroblasts into myofibroblasts, TGF- β promotes the matrix protection and secretion by increasing the matrix protein synthesis and changing the balance between matrix protective and destructive signals. TGF- β stimulates the transcription of collagen type 1 gene in a Smad3-dependent manner (Biernacka *et al.*, 2011).

The important role of TGF- β in tissue fibrosis suggests that TGF- β -mediated pathways can be an attractive therapeutic modality for the treatment of patients with fibrotic conditions.

Plantago ovata is known as a rich source of various secondary metabolites that have antioxidant and anti-inflammatory effects and its role as a laxative, hypoglycemic, anti-inflammatory, anti-viral, analgesic, antioxidant, and anti-cancer agent, as well as immune system modifier and antihypertensive system is approved (El-feky *et al.*, 2018).

Despite significant advances in understanding liver fibrosis and setting goals for treatment, there are limited antifibrotic drugs for clinical use in patients with advanced liver disease, and a large group of patients do not respond to routine treatments and

therefore they are at risk of developing fibrosis to cirrhosis. Antioxidants are able to destroy extracellular matrix (ECM). Combination therapy that works on a variety of mechanisms to prevent the activation of stellate cells and the pathogenesis of liver fibrosis is more appropriate (Mormone *et al.*, 2011).

Therefore, this study intended to evaluate the expression of TGF- β as a fibrotic marker and serum ALP changes in cholestatic rats treated with *P. ovata* extract.

Materials and Methods

Experimental Animals and Ethical Aspects

In this study, 48 adult male Wistar rats within a weight range of 220-250 g were used. Animal care, and the experimental steps were performed in full accordance with the criteria of care and use of institutional Animals Medical Sciences Ethics Committee of Science and Research University, Tehran, Iran (Ethical code: IR.IAU.SRB.REC.1398.071). The number of rats was minimized as far as possible. After accommodation for two weeks, the rats were randomly divided into eight groups of six animals each as follows: (1) healthy control group without BDL surgery and treatment; (2–4) three healthy experimental groups plus *P. ovata* groups: rats underwent laparotomy without BDL, treated with *P. ovata* at dose levels of 100, 200, and 400 mg/kg body weight, respectively; (5) the BDL group: rats with BDL and treated with distilled water; and (6–8) the BDL plus *P. ovata* groups: rats with BDL and treated with *P. ovata* at dose levels of 100, 200, and 400 mg/kg body weight, respectively, via intragastric gavage for 45 consecutive days. The doses were selected based on previous studies on *P. ovata* LD50 (3660 mg/kg for rat) (Bagheri *et al.*, 2018). During the experiment, the animals were fed with rat food purchased from Pars Animal Feed Company and drinking water containing clean water ad libitum. The animals were kept in fiberglass cages (35 × 30 × 15 cm) under the conditions of 12-hour light-dark cycle and relative humidity of 40-60%. During the research period, ethical standards of working with laboratory animals were observed. In order to adapt the animals to the new keeping conditions, experiment began after two weeks.

Plant Extraction

Three kg of *P. ovata* was purchased from different perfumeries in Tehran and sent to the herbarium laboratory of Razi Laboratory Complex, Islamic Azad University, Science and Research Branch, for testing. To prepare the ethanolic extract, *P. ovata* seeds were ground, resolved in 80% ethanol (in a ratio of 1:12) and then mixed for 72 hours on a basic shaker (IKA KS 260, Germany). Then, it was passed through a filter paper and placed in a rotary machine (IKA-WERKE, Germany) for 1.5 hours. Finally, the liquid was dried for 24 hours at 50°C (to increase durability) and the resulting powder was mixed with a certain amount of distilled water as a solvent. The extract was administered to the rats by intragastric gavage once a day for 45 consecutive days (Karami *et al.*, 2017).

Bile Duct Ligation and Animal Treatment

The surgery was performed according to the standard procedure proposed by Uchinami *et al.* (2006). Therefore, after a 2-week period of adaptation of the rats to the environment, the animals were anesthetized with a combination of ketamine (90 mg/kg body weight) and xylazine (10 mg/kg body weight). After shaving and disinfecting the area, a 3-cm incision was made in the midline of the abdomen and the skin and muscle were dissected. The liver was tilted slightly upwards and after identifying the common bile duct, the duct was blocked and sutured in two places (after the end of the intrahepatic bile duct and before the entrance of the pancreatic duct) by a 4-0 silk suture and then the space between two sites were cut. Finally, 3 mL of 10% normal saline solution was poured into the abdominal cavity to prevent adhesion and the muscle and skin were sutured with 4-0 absorbable Vicryl sutures and 3-0 non-absorbable nylon, respectively. Oxytetracycline spray was used to prevent the rats from chewing the sutures. All animals were survived during the experiment. Two-three days after BDL, the urine and ear color of the animals turned yellow, which was a sign that the surgery was successful. From a day after the surgery, the treatment was started via intragastric gavage for 45 consecutive days (once per day). At the end of the treatment period and after 12 hours of fasting, the animals were sacrificed using the chloroform according to the ethical principles. Blood

samples were taken directly from their hearts for serum analysis. Furthermore, part of the liver tissue was fixed in 10% formalin buffer solution for immunohistochemical studies (Ale-Ebrahim *et al.*, 2014).

Serum ALP level

To measure the serum ALP level, blood samples were coagulated for 30 minutes at room temperature and then separated by serum centrifuges at 1000 rpm for 10 minutes. Serum ALP level was measured according to the IFCC (International Federation of Clinical Chemistry and Laboratory Medicine) method using the relevant dedicated kit from Pars Azmoon Company (Iran) in an automatic biochemistry analyzer (BT1500, Italy).

Immunohistochemical Evaluation

Immunohistochemistry is a method to show the presence and location of proteins in tissue sections and makes it possible to observe processes in the context of intact tissue. The immunohistochemical study was performed by obtaining 3-mm-thick sections from paraffin-embedded tissue blocks and placing them on a silanized glass slide. The sections were deparaffinized, washed in phosphate-buffered saline (PBS), and submitted to antigen retrieval. After treatment with normal serum, the sections were incubated with the anti-TGF- β antibodies (ABCAM, the USA) in a moist chamber at room temperature. Peroxidase activity was visualized by immersing the tissue sections in diaminobenzidine, which resulted in a brown reaction product. Finally, the sections were counterstained with Harris hematoxylin and coverslipped. Sections of human breast carcinoma were used as positive control for the anti-TGF- β 1 antibody, and sections of hepatic tissue without primary antibody were used as negative control.

Immunohistochemical analysis was performed with an Olympus light microscope (Olympus, Germany). Tissue sections were examined under light microscopy (100X magnification) to identify areas containing the largest number of immunoreactive cells, and the selected microscopic field was then analyzed at 400X magnification. The following aspects were considered in evaluating the TGF- β immunostaining:

Presence (+) or absence (-) of immunostaining, type of immunopositive cells and their tissue distribution (focal or diffuse). Expression of TGF- β 1 in hepatic tissues was evaluated based on the percentage of positive cells and classified as follows:

when positive cells accounted for less than 10% of total cells, TGF- β 1 negative staining (-), 10-25% of total cells, TGF- β 1 weak staining (+); 26-50%, TGF- β 1 moderate staining (++); 51-75%, TGF- β 1 stronger staining (+++); > 75%, TGF- β 1 the strongest staining (++++) (Alvares *et al.*, 2017, Javle *et al.*, 2014).

Statistical Analysis

All data were statistically analyzed using one-way ANOVA, Kruskal-Wallis, and Prism statistical program. The results were presented as Mean \pm standard error of measurement (S.E.M.) and in all stages of data analysis, the significance level less than 0.0001 was taken into consideration ($P < 0.0001$).

Results

Serum ALP Changes

The results of the present study showed that in the BDL group compared to the control group, there was a significant increase in ALP enzyme activity ($P < 0.0001$; [Figure 1](#)). Treatment of healthy animals in 3 groups with *P. ovata* at doses of 100, 200, and 400 mg/kg did not significantly change the mean compared to the control group. However, treatment of BDL animals with *P. ovata* at doses of 100, 200, and 400 mg/kg body weight in a dose-dependent manner caused a significant decrease in serum ALP activity compared to the BDL group, which are statistically significant so that treatment with a dose of 400 mg/kg had the greatest effect compared to the BDL group ($P < 0.0001$).

Immunohistochemistry

[Figure 2](#) shows the statistical analysis of TGF- β expression in study groups. In immunohistochemical staining, TGF- β expression was evaluated in different areas of the hepatic tissues. [Figure 2](#) depicts the changes in the TGF- β index in different groups. Histopathology findings for control group ([Figure 3A](#)) and 3 healthy experimental groups treated only with 100, 200, and 400 mg/kg ([Figure 3C-D-E](#)) indicated that TGF- β expression was negative in hepatocytes

around the central vein. In other words, these groups did not differ in the expression of TGF-β. TGF-β is a fibrogenic marker that is normally expressed only in the portal space. Since the aim of the present study was to evaluate the expression of TGF-β in hepatocytes, TGF-β expression for the mentioned groups was considered negative. In the BDL group, an increase in TGF-β expression was considered as highly positive both in hepatocytes and hyperplastic bile duct so that TGF-β expression was greatly seen as brownish stain in the hepatocytes and hyperplastic bile duct cytoplasm (Figure 3B). In the BDL group,

TGF-β expression was highly positive around the central vein, and the brownish cytoplasm of hepatocytes and hyperplastic bile duct were largely seen. In the BDL group treated with 100 mg/kg *P. ovata*, TGF-β expression was still strongly present (Figure 3F) while 200 and 400 mg/kg doses of *P. ovata* extracts were able to significantly reduce the TGF-β expression in a dose-dependent manner only in hyperplastic bile duct, and the greatest reduction was observed at 400 mg/kg dose (Figure 3G-H; $P < 0.0001$).

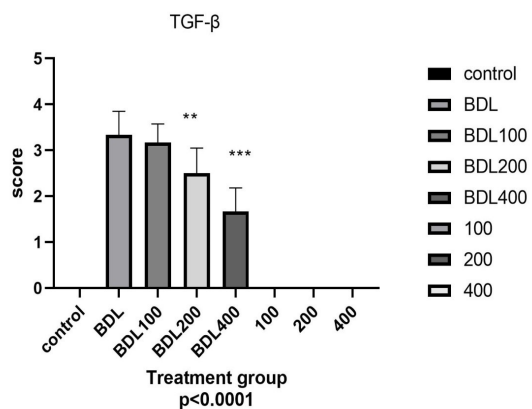
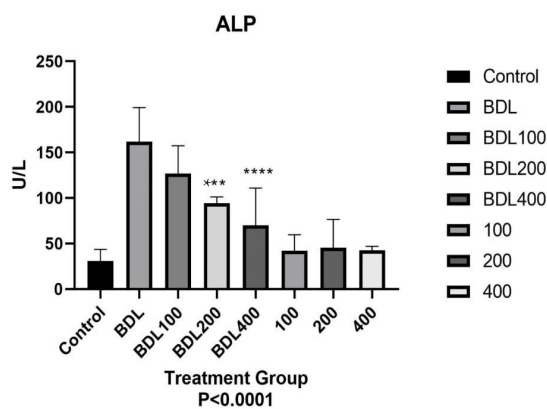
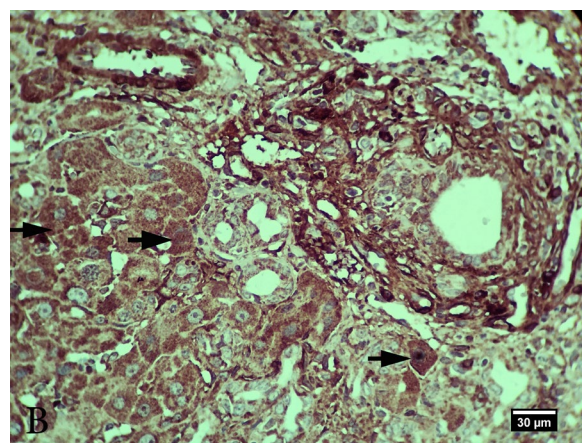
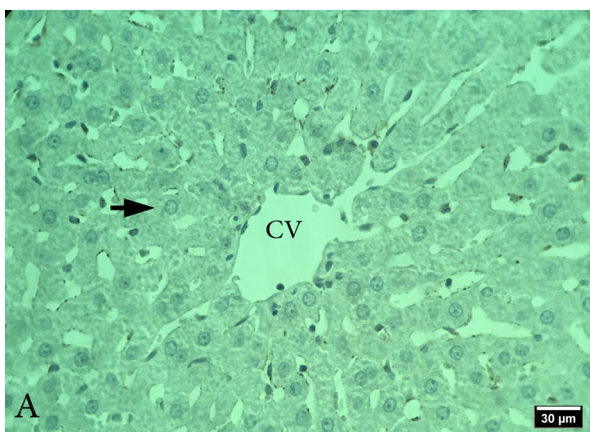


Figure 1. Effect of treatment via *P. ovata* at doses of 100, 200 and 400 mg/kg on serum alkaline phosphatase (ALP) in different studied groups ($P < 0.0001$)

*** : Significant statistical difference compared to cholestasis group (BDL)

Figure 2. Effect of treatment of *P. ovata* in doses of 100, 200 and 400 mg/kg on TGF-β expression in the liver of different studied groups ($P < 0.0001$).

*** : Significant statistical difference compared to cholestasis group (BDL)



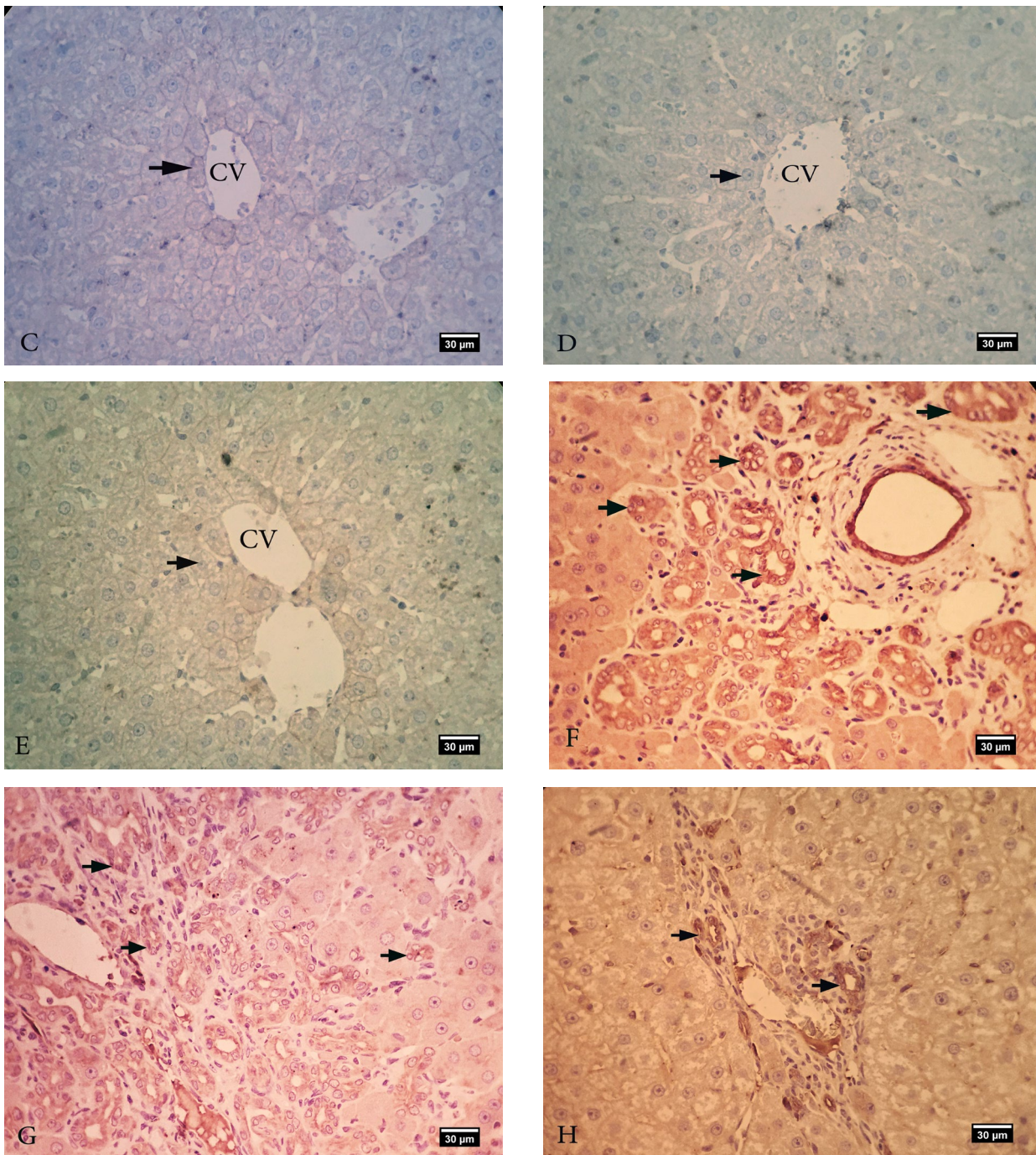


Figure 3. Expression of TGF- β in liver tissue sections in different studied groups (immunohistochemical staining (IHC)). (A) Control. (B) BDL Group. (C-D-E) Experimentally healthy treated at doses of 100, 200 and 400 mg/kg, respectively. (F-G-H) BDL (Cholestasis) group were treated with doses of 100, 200 and 400 mg/kg, respectively. TGF- β expression was negative in the control group and in healthy experimental groups treated with different doses of *P. ovata*, and hepatocytes around the central vein (arrow) were observed naturally. In the BDL (cholestasis) group, severe expression of TGF- β (arrow) is seen in the nucleus of hepatocytes in fibrous regions. In the BDL (cholestasis) group treated with 100 mg/kg *P. ovata*, there is a strong expression of TGF- β in the affected areas (arrow), but the expression of this marker in the BDL cholestasis groups treated with doses of 200 and 400 mg/kg (arrow) was reduced by treatment with *P. ovata* extract. (IHC)

Discussion

In this study, cholestasis and subsequent liver fibrosis were induced by BDL surgery in the rats to investigate the expression of TGF- β and ALP changes in cholestatic liver. BDL leads to liver fibrosis through the production of Reactive Oxygen Species (ROS) and the increased expression of fibrogenic markers (Yanguas *et al.*, 2016).

Antioxidants are compounds that can delay, prevent, or eliminate oxidative damage to the target molecule. Fibrotic cells experience a higher level of oxidative damage than normal cells, so it would be helpful to use antioxidant supplements in patients who suffer from these lesions (Morry *et al.*, 2011).

Some minerals and plants have antioxidant properties such as *P. ovata*. Measuring serum ALP levels is an indirect asset for assessing liver status. Retention and accumulation of hydrophobic bile acids within the hepatocytes during cholestasis has been considered as one of the most important causes of liver damage in this disease. Bile acids can disrupt cell membrane through their detergent action on lipid components, and produce ROS, which oxidatively alter lipids, proteins, and nucleic acids, and eventually cause hepatocyte apoptosis. In addition, they can activate Kupffer cells to produce ROS, and cause hepatocyte necrosis (Morry *et al.*, 2011).

Structural and functional damage caused by hydrophobic bile acids to hepatocyte membranes through ROS production plays an important role in the pathogenesis of cholestatic liver disease. In hepatocytes, when the concentration of hydrophobic bile acids exceeds the binding capacity of cytosolic proteins, these compounds likely damage the organelle membranes (Perez and Briz, 2009).

ALP is one of the induced enzymes in the liver, an enzyme that binds to the membrane of hepatocytes, thereby increasing its serum level due to damage to the membrane of hepatocytes. In the present study, 45 days after the beginning of the experiment, the BDL group showed a significant increase in serum ALP levels. Treatment of BDL rats with different doses of *P. ovata* extract significantly and dose-dependently reduced the serum level of ALP enzyme. Previous studies have shown that *P. ovata* exerts anti-inflammatory effect by improving the production of some mediators involved in intestinal

inflammatory responses such as cytokines (TNF- α , LTB4, and NO) in Inflammatory Bowel Disease (IBD) (Rodriguez *et al.*, 2003).

Research on diabetes also reports that *P. ovata* has antioxidant effects. Free radicals cause damage and insulin resistance, beta cell dysfunction, glucose instability, and diabetes. The reduction in superoxide dismutase (SOD) and catalase (CAT) activities and the increase in malondialdehyde (MDA) level and the induction of diabetes were reversed with the use of *P. ovata*. This suggests an antioxidant effect that may be attributed to phenolic compounds present in plants (Abdel-Rahim *et al.*, 2016).

Another study also showed that *P. ovata* can decrease glucose, and total cholesterol and LDL levels in men with type 2 diabetes (Galisteo *et al.*, 2010).

The results of the present study agree with the results of the mentioned studies on hepatoprotective and antioxidative activities of *P. ovata* extract. Hepatic stellate cells (HSCs), formerly called Ito cells, are the primary source of ECM components. Release of ROS with the secretion of cytokines and growth factors (e.g., PDGF, TGF- β , connective tissue growth factor (CTGF), interleukin-6 (IL-6), and IL-13) and immune cells during the inflammatory phase is known to stimulate stellate cell activation and collagen deposition in fibrosis. Of these, TGF- β is the strongest pre-fibrotic cytokine. The presence of ROS can activate TGF- β signaling pathways, which include Smad-dependent pathways or non-Smad-dependent pathways. TGF- β expression leads to the proliferation and transfer of fibroblasts to myofibroblasts, excessive production and deposition of ECM, and incidence of fibrosis. TGF- β is also a molecule involved in the production of intracellular ROS, thereby inducing fibrosis, too (Morry *et al.*, 2011).

P. ovata is known as a rich source of various secondary metabolites such as phenolic compounds, flavonoids, alkaloids, terpenoids, and ascorbic acid. In addition to their high carbohydrate and nutrient content, these compounds have antioxidant and anti-inflammatory effects. *P. ovata* is now widely used as a dietary supplement to treat hypercholesterolemia, constipation, and daily care of the large intestine. In

addition to these effects, it also has a preventive effect on cancers, especially colon and lung cancers (Nakamura *et al.*, 2004).

P. ovata has also been reported to reduce breast adenocarcinoma and ductal carcinoma (Nakamura *et al.*, 2014).

In addition, another study has demonstrated the protective effect of *P. ovata* against ketoprofen-induced hepatotoxicity due to its antioxidant and anti-inflammatory properties (El-Feky *et al.*, 2018).

Previous studies have shown that BDL significantly increases TGF- β expression in liver tissue. In the present study, BDL surgery increased the expression of this index in the BDL group through the accumulation of bile acids in the liver as well as ROS production. However, treatment of BDL rats with doses of 200 and 400 mg/kg of *P. ovata* was able to significantly reduce the expression of this cytokine. The effect of *P. ovata* extract on immunohistochemical parameters has not been studied so far. However, previous studies on other mineral and plant compounds with antioxidant effects on the TGF- β index were consistent with the results of the present study. For example, Wei *et al.* (2015) showed that pomegranate peel and seed extract had a protective effect against liver fibrosis induced by carbon tetrachloride, a mechanism possibly due to their antioxidant activity. It is associated with decreased TGF- β expression levels and inhibition of collagen synthesis (Wei *et al.*, 2015).

This study showed that the expression of TGF- β and ALP changes in the cholestatic liver induced by

P. ovata could probably reduce the TGF- β expression by increasing the antioxidative capacity of the liver and inhibiting the activation of stellate cells.

The treatment of the BDL group with *P. ovata* significantly reduced the TGF- β expression in a dose-dependent manner, compared with the BDL-untreated rats, though the effect of *P. ovata* at a dose of 100 mg/kg on TGF- β expression proved to be not significant statistically.

Moreover, *P. ovata* appeared to improve the serum ALP levels in a dose-dependent manner. There was a significant and logical correlation between the TGF- β expression as a fibrogenic marker and ALP changes as a cholestasis indicator so that *P. ovata* could reduce these alterations, and the greatest reduction was observed at 400 mg/kg dose for both of them. It seems that the effects of *P. ovata* are due to its antioxidant properties and the removal of free radicals, which probably refers to the phenolic compounds. In conclusion, *P. ovata* could likely be used as an antifibrotic supplement for patients with cholestatic liver disease in the future.

Acknowledgments

The authors of this article express their sincere gratitude and appreciation to officials of Faculty of Veterinary Science, Islamic Azad University, Science and Research Branch, for providing facilities to perform this research.

Conflict of Interest

The authors declared that there is no conflict of interest.

References

- Abdel-Rahim, E. A., Rashed, M. M., El-Hawary, Z. M., Abdelkader, M. M., Kassem, S. S., & Mohamed, R. S. (2016). Anti-diabetic Effect of Cichorium intybus Leaves and Plantago ovate Seeds in High Fat Diet-streptozotocin Induced Diabetic Rats. *Journal of Food and Nutrition Research*, 4(5), 276-281.
- Ale-Ebrahim, M., Eidi, A., Mortazavi, P., Tavangar, S. M., & Tehrani, D. M. (2015). Hepatoprotective and antifibrotic effects of sodium molybdate in a rat model of bile duct ligation. *Journal of Trace Elements in Medicine and Biology*, 29, 242-248. [DOI:10.1016/j.jtemb.2014.07.002] [PMID]

- Alvares, P. R., Arruda, J. A. A. D., Silva, L. P. D., Nascimento, G. J. F. D., Silveira, M. F. D., & Sobral, A. P. V. (2017). Immunohistochemical expression of TGF- β 1 and MMP-9 in periapical lesions. *Brazilian Oral Research*, 31, 51-63. [DOI:10.1590/1807-3107bor-2017.vol31.0051] [PMID]
- Bagheri, S. M., Zare-Mohazabieh, F., Momeni-Asl, H., Yadegari, M., Mirjalili, A., & Anvari, M. (2018). Anti-ulcer and hepatoprotective effects of aqueous extract of *Plantago ovata* seed on indomethacin-ulcerated rats. *Biomedical Journal*, 41(1), 41-45. [DOI:10.1016/j.bj.2018.01.001] [PMID] [PMCID]
- Biernacka, A., Dobaczewski, M., & Frangogiannis, N. G. (2011). TGF- β signaling in fibrosis. *Growth Factors*, 29(5), 196-202. [DOI:10.3109/08977194.2011.595714] [PMID] [PMCID]
- Chen, W. Y., Chen, C. J., Liao, J. W., & Mao, F. C. (2009). Chromium attenuates hepatic damage in a rat model of chronic cholestasis. *Life Sciences*, 84(17-18), 606-614. [DOI:10.1016/j.lfs.2009.02.003]
- El-Feky, A. M., Elbatany, M. M., Naser, A. F. A., & Hamed, M. A. (2018). A therapeutic insight of carbohydrate and fixed oil from *Plantago ovata* L. seeds against ketoprofen-induced hepatorenal toxicity in rats. *Bulletin of the National Research Centre*, 42(1), 1-16. [DOI:10.1186/s42269-018-0031-4]
- Erdogan, M., & Tekeli, S. (2002). The effect of martensite particle size on tensile fracture of surface-carburised AISI 8620 steel with dual phase core microstructure. *Materials and Design*, 23(7), 597-604. [DOI:10.1016/S0261-3069(02)00065-1]
- Galisteo, M., Morón, R., Rivera, L., Romero, R., Anguera, A., & Zarzuelo, A. (2010). *Plantago ovata* husks-supplemented diet ameliorates metabolic alterations in obese Zucker rats through activation of AMP-activated protein kinase. Comparative study with other dietary fibers. *Clinical Nutrition*, 29(2), 261-267. [DOI:10.1016/j.clnu.2009.08.011] [PMID]
- Huan, W., Wu, X., Zhang, S., Zhao, Y., Xu, H., Wang, N., ... & Wang, Y. (2012). Spatiotemporal patterns and essential role of TNF receptor-associated factor 5 expression after rat spinal cord injury. *Journal of Molecular Histology*, 43(5), 527-533. [DOI:10.1007/s10735-011-9350-6] [PMID]
- Javle, M., Li, Y., Tan, D., Dong, X., Chang, P., Kar, S., & Li, D. (2014). Biomarkers of TGF- β signaling pathway and prognosis of pancreatic cancer. *PLoS one*, 9(1), e85942. [DOI:10.1371/journal.pone.0085942] [PMID] [PMCID]
- Karami, L., Ghahtan, N., & Habibi, H. (2017). Antibacterial effect of *plantago ovata* and *lallelantia iberica* seed extracts against some bacteria. *Research in Molecular Medicine*, 5(3), 32-36. [DOI:10.29252/rmm.5.3.32]
- Latimer, K. S. (Ed.). (2011). *Duncan and Prasse's veterinary laboratory medicine: clinical pathology*. Hoboken, NJ: John Wiley & Sons.
- Mormone, E., George, J., & Nieto, N. (2011). Molecular pathogenesis of hepatic fibrosis and current therapeutic approaches. *Chemico-biological Interactions*, 193(3), 225-231. [DOI:10.1016/j.cbi.2011.07.001] [PMID] [PMCID]
- Morry, J., Ngamcherdtrakul, W., & Yantasee, W. (2017). Oxidative stress in cancer and fibrosis: Opportunity for therapeutic intervention with antioxidant compounds, enzymes, and nanoparticles. *Redox Biology*, 11, 240-253. [DOI:10.1016/j.redox.2016.12.011] [PMID] [PMCID]
- Nakamura, Y., Trosko, J. E., Chang, C. C., & Upham, B. L. (2004). Psyllium extracts decreased neoplastic phenotypes induced by the Ha-Ras oncogene transfected into a rat liver oval cell line. *Cancer Letters*, 203(1), 13-24. [DOI:10.1016/j.canlet.2003.08.022] [PMID]
- Nakamura, Y., Yoshikawa, N., Hiroki, I., Sato, K., Ohtsuki, K., Chang, C. C., ... & Trosko, J. E. (2005). β -Sitosterol from psyllium seed husk (*Plantago ovata* Forsk) restores gap junctional intercellular communication in Ha-ras transfected rat liver cells. *Nutrition and Cancer*, 51(2), 218-225. [DOI:10.1207/s15327914nc5102_12] [PMID]
- Perez, M.J., Briz, O. (2009). Bile-acids-induced cell injury and protection. *World Journal of Gastroenterology*, 15(14): 1677-1689. [DOI:10.3748/wjg.15.1677] [PMID] [PMCID]
- Sadeghian, F., Rahmanian, S., & Kargar Jahromi, H. (2018). Impact of aqueous extract of *Plantago ovata* fork (psyllium) fruit on the improvement of non-alcoholic fatty liver disease among male rats. *Asian Journal of Pharmaceutics*, 12(1), S173-S178.

- Tag, C. G., Weiskirchen, S., Hittatiya, K., Tacke, F., Tolba, R. H., & Weiskirchen, R. (2015). Induction of experimental obstructive cholestasis in mice. *Laboratory Animals*, 49(1_suppl), 70-80. [[DOI:10.1177/0023677214567748](https://doi.org/10.1177/0023677214567748)] [[PMID](#)]
- Wei, X. L., Fang, R. T., Yang, Y. H., Bi, X. Y., Ren, G. X., Luo, A. L., ... & Zang, W. J. (2015). Protective effects of extracts from Pomegranate peels and seeds on liver fibrosis induced by carbon tetrachloride in rats. *BMC Complementary and Alternative Medicine*, 15(1), 1-9. [[DOI:10.1186/s12906-015-0916-9](https://doi.org/10.1186/s12906-015-0916-9)] [[PMID](#)] [[PMCID](#)]
- Yanguas, S. C., Cogliati, B., Willebrords, J., Maes, M., Colle, I., Van den Bossche, B., ... & Vincken, M. (2016). Experimental models of liver fibrosis. *Archives of Toxicology*, 90(5), 1025-1048. [[DOI:10.1007/s00204-015-1543-4](https://doi.org/10.1007/s00204-015-1543-4)] [[PMID](#)] [[PMCID](#)]

مطالعه بیان کبدی فاکتور رشدی تغییر شکل دهنده بتا و تغییرات فسفاتاز قلیایی سرم در موش‌های صحرائی کلستاتیک تیمار شده با عصاره اتانولی گیاه اسفرزه

مأنده رفیعی^۱، پژمان مرتضوی^{۲*}، احمد اصغری^۳

^۱دانشکده دامپزشکی، واحد علوم و تحقیقات، دانشگاه آزاد اسلامی، تهران، ایران.

^۲گروه پاتوبیولوژی، دانشکده دامپزشکی، واحد علوم و تحقیقات، دانشگاه آزاد اسلامی، تهران، ایران.

^۳گروه علوم درمانگاهی، دانشکده دامپزشکی، واحد علوم و تحقیقات، دانشگاه آزاد اسلامی، تهران، ایران

(دریافت مقاله: ۱۱ آبان ماه ۱۳۹۹، پذیرش نهایی: ۱۵ بهمن ماه ۱۳۹۹)

زمینه مطالعه: القا کلستاز، یکی از روش‌های ایجاد فیبروز کبدی است که موجب توسعه استرس اکسیداتیو، افزایش بیان نشان‌گرهای فیبروزیک، رسوب بیش از حد ماتریکس خارج سلولی و در نهایت بروز فیبروز می‌گردد. اسفرزه به‌عنوان یک منبع غنی از متابولیت‌های ثانویه مختلف مانند ترکیبات فنولی، آلکالوئیدها، تریپانوئیدها و اسید آسکوربیک شناخته می‌شود.

هدف: در مطالعه حاضر، بیان $TGF-\beta$ به‌عنوان یک نشانگر فیبروتیک و تغییرات ALP سرم در موش‌های کلستاتیک تحت درمان با عصاره *P. ovata* بررسی شد.

روش کار: در این مطالعه، از ۴۸ سر موش صحرائی نژاد ویستار استفاده شد. موش‌ها به‌طور تصادفی به ۸ گروه ۶ تایی تقسیم شدند که به شرح زیر است: (۱) گروه کنترل سالم بدون جراحی BDL و بدون درمان. (۲-۴) سه گروه آزمایشی سالم به علاوه اسفرزه: موش‌های بدون BDL تحت درمان با اسفرزه در دوزهای ۱۰۰، ۲۰۰ و ۴۰۰ میلی‌گرم/کیلوگرم وزن بدن. (۵) گروه BDL: موش‌های جراحی BDL شده و تیمار شده با آب مقطر. (۶-۸) سه گروه BDL به‌علاوه اسفرزه: موش‌های جراحی BDL شده و تحت درمان با اسفرزه در دوزهای ۱۰۰، ۲۰۰ و ۴۰۰ میلی‌گرم/کیلوگرم وزن. موش‌ها به مدت ۴۵ روز متوالی (روزانه یکبار) با عصاره *P. ovata* تحت درمان قرار گرفتند. پس از آسان‌کشی (که براساس اصول اخلاقی انجام شد) و جداسازی سرم، آنزیم آلکالین فسفاتاز اندازه‌گیری شد. همچنین، کبد موش‌ها در محلول بافر فرمالین ۱۰٪ فیکس شد. مطالعه ایمونوهیستوشیمی با آنتی‌بادی $TGF-\beta$ انجام شد. تجزیه و تحلیل داده‌ها با استفاده از آزمون One Way Anova و Kruskal-Wallis و برنامه آماری Prism انجام شد ($P < 0.001$).
نتایج: نتایج افزایش قابل توجهی در سطح سرمی آنزیم ALP و بیان $TGF-\beta$ در گروه BDL را نشان داد. درمان با عصاره *P. ovata* توانست به‌طور قابل توجهی این تغییرات را به صورت وابسته به دوز بهبود بخشد.

نتیجه‌گیری نهایی: نهایی: نتایج این مطالعه نشان داد که *P. ovata* به دلیل ترکیبات فنولی و اثر آنتی‌اکسیدانی خود، اثر محافظتی روی کبد داشته و متعاقباً موجب بهبود سطح ALP سرم و همچنین کاهش بیان $TGF-\beta$ می‌شود.

واژه‌های کلیدی: آلکالین فسفاتاز، اسفرزه، کلستاز، فاکتور رشد تغییر شکل دهنده بتا ($TGF-\beta$)، موش صحرائی