

## Case Report

Tibiotarsal Subcutaneous Xanthogranuloma in a Rose-breasted Cockatoo (*Eolophus roseicapilla*): A Case Report

Farhang Sasani<sup>1\*</sup>, Diba Golchin<sup>1</sup>, Mohammad Yasan Bangash<sup>2,3</sup>, Soheil Khorasaninejad<sup>4</sup>, Sanaz Banifazl<sup>1</sup>

1. Department of Pathology, Faculty of Veterinary Medicine, University of Tehran, Tehran, Iran.

2. Department of Surgery, Oxygen Veterinary Hospital, Tehran, Iran.

3. Department of Clinical Sciences, Faculty of Veterinary Medicine, Université de Montréal, Montréal, Canada.

4. Department of Ornamental Bird Diseases, Oxygen Veterinary Hospital, Tehran, Iran.



**How to Cite This Article** Sasani, F., Golchin, D., Bangash, M. Y., Khorasaninejad, S., & Banifazl, S. (2024). Tibiotarsal Subcutaneous Xanthogranuloma in a Rose-breasted Cockatoo (*Eolophus roseicapilla*): A Case Report. *Iranian Journal of Veterinary Medicine*, 18(1), 151-158. <http://dx.doi.org/10.32598/ijvm.18.1.1005267>

**doi** <http://dx.doi.org/10.32598/ijvm.18.1.1005267>



## ABSTRACT

**Background:** Xanthogranuloma (xanthoma) presents as a rare, non-infectious granulomatous lesion with a yellowish and soft appearance. Hypercholesterolemia and hyperlipidemia are believed to be the underlying causes of this lesion. Xanthoma has been identified in vertebrates and humans.

**Objectives:** This report presents a case of cutaneous xanthogranuloma located in the tibiotarsal region of a 5-year-old rose-breasted cockatoo (*Eolophus roseicapilla*) fed with high-fat diets.

**Methods:** The cockatoo underwent anesthesia using isoflurane administered through a face mask connected to an Ohmeda anesthesia machine. The mass was surgically removed and submitted for histopathological examination. The tissue was fixed in 10% neutral buffered formalin, and representative sections were routinely processed for hematoxylin and eosin (H&E) staining. Moreover, frozen sections were obtained and stained with the Oil Red O technique.

**Results:** Upon histopathologic examination of routine H&E slides, vacuolated macrophages, and multinucleated giant cells were noted in addition to cholesterol clefts and heterophilic infiltrates. Oil Red O staining was performed to detect intracellular and extracellular lipid content. Xanthogranulomas invaded the surrounding tissues, necessitating complete surgical excision. The lesion did not recur during the 1-month follow-up, but the patient died due to respiratory disorders.

**Conclusion:** Stress and high-lipid feed consumption were considered the predisposing factors to xanthogranuloma development in this bird.

**Keywords:** Cockatoo, Tibiotarsal region, Xanthogranuloma, Histopathology, Oil red O

## Article info:

Received: 05 Jan 2023

Accepted: 18 Mar 2023

Publish: 01 Jan 2024

## \* Corresponding Author:

Farhang Sasani, Professor:

Address: Department of Pathology, Faculty of Veterinary Medicine, University of Tehran, Tehran, Iran.

Phone: +98 (21) 61117060

E-mail: [fsasani@ut.ac.ir](mailto:fsasani@ut.ac.ir)

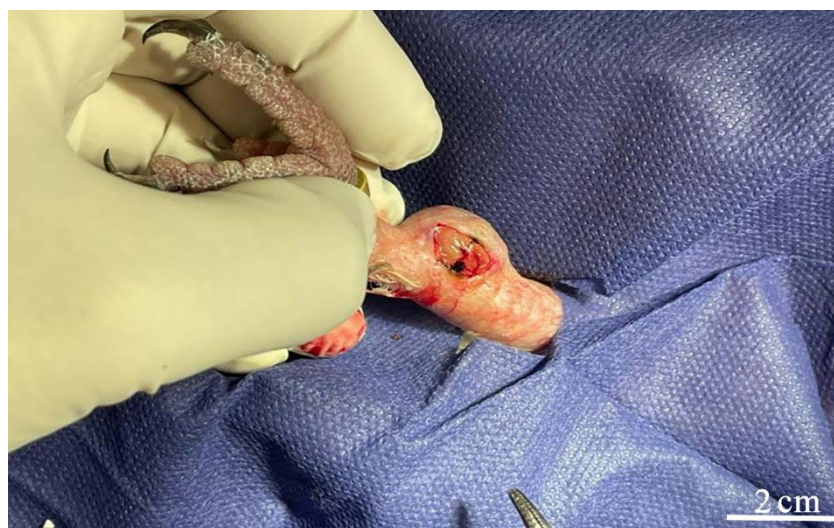## Case History

**X**anthomas (also known as xanthogranulomas) are rare non-neoplastic and non-infectious granulomatous lesions. Grossly, they appear as variably sized, mostly nodular, yellowish (as the name implies) soft masses stemming from abnormal intracellular and extracellular cholesterol accumulation (Benoit-Biancamano & Langlois, 2020; Lennox, 2014; Mauldin & Peters-Kennedy, 2016; Schmidt et al., 2015). Histologically, they present as large lipid-laden foamy macrophages, multinucleated giant cells (sometimes Touton giant cells), and cholesterol clefts. Lymphocytic and heterophilic infiltrates are usually observed (Mauldin & Peters-Kennedy, 2016; Reavill & Dorrestein, 2018; Schmidt et al., 2015; Stacy et al., 2021). Xanthomas have been reported in humans (Benoit-Biancamano & Langlois, 2020) as well as a broad range of animals, such as frogs (Carpentear et al., 1986), fish (Béland et al., 2020), dogs (Harvey et al., 2020; Russell & Courtman, 2019), cats (Barachetti et al., 2021), cattle (Özmen et al., 2014), birds, and even reptiles, however, uncommon (Stacy et al., 2021). In recent years avian xanthomas have been reported in various species such as Japanese quails (*Coturnix japonica*) (Sasikala et al., 2018), blue and gold macaws (*Ara ararauna*) (Souza et al., 2009), cockatiels (*Nymphicus hollandicus*) (Lipar et al., 2011; Pazhanivel et al., 2018), great white pelicans (*Pelecanus onocrotalus*) (Di Girolamo et al., 2014), budgerigars (*Melopsittacus undulatus*) (Shokrpoor et al., 2019), and Eclectus parrots (*Eclectus roratus*) (Hanson et al., 2020). Xanthogranulomas have been reported in the cutaneous and subcutaneous tissues and tendons.

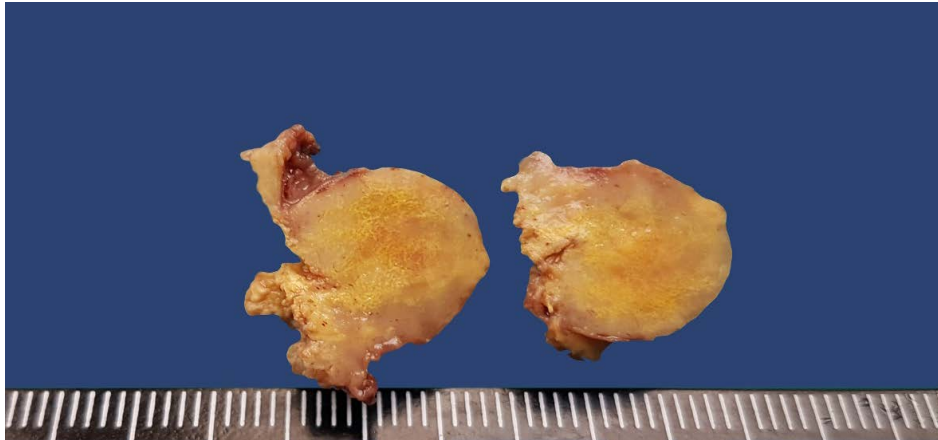
Also, there are uncommon records of visceral involvement (Benoit-Biancamano & Langlois, 2020; Reavill and Dorrestein, 2018; Schmidt et al., 2015). Eyelids and the skin covering the face, wings, sternum, ventral abdomen, pubis, and thighs are the commonly affected anatomic regions in birds (Reavill & Dorrestein, 2018; Trupkiewicz et al., 2018). Despite the ambiguity on the underlying cause, mechanical stress (Stacy et al., 2021), chronic trauma (Lennox, 2014), and inflammation (Hanson et al., 2020) are suspected to be the predisposing factors to the disease. Genetic predisposition (such as storage disorders), metabolic impairments, renal disorders, endocrinopathies, and high-lipid feed consumption can lead to dyslipidemia (e.g. hypercholesterolemia and hyperlipidemia), thus increasing the risk of xanthomas (Barboza & Beaufrère, 2019; Hanson et al., 2020; Reavill & Dorrestein, 2018; Stacy et al., 2021). Lipoma, xanthoma, and spindle cell tumors (especially fibrosarcoma) are the primary differential diagnoses of such soft subcutaneous masses (Chang et al., 2019; Latimer & Rakich, 1995; Stacy et al., 2021). This paper presents a case of xanthogranuloma in an uncommon anatomic region in a rose-breasted cockatoo. The surgical excision process, macroscopic findings, histopathologic features, routine hematoxylin and eosin (H&E) staining, and Oil Red O special staining are described.

## Clinical Presentation

In January 2022, a 350-g, 5-year-old, rose-breasted cockatoo (*Eolophus roseicapilla*) (Galah) was referred for assessment of a non-pruritic and non-painful soft subcutaneous mass on the medial aspect of the tibiotarsal region for the past 7 days (Figure 1). The animal's



**Figure 1.** The subcutaneous mass in the tibiotarsal region with superficial hyperemia and focal hemorrhage



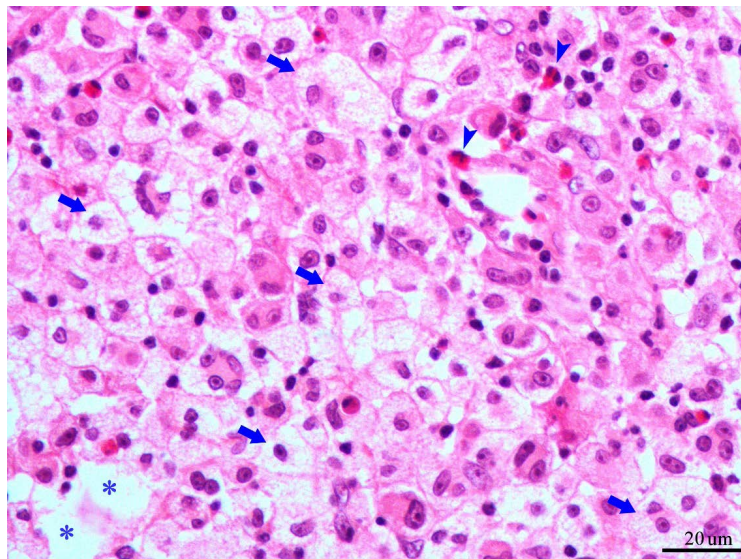
**Figure 2.** The cut surface of the excised mass with vivid yellow material deposition

diet was mainly composed of nuts and seeds (mostly pumpkin seed, sunflower seed, and hemp seed), boiled eggs, human food, and occasionally fruits. Upon physical examination, concurrent bacterial airsacculitis, most remarkable in thoracic and clavicular air sacs, was diagnosed in the bird. Due to the severity and urgency of the respiratory condition, antibiotic therapy took precedence over the surgical removal of the mass. During 3 weeks, aminophylline was administered in conjunction with enrofloxacin through nebulization. Surgical excision was planned because the mass grew significantly during the treatment course.

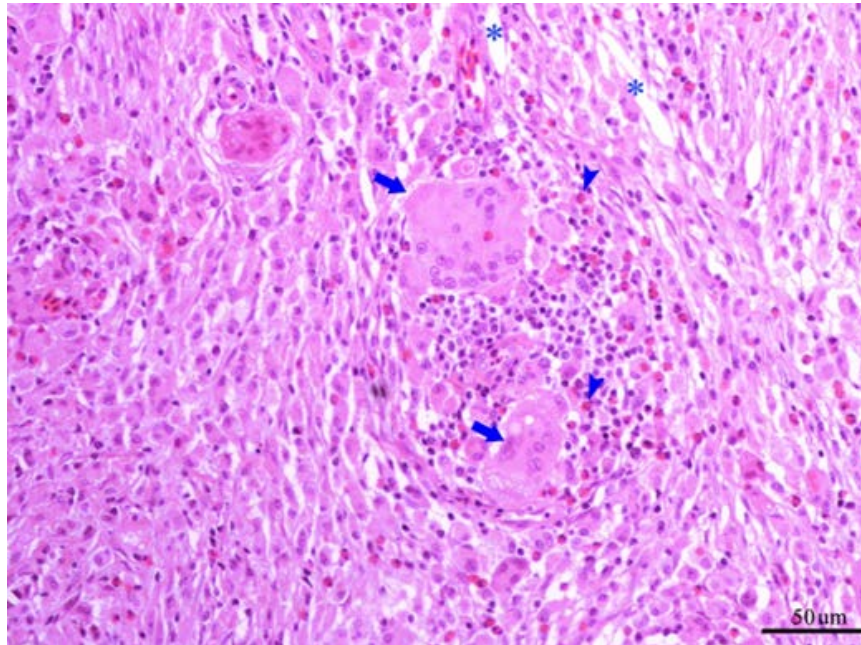
The anesthesia was induced by delivering isoflurane through a face mask connected to an Ohmeda anesthesia machine (Ohmeda Inc, United States). Then, an endotra-

cheal catheter was placed and connected to a Mapleson-F Open Respiratory Circuit, delivering isoflurane to the patient for maintaining anesthesia. The mass was finely dissected from the underlying tissues and excised thoroughly from the region. There were some invasions to the underlying tissues and muscles, which were freed easily. The bone was intact with no grossly evident invasion. The bird was recovered from anesthesia and discharged after 2 hours. The wound healed after 10 days with no gross appearance of relapse of the mass, but unfortunately, the bird died after 1 month due to respiratory disorders.

The excised tissue was immersed in 10% neutral buffered formalin. Following the gross inspection, representative sections were obtained, processed routinely, em-



**Figure 3.** Lipid-laden macrophages (arrows), heterophils (arrowheads), and extracellular lipid depositions (asterisks) (hematoxylin and eosin (H&E) staining)



**Figure 4.** Multinucleated giant cells (arrows), heterophils (arrowheads), and cholesterol clefts (asterisks) (hematoxylin and eosin (H&E) staining)

bedded in paraffin, cut at 5- $\mu$ m thickness, and stained with H&E for histopathologic evaluation. Frozen sections were also obtained from the mass and stained with Oil Red O to detect lipid accumulation.

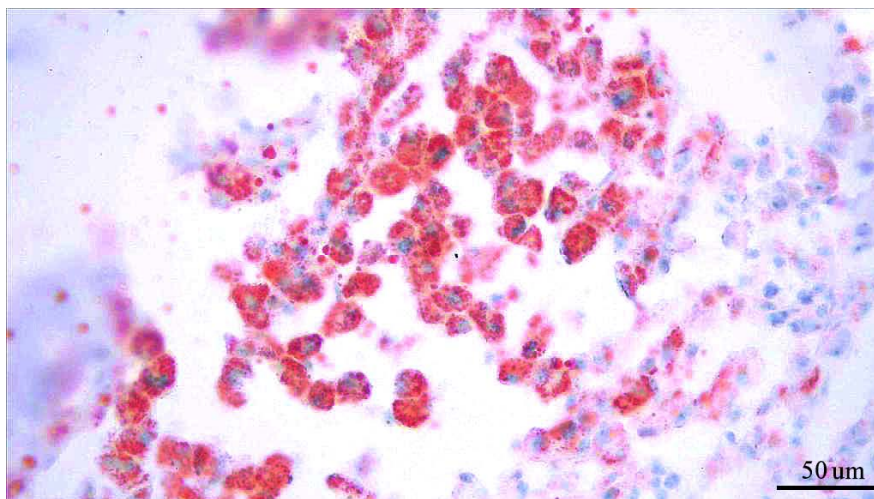
### Diagnostic testing

Subcutaneous connective tissue and muscle invasion were noted throughout the surgery, sparing the bones. Upon gross inspection, a 2 $\times$ 1.5 $\times$ 1.2 cm irregular, yellowish tan, soft, and friable mass was detected with multifocal superficial hemorrhage. The cut surface showed a vivid yellow material deposition (Figure 2). Histopatho-

logic scrutiny revealed sheets of densely packed foamy and lipid-laden macrophages, heterophilic inflammatory infiltrates (Figure 3), numerous multinucleated giant cells, and cholesterol clefts (Figure 4). Lipid-laden macrophages and extracellular lipid deposits were positively stained with Oil Red O (Figure 5).

### Assessment

Xanthogranulomas are sterile granulomatous lesions composed of finely vacuolated macrophages, multinucleated giant cells, cholesterol clefts, and crystals, with occasional necrosis (Mauldin & Peters-Kennedy, 2016;



**Figure 5.** Intracellular and extracellular lipid content (Oil Red O staining)

Stacy et al., 2021), matched with the findings in the present case. Xanthomas may be single or multiple (xanthomatosis) (Mauldin & Peters-Kennedy, 2016; Trupkiewicz et al., 2018), nodular (Mauldin & Peters-Kennedy, 2016), or disseminated (Carpentear et al., 1986; Hanson et al., 2020). Diagnosis can be made by histopathology. Surgical excision (Koski, 2002), radiation therapy, hyperthermia (Filippich, 2004; Koski, 2002), and sufficient dietary vitamin A (Reavill & Dorrestein, 2018) have been proposed for treatment. Xanthomas may lead to focal feather loss without feather-picking (Koski, 2002). This lesion is more frequent in psittacine (Psittaciformes order), predominately in older budgerigars and cockatiels (Reavill & Dorrestein, 2018). However, other avian orders, including Columbiformes, Anseriformes, and Accipitriformes, have also been affected (Hanson et al., 2020). Budgerigars and cockatoos, especially galah or rose-breasted cockatoos (*Eolophus roseicapilla*), are prone to developing lipomas (Filippich, 2004; Koski, 2002). Despite the benign nature, the surrounding tissues may be massively invaded by xanthomas (Kubiak, 2021), which was seen in our patient. In terms of etiology, the lipid-rich diet of this bird (majorly composed of pumpkin seed, sunflower seed, hemp seed, and boiled eggs) and lack of any clinical signs related to renal diseases or endocrinopathies explain the propensity of developing xanthogranuloma. It is well-established that high-fat diets and hyperlipidemia are linked to developing xanthomas (Stacy et al., 2021). Moreover, the owner rejected any previous local trauma, inflammation, or irritation; such lesions were absent in the patient's health records. It can be concluded that stress, dietary imbalance, and consumption of lipid-rich feed are the leading underlying causes of the development of xanthogranuloma in this patient.

## Ethical Considerations

### Compliance with ethical guidelines

The patient's owner provided written informed consent for the treatment and diagnostic work-up, follow-up of their pet, and participation in this case report.

### Funding

This research received no financial support for this research, diagnostic work-up, authorship, or publication.

### Authors' contributions

Supervision, investigation and funding acquisition: Farhang Sasani; Conceptualization, methodology, investiga-

tion, resources, original draft preparation: Diba Golchin; Data collection and investigation: Mohammad Yasan Bangash, Soheil Khorasaninejad and Sanaz Banifazl; Review & editing: All authors.

### Conflict of interest

The authors declared no conflict of interest.

### Acknowledgments

The authors would like to thank Fahimeh Babaahmadi Milani for her invaluable technical support.

## References

- Barachetti, L., Fanton, N., Savov, S., Cancelli, I., & Miller P. E. (2021). Lipemic aqueous humor and suspected xanthomas associated with primary hypertriglyceridemia in a cat. *Vet Record Case Reports*, 9(3), e123. [DOI:10.1002/vrc2.123]
- Barboza, T., & Beaufrère, H. (2019). Comparison of a point-of-care cholesterol meter with a reference laboratory analyzer in companion psittaciformes. *Journal of Avian Medicine and Surgery*, 33(1), 7–14. [DOI:10.1647/2017-291] [PMID]
- Benoit-Biancamano, M. O., & Langlois, I. (2020). Sterile traumatic panniculitis in a captive Brent goose. *Journal of Veterinary Diagnostic Investigation: Official Publication of the American Association of Veterinary Laboratory Diagnosticians, Inc*, 32(2), 336–338. [DOI:10.1177/1040638720907586] [PMID] [PMCID]
- Béland, K., Wong, E., St-Cyr, J. F., & Lair, S. (2020). High occurrence rate of xanthomatosis and nephrocalcinosis in aquarium-housed Atlantic wolffish *Anarhichas lupus* and spotted wolffish *A. Minor*. *Diseases of Aquatic Organisms*, 139, 223–232. [DOI:10.3354/dao03477. PMID: 32495748] [PMID]
- Carpenter, J. L., Bachrach, A., Jr, Albert, D. M., Vainisi, S. J., & Goldstein, M. A. (1986). Xanthomatous keratitis, disseminated xanthomatosis, and atherosclerosis in Cuban tree frogs. *Veterinary Pathology*, 23(3), 337–339. [DOI:10.1177/030098588602300320] [PMID]
- Chang, J. C., Tsai, F. Y., Lee, Y. S., Wang, R. C., Kao, J. P., & Chiou, H. Y., et al. (2019). Case report: Liposarcoma with microvascular proliferation in a cockatiel (*Nymphicus hollandicus*). *Taiwan Veterinary Journal*, 45(3), 85–89. [DOI:10.1142/S1682648519720028]
- Di Girolamo, N., Lane, E. P., Reyers, F., & Gardner, B. R. (2014). Subcutaneous xanthomatosis in a great white pelican (*Pelecanus onocrotalus*). *Journal of Zoo and Wildlife Medicine: Official Publication of the American Association of Zoo Veterinarians*, 45(1), 153–156. [DOI:10.1638/2012-0234r2.1. PMID: 24712175.] [PMID]
- Filippich, L. J. (2004). Tumor control in birds. *Seminars in Avian and Exotic Pet Medicine*, 13(1), 25–43. [DOI:10.1053/S1055-937X(03)00055-0]

- Hanson, M. E., Donovan, T. A., Quesenberry, K., Dewey, A., Brown, C., & Chen, S., et al. (2020). Imaging features of disseminated xanthogranulomatous inflammation in eclectus parrots (*Eclectus roratus*). *Veterinary Radiology & Ultrasound: The Official Journal of the American College of Veterinary Radiology and the International Veterinary Radiology Association*, 61(4), 409–416. [DOI:10.1111/vru.12861] [PMID]
- Harvey, A. M., Teixeira, L. B. C., & Dubielzig, R. R. (2020). A clinicopathological study of 17 cases of ocular surface xanthogranuloma in dogs. *Veterinary Ophthalmology*, 23(1), 190–198. [DOI:10.1111/vop.12711] [PMID]
- Koski, M. A. (2002). Dermatologic diseases in psittacine birds: An investigational approach. *Seminars in Avian and Exotic Pet Medicine*, 11(3), 105–124. [DOI:10.1053/saep.2002.123981]
- Kubiak, M. (2021) Budgerigars and cockatiels. In: M. Kubiak (Ed.), *Handbook of Exotic Pet Medicine* (pp. 141–164). New Jersey: John Wiley & Sons. [DOI:10.1002/9781119389934.ch10]
- Latimer, K. S., & Rakich, P. M. (1995). Subcutaneous and hepatic myelolipomas in four exotic birds. *Veterinary Pathology*, 32(1), 84–87. [DOI:10.1177/030098589503200117] [PMID]
- Lennox, A. (2014). Dermatological diseases. In: C. B. Greenacre, & T. Y. Morishita (Eds.), *Backyard poultry medicine and surgery: A Guide for veterinary practitioners* (pp. 259–274). New Jersey: John Wiley & Sons. [DOI:10.1002/9781119511816.ch15]
- Lipar, M., Horvatek, D., Prukner-Radovčić, E., Kurilj, A. G., Radišić, B., & Vnuk, D., et al. (2011). Subcutaneous xanthoma in a cockatiel (*nymphicus hollandicus*): A case report. *Veterinarski Arhiv*, 81(4), 535–543. [Link]
- Mauldin, E. A., & Peters-Kennedy, J. (2016). Integumentary system. In: M. G. Maxie (Ed). *Jubb, Kennedy, and Palmer's pathology of domestic animals* (p. 700). Amsterdam: Elsevier. [DOI:10.1016/B978-0-7020-5317-7.00006-0] [PMCID]
- Özmen, Ö., Gelen, T., Aydoğan, A., Haligur, M., & Çetin, Y. (2014). A case of vaginal xanthoma in a cow; first report. *Ankara Üniversitesi Veteriner Fakültesi Dergisi*, 61(4), 313–317. [Link]
- Pazhanivel, N., Balachandran, C., Saahithya, R., Sudhakar Rao, G. V., Shafiuza, M., & Krishnaveni, N. (2018). A case report of cutaneous xanthoma in a cockatiel (*Nymphicus hollandicus*). *Journal of Entomology and Zoology Studies*, 6(5), 556–558. [Link]
- Reavill, D. R., & Dorrestein, G. (2018). Psittacines, coliformes, musophagiformes, cuculiformes. In: K. A. Terio, D. McAloose, & J. St. Leger (Eds.), *Pathology of wildlife and zoo animals* (pp. 775–798). Amsterdam: Elsevier. [DOI:10.1016/B978-0-12-805306-5.00032-8]
- Russell, E. B., & Courtman, N. F. (2019). Unique cytologic and histologic features of a suspected cutaneous xanthoma in a dog. *Veterinary Clinical Pathology*, 48(4), 716–720. [DOI:10.1111/vcp.12804] [PMID]
- Sasikala, M., Selvaraj, J., Ahamad, D. B., & Prasath, N. B. (2018). Xanthoma in a Japanese quail. *The Indian Veterinary Journal*, 95(04), 85–86. [Link]
- Schmidt, R. E., Reavill, D. R., & Phalen, D. N. (2015). Integument. In: R. E. Schmidt, D. R. Reavill, & D. N. Phalen (Eds.), *Pathology of pet and aviary birds* (pp: 237–262). New Jersey: John Wiley & Sons, Inc. [DOI:10.1002/9781118828007.ch11]
- Shokrpour, S., Asghari Baghkheirati, A., Yazdani, A., & Razmyar, J. (2019). Cutaneous xanthogranuloma associated with klebsiellapneumonia in a budgerigar (*Melopsittacus undulatus*). *Veterinary Research Forum: An International Quarterly Journal*, 10(4), 365–367. [DOI:10.30466/vrf.2019.102621.2445] [PMID] [PMCID]
- Souza, M. J., Johnstone-McLean, N. S., Ward, D., & Newkirk, K. (2009). Conjunctival xanthoma in a blue and gold macaw (*Ara ararauna*). *Veterinary Ophthalmology*, 12(1), 53–55. [DOI:10.1111/j.1463-5224.2009.00674.x] [PMID]
- Stacy, N. I., Pendl, H., & Wencel, P. M. (2021). Reptiles and birds. In: L. C. Sharkey, M. J. Radin, & D. Seelig (Eds.), *Veterinary Cytology* (pp. 828–868). New Jersey: John Wiley & Sons, Inc. [DOI:10.1002/9781119380559.ch61]
- Trupkiewicz, J., Garner, M. M., & Juan-Sallés, C. (2018). Passeriformes, caprimulgiformes, coraciiformes, piciformes, bucceriformes, and apodiformes. In: K. A. Terio, D. McAloose, & J. St. Leger (Eds.), *Pathology of wildlife and zoo animals* (pp. 799–823). Amsterdam: Elsevier. [DOI:10.1016/B978-0-12-805306-5.00033-X]

## مطالعه موردی

زانتوگرانولومای زیرجلدی در ناحیه تیبیوتارسال یک کاکادو (*Eolophus roseicapilla*): گزارش یک مورد\*فرهنگ ساسانی<sup>۱</sup>، دیبا گلچین<sup>۱</sup>، محمدیاسان بنگش<sup>۲،۳</sup>، سهیل خراسانی نژاد<sup>۴</sup>، ساناز بنی فضل<sup>۲</sup>

۱. گروه پاتولوژی، دانشکده دامپزشکی، دانشگاه تهران، تهران، ایران.

۲. بخش جراحی، بیمارستان حیوانات خانگی اکسیژن، تهران، ایران.

۳. گروه علوم بالینی، دانشکده دامپزشکی دانشگاه مونترال، مونترال، کانادا.

۴. بخش بیماری‌های پرندگان زینتی، بیمارستان حیوانات خانگی اکسیژن، تهران، ایران.

Use your device to scan and read the article online

**How to Cite This Article** Sasani, F., Golchin, D., Bangash, M. Y., Khorasaninejad, S., & Banifazl, S. (2024). Tibiotarsal Subcutaneous Xanthogranuloma in a Rose-breasted Cockatoo (*Eolophus roseicapilla*): A Case Report. *Iranian Journal of Veterinary Medicine*, 18(1), 151-158. <http://dx.doi.org/10.32598/ijvm.18.1.1005267>doi <http://dx.doi.org/10.32598/ijvm.18.1.1005267>

## چکیده



**زمینه مطالعه:** زانتوگرانولوما (زانتوما) ضایعه‌ای نادر، غیرعفونی، گرانولوماتوز و زرد رنگ است که قوامی نرم دارد. هیپرکلیسترولمی و هیپرلیپیدمی علل زمینه‌ساز بروز این ضایعه‌اند. زانتوما در مهرداران و انسان‌ها گزارش شده است. گزارش پیش‌رو زانتوگرانولومای پوستی ناحیه تیبیوتارسال را در یک طوطی سینه‌صورتی (کاکادو) ۵ ساله که با رژیم غذایی پرچربی تغذیه شده است، ارائه می‌دهد. بیهوشی با ایزوفلوران از طریق ماسک صورت متصل به دستگاه بیهوشی Ohmeda القا شد. توده به روش جراحی برداشته شد و به منظور تشخیص دقیق برای هیستوپاتولوژی ارسال شد. بافت در فرمالین بافر خنثی ۱۰ درصد تثبیت شد و مقاطع بافتی برای رنگ‌آمیزی هماتوکسیلین و ائوزین (H&E) پردازش شدند. در بررسی هیستوپاتولوژیک اسلایدهای روتین H&E، ماکروفاژهای واکنش‌دهنده و دیوسلول‌های چند هسته‌ای، شکاف‌های کلاسترولی و ارتشاح هتروفیل‌ها مشاهده شد. رنگ‌آمیزی اختصاصی Oil Red O بر روی مقاطع انجمادی با هدف نشان دادن تجمع داخل سلولی و خارج سلولی چربی انجام شد. زانتوگرانولوما به بافت‌های اطراف تهاجم می‌کند. بنابراین، برداشتن کامل توده به روش جراحی ضروری است. وضعیت بیمار به مدت ۱ ماه به دقت بررسی شد و اثری از بازگشت ضایعه مشاهده نشد، اما بیمار به دلیل ابتلا به اختلالات تنفسی تلف شد. اعتقاد بر این است که استرس و مصرف خوراک پرچرب از عوامل مستعدکننده ایجاد زانتوگرانولوما در این پرنده بوده‌اند.

کلیدواژه‌ها: کاکادو، ناحیه تیبیوتارسال، زانتوگرانولوما، هیستوپاتولوژی، Oil Red O

تاریخ دریافت: ۱۵ بهمن ۱۴۰۱

تاریخ پذیرش: ۲۷ اسفند ۱۴۰۱

تاریخ انتشار: ۱۱ دی ۱۴۰۲

## \* نویسنده مسئول:

دکتر فرهنگ ساسانی

نشانی: تهران، دانشگاه تهران، دانشکده دامپزشکی، گروه پاتولوژی.

تلفن: +۹۸ ۶۱۱۱۷۰۶۰ (۲۱)

رایانامه: [fsasani@ut.ac.ir](mailto:fsasani@ut.ac.ir)

This Page Intentionally Left Blank