

Original Article

Effects of *Spirulina platensis* on Iron Oxide Nanoparticles Induced-oxidative Stress and Liver Damage in Grey Mullet (*Mugil cephalus*)Omid Koohkan¹, *Hassan Morovvati¹, Ali Taheri Mirghaed²

1. Department of Basic Sciences, Faculty of Veterinary Medicine, University of Tehran, Tehran, Iran.

2. Department of Aquatic Health and Diseases, Faculty of Veterinary Medicine, University of Tehran, Tehran, Iran.



How to Cite This Article Koohkan, O., Morovvati, H., Taheri Mirghaed, A. (2023). Effects of *Spirulina platensis* on Iron Oxide Nanoparticles Induced-oxidative Stress and Liver Damage in Grey Mullet (*Mugil cephalus*). *Iranian Journal of Veterinary Medicine*, 17(1): 75-86. <http://dx.doi.org/10.32598/ijvm.17.1.1005284>

doi <http://dx.doi.org/10.32598/ijvm.17.1.1005284>



ABSTRACT

Background: Nanoparticles are increasingly exposed to ecosystems and people due to their large-scale manufacture and usage. The use of nanomaterials has increased their discharge into the aquatic environment.

Objectives: This research evaluated the protective effect of *Spirulina platensis* against liver damage and oxidative stress in grey mullet (*Mugil cephalus*) after exposure to iron oxide nanoparticles.

Methods: Juvenile grey mullets were randomly classified into 12 equal groups: Group 0, 96h control group; Group 1, 60 days control group; Group 2, iron oxide nanoparticles (IONPs) at 15mg/kg for 96h; Group 3, IONPs at 15mg/kg for 60 days; Group 4, *S. platensis* at 300mg/kg for 96h; Group 5, *S. platensis* at 300mg/kg for 60 days; Group 6, IONPs at 15mg/kg+*S. platensis* at 300mg/kg for 96h; Group 7, IONPs at 15mg/kg+*S. platensis* at 300mg/kg for 60 days; Group 8, IONPs at 15mg/kg (for 2 weeks) followed by *S. platensis* at 300mg/kg for 96h; Group 9, IONPs at 15mg/kg (for 2 weeks) followed by *S. platensis* at 300mg/kg for 60 days; Group 10, *S. platensis* at 300mg/kg (for 2 weeks) followed by IONPs at 15mg/kg for 96h; Group 11, *S. platensis* at 300mg/kg (for 2 weeks) followed by IONPs at 15mg/kg for 60 days. At the end of the experiment, samples of the liver were extracted and subjected to analyses to measure reduced glutathione (GSH), superoxide dismutase (SOD), catalase (CAT), and malondialdehyde (MDA).

Results: MDA levels in the liver were shown to have dramatically risen in the current investigation, but antioxidant SOD and GSH activity in the IONPs-treated group had significantly reduced compared to the controls. When compared to fish solely treated with IONPs, *S. platensis* treatment dramatically reduced liver MDA and CAT activity and raised SOD and GSH.

Conclusion: All prior metrics significantly improved when IONPs-induced liver damage in fish was prevented by spirulina. By scavenging free radicals, reducing inflammation, and restoring endogenous antioxidant defense systems, *S. platensis* therapy has a protective effect in the liver of grey mullet against damage and oxidative stress in the IONPs.

Keywords: Antioxidant, Iron oxide nanoparticles, Liver, *Mugil cephalus*, *Spirulina platensis*

Article info:

Received: 24 Jul 2022

Accepted: 14 Sep 2022

Publish: 01 Jan 2023

* Corresponding Author:

Hassan Morovvati

Address: Department of Basic Sciences, Faculty of Veterinary Medicine, University of Tehran, Tehran, Iran.

Phone: +98 (21) 61117009

E-mail: hmorovvati@ut.ac.ir

1. Introduction

Because of their capacity to target a specific spot inside the body, iron oxide nanoparticles (IONPs) have been suggested for various applications (Mody et al., 2014). Providing medicine or gene, enhancing contrast in magnetic resonance imaging (MRI), separating cells, immobilizing proteins, and so on (Vidya and Chitra, 2019; Yarjanli et al., 2017). Six distinct types of iron oxide are known to exist; they include wustite (FeO), hematite (α -Fe₂O₃), β -Fe₂O₃, ϵ -Fe₂O₃, maghemite (γ -Fe₂O₃), and magnetite (Fe₃O₄) (Cornell and Schwertmann, 2003). Natural sources of nano-sized iron oxides include volcanoes and forest fires, where they are produced as magnetite and maghemite crystalline formations. Many IONPs are intentionally created and employed in many applications (Vidya and Chitra, 2019). In biomedical applications, magnetite (Fe₃O₄) and maghemite (Fe₂O₃) are widely utilized. Both compounds' physicochemical characteristics are similar (Estelrich et al., 2015).

Metal removal from aqueous solutions and environmental cleanup employ iron oxide nanoparticles made from magnetite and maghemite (Grover et al., 2012). Due to their widespread manufacturing and usage, nanoparticle exposure to ecosystems and people has increased. There are four ways that nanoparticles may come into contact with living things: via the air, water or food, dermal contact, and sediment deposition (Vidya and Chitra, 2019). Applications of nanomaterials have increased their release into aquatic environments. The primary means by which nanoparticles enter aquatic environments include effluents from wastewater treatment facilities, during use and transit, and runoff from roofs and other roof-related activities (Garner and Keller, 2014). The hydrodynamic radius and surface charge of nanoparticles influence the accessibility of tissues and their absorption by cells when it reaches aquatic species. IONPs are digested after being absorbed by cells, releasing free iron ions into the cells (Malvindi et al., 2014). Iron deposition in the targeted tissue due to the widespread use of IONPs may be hazardous, affect cellular functions and metabolism, and cause significant alterations in the physiology, morphology, and behavior of animals exposed to it. Because of the great biocompatibility of iron oxide nanoparticles, they may readily interact with biomolecules such as proteins, lipids, and nucleic acids (Gokduman et al., 2018).

Iron oxide exposure has been linked to changes in hematological, biochemical, ionoregulatory, and enzymological parameters as well as mortality, delayed hatching, and malformation in Indian major carp, zebrafish, and Labeo rohita (Zhu et al., 2012; Keerthika et al., 2017). Metals may be linked to oxidative tissue damage because they serve as catalysts in oxidative processes (Badi et al., 2022). Exogenous chemicals have the potential to generate highly reactive oxygen species (ROS), which may oxidize biomolecules and cause cell death and tissue damage. Most biomolecules, including proteins, lipids, and lipoproteins, may react with ROS. Malondialdehyde (MDA) indicates oxidative stress in cells and tissues because lipid peroxidation is a well-established mechanism of cellular harm. MDA testing is often used as a lipid peroxidation biomarker. In both people and model systems, higher lipid peroxidation levels have been linked to several disorders.

Detoxification mechanisms, including antioxidant responses like reduced glutathione (GSH), superoxide dismutase (SOD), and catalase (CAT), are triggered by oxidative stress (Kim and Kang, 2015; Kim et al., 2017). Therefore, the reactions of fish exposed to metals to antioxidants may be a sensitive measure of oxidative stress. The most popular and generally accessible spirulina species is *S. platensis* (*Arthrospira platensis*), which is edible and has great nutritional and medicinal properties (Hussein et al., 2019). Spirulina or *S. platensis* contains essential fatty acids, polysaccharides, glycolipids, sulfolipids, vitamins, proteins (up to 70% of dry weight), lipids (5%-8% of dry weight), carbohydrates (up to 14%), some vital minerals (like calcium, iron, zinc, magnesium, manganese, and selenium), carbohydrates (up to 14%), and essential minerals (Hussein et al., 2019). Due to the presence of enzymatic and non-enzymatic antioxidants that mitigate the effects of reactive oxygen species, spirulina prevents cell damage (Frag et al., 2016). Carotenoids, tocopherols (TOH), ascorbic acid, glutathione (GSH), and chlorophyll are examples of non-enzymatic antioxidant compounds.

In contrast, SOD, CAT, glutathione peroxidase (GPX), peroxiredoxin (PrxR), and ascorbate peroxidase (AXP) are examples of enzymatic antioxidants (Abd El-Baky et al., 2009). The current research aimed to evaluate the histological and biochemical changes caused by IONPs in important tissues such as fish liver and grey mullet since the number of nanoparticles exposed in the aquatic environment has been steadily increasing. The research assessed the antioxidant and healing properties of spirulina therapy both before and after IONP exposure.

2. Materials and Methods

Iron oxide nanoparticle

IONPs were provided by ARMINANO Co. in Iran. The particles were pre-characterized before the experiment (SEM: TESCAN, MIRA3-LMU). They were pure, and the Mean±SD size was confirmed as 17.45±2.88nm. The test dose of nanoparticles (15mg/kg) was chosen based on [Vidya and Chitra \(2019\)](#).

Dried *S. platensis* powder

The substances that an aquarium system produces as dried algae powder (spirulina), are described below (Karaj, Iran). Spirulina was produced, dried at 32°C, and mixed to create a homogenized powder. Based on [Karadeniz et al. \(2009\)](#) study, a dose of *S. platensis* (300 mg/kg) was chosen.

Experimental design

Juvenile fish of the grey mullet (*Mugil cephalus*) (Mean±SD weight: 22.79±1.14g) and (Mean±SD height: 123.22±1.94mm) were caught from the fish farm of Chabahar Science Research Institute, southeast of Iran, in September 2020. The obtained fish was immediately transported to the Fish Biology Laboratory at Chabahar Maritime University.

They were kept in 40-L plastic tanks of seawater with 10 fish each, with excellent aeration and light, for two weeks before the experimental investigation to acclimate them to the laboratory environment. Before the study, the experimental fish were given commercial marine fish pellets at a rate of 5% of wet weight twice daily at 10:00 and 15:00 to assist the fish in adjusting to their new habitat. Feces and leftover food were aspirated, and there was a twice-weekly water exchange. Standard water temperature (26°C±1.4°C), total dissolved solids (TDS) (41.92±0.64) ppm, salinity (39.85±0.38) ppt, the dissolved oxygen concentration of water (70%) and pH (7.8 to 8.24) were maintained.

Fish were grouped into 12 as follows:

Group 0: control group, toxicant-free (96h, short term)

Group 1: control group, toxicant-free (60d, long term)

Group 2: IONPs at 15mg/kg for 96h (short term)

Group 3: IONPs at 15mg/kg for 60d (long term)

Group 4: *S. platensis* at 300mg/kg for 96h (short term)

Group 5: *S. platensis* at 300mg/kg for 60d (long term)

Group 6: IONPs at 15mg/kg+S. *platensis* at 300mg/kg for 96h (short term)

Group 7: IONPs at 15mg/kg+S. *platensis* at 300mg/kg for 60d (long term)

Group 8: IONPs at 15mg/kg (for 2 weeks) followed by *S. platensis* at 300mg/kg for 96h (short term)

Group 9: IONPs at 15mg/kg (for 2 weeks) followed by *S. platensis* at 300mg/kg for 60d (long term)

Group 10: *S. platensis* at 300mg/kg (for 2 weeks) followed by IONPs at 15mg/kg for 96h (short term)

Group 11: *S. platensis* at 300 mg/kg (for 2 weeks) followed by IONPs at 15mg/kg for 60d (long term)

Fish were captured after each treatment session using small dip nets to minimize stress on the animal, and the liver tissues were removed for histological analysis.

General histology

After collecting tissues, they were fixed in buffered formalin at a 10% concentration. Tissues were dehydrated in progressively higher concentrations of alcohol and then cleaned in xylene until they were transparent. To thoroughly eliminate xylene, tissues were placed in molten paraffin wax for one hour before being impregnated with wax. To create sections with a thickness ranging from 4 to 6 microns, blocks were cut in a rotary microtome. Hematoxylin and eosin were used to stain the sections, which were then examined under the microscope ([Rahmati et al., 2022](#)). Under a light microscope (CX21; Olympus, Tokyo, Japan), the structural changes to the liver were examined and contrasted with the control tissue. Dino-Lite digital lenses were used for the photomicrographs, and DinoCapture software was used for the survey.

Tissue collection

During the experiment (days 3, 60), fish were anesthetized with carnation (*Dianthus*) powder (5g/L), and their liver tissues were separated and collected in aluminum foil and stored at -80°C until use.

Table 1. Tissue lesions in the liver of gray mullet at different treatments

Variables	G0-G1	G2	G3	G4	G5	G6	G7	G8	G9	G10	G11
Hyperemia	-	++	+++	-	±	-	+	++	+	-	±
MMC	+	++	+++	-	+	+	++	++	+	-	+
Vacuolation	-	-	++	-	-	-	+	+	±	-	±
Necrosis	-	-	+	-	-	-	-	±	-	-	-

-: No lesion; ±: Lesion <10%; +: Lesion <20%; ++: Lesion <60%; +++: Lesion >60%.

Determination of stress oxidative and antioxidant in liver

The isolated sections of the liver were immediately washed in ice-cold saline. It is then homogenized in potassium phosphate 50mM (pH=7.4) and reaches a concentration of 10%. They were then centrifuged at 4000 rpm for 15 minutes at 4°C. The obtained supernatant is used to measure spectrophotometrically and ELISA applying commercial kits based on the manufacturer's instructions.

Statistical analysis

All data were presented as Mean±SEM and analyzed in SPSS software, version 26. Variance comparisons between the means of the control and experiment treatment data were made by 1-way ANOVA. Tukey's post hoc test was used to compare the median of each group. The difference in mean values among the groups and histological analysis was studied utilizing a nonparametric test. $P \leq 0.05$ was regarded as significant.

3. Results

Effects on MDA Levels

MDA level in the liver was considerably higher in the IONPs groups (48%) compared to the control ($P \leq 0.05$). The administration of spirulina with IONPs for 60 days considerably decreased the levels of MDA in the liver compared with the IONPs alone group, which means its protective and healing impacts (Figure 1).

Effects on GSH levels

IONPs caused a considerable depletion in GSH levels in the liver (60%) compared with the control group. *S. platensis* treatment with IONPs did produce a considerable increase in the level of GSH in the liver (Figure 2).

Effects on CAT levels

IONPs administration considerably increased the levels of CAT by 48% in the liver compared with the

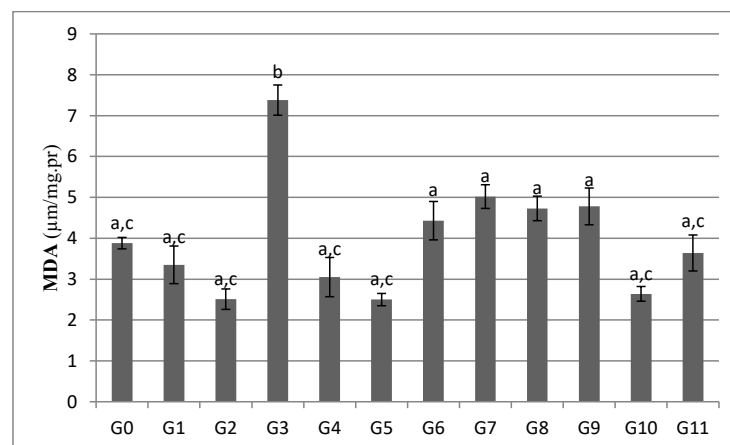


Figure 1. Effects of *S. platensis* on hepatic Malondialdehyde (MDA) levels in Iron Oxide Nanoparticles (IONPs)-treated fish (*mugil cephalus*)

Each column represents the Mean±SE. for 10 fish in each group. Different letters showed a statistical difference between the groups ($P < 0.05$).

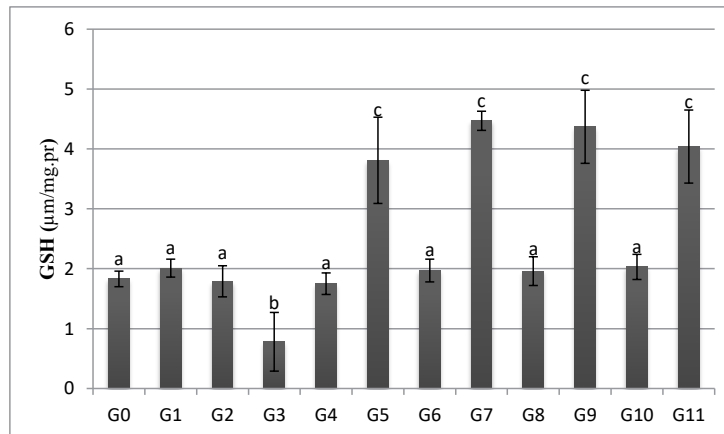


Figure 2. Hepatic reduced glutathione (GSH) levels in the control, Iron Oxide Nanoparticles (IONPs), and *S. platensis*-treated grey mullet

Each column represents the Mean±SE. for 10 fish in each group. Different letters showed a statistical difference between the groups ($P<0.05$).

control group ($P\leq 0.05$). Treatment of fish with *S. platensis* reduced the levels of CAT in liver compared with the IONPs group, but have no significant differences with control group (Figure 3).

Effects on SOD levels

IONPs administration reduced the levels of SOD by 41% in the liver compared to the control group. Treatments of fish with *S. platensis* increased the levels of SOD by 173% in the liver compared to the control group ($P\leq 0.05$). The administration of spirulina with IONPs for 60 days caused a significant increase in the levels of SOD in the liver compared with the IONPs group (Figure 4).

Histopathological changes

The histopathology of the livers in the control group was normal (Figure 5a). Liver sections of animals treated with IONPs for 3 days, revealed a rise of the melanomacrophage centers and hyperemia (Figure 5b), which was more severe in the 60-day group (Figure 6a) (Figures 6b, 7a). A substantial degree of vacuole degradation was detected in several samples (Figure 7a, 7b). It is interesting to note that *S. platensis* therapy stopped the histopathological changes caused by IONPs. Lesions seen in the livers of *S. platensis* plus IONPs intoxicated animals were much less than those seen in the IONPs alone group (Figure 8a, 8b). The severity of the liver lesions seen in the grey mullet’s liver after various treatments are shown in Table 1.

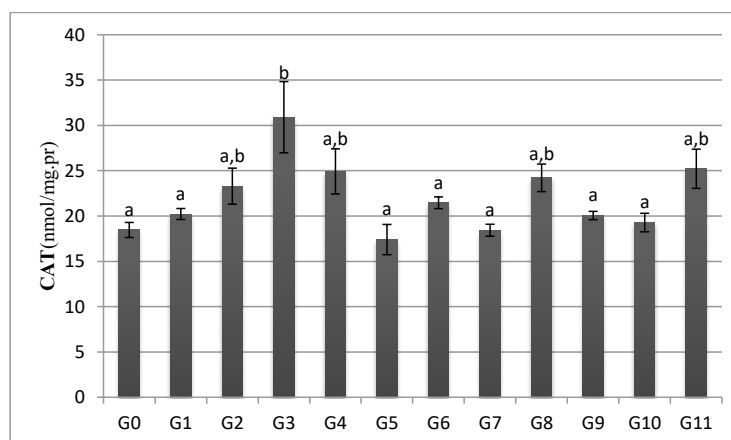


Figure 3. Hepatic catalase (CAT) levels in the control, iron oxide nanoparticles (IONPs), and *S. platensis*-treated grey mullet

Each column represents the Mean±SE. for 10 fish in each group. Different letters showed a statistical difference between the groups ($P<0.05$).

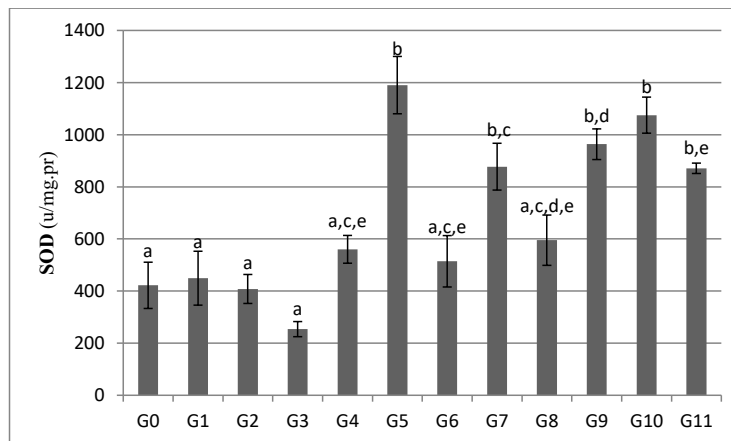


Figure 4. Hepatic superoxide dismutase (SOD) levels in the control, iron oxide nanoparticles (IONPs), and *S. platensis*-treated grey mullet

Each column represents the Mean \pm SE. for 10 fish in each group. Different letters showed statistical differences between the groups ($P < 0.05$).

4. Discussion

Numerous studies have revealed both in vitro and in vivo toxicity of IONPs. However, some studies report that IONPs are not poisonous and may even be beneficial (Yarjanli et al., 2017). Enzymatic activity that removes iron ions from their surface may produce ROS (Jarockyte et al., 2016). This study aimed to examine the hepatic toxic effects of IONPs in grey mullet and how *S. platensis* could mitigate these effects. Ions produced by IONPs may participate in Fenton's reaction and produce ROS from superoxide and H_2O_2 (Dashtipour et al., 2015). IONPs may harm the balance between the body's antioxidant and oxidant defense mechanisms (Elmallah et al., 2017). Numerous physiological processes, including DNA synthesis, cell cycle control, transcription factor activation, mitochondrial

permeability transition, and apoptosis, are impacted by oxidative stress (Yarjanli et al., 2017).

The levels of oxidative stress indices and MDA in the liver were dramatically elevated in the IONPs-treated group, whereas the activity of antioxidant SOD and GSH in the liver was significantly lowered. The mean levels of MDA and CAT activities in the liver rose considerably in the IONPs group compared to the control group. Compared to fish treated with IONPs alone, spirulina administration considerably lowered liver MDA and CAT activity. These findings demonstrated that SOD and GSH prevent producing oxygen free radicals in liver tissue (Karadeniz et al., 2009). These reductions may indirectly result in oxidative DNA or mitochondrial damage in cells (Yarjanli et al., 2017). However, the MDA levels of fish given IONPs containing *S. platensis* reverted to normal. Therefore, it is hypothesized that *S. platensis* inhibits lipid peroxidation due to its

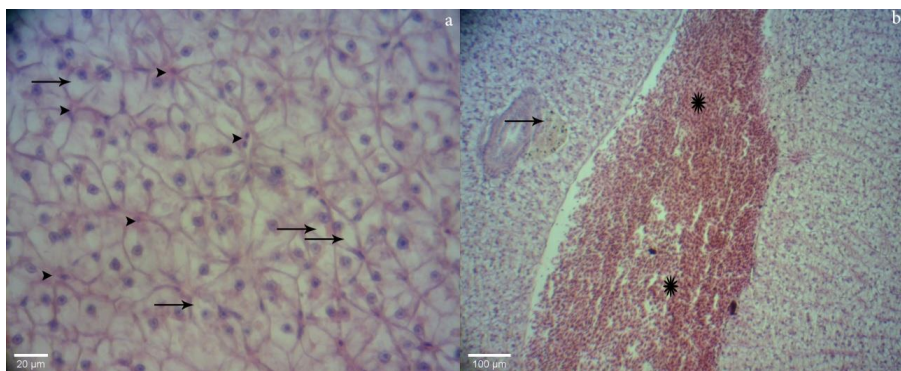


Figure 5. a) Normal liver structure in the control grey mullet, high lipid in hepatocytes seen (arrows) and sinusoids containing red blood cells (arrowheads), (H&E, 40x); b) liver of fish exposed for 3 days to iron oxide nanoparticles indicating hyperemia (stars) and melanomacrophage center (arrow), (H&E, 10x)

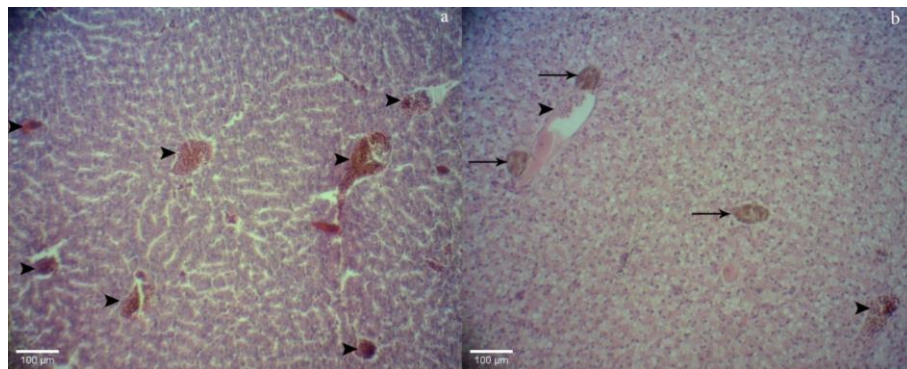


Figure 6. Liver of gray mullet exposed to iron oxide nanoparticles for 60 days (H&E, 10x)

a) hyperemia (arrowheads) and swollen sinusoids; b) melanomacrophage centers (arrows) shown a sharp increase compared with 3 days fish and dilated blood vessels (arrowheads)

free radical scavenging function (Amin et al., 2006). According to Amin et al. (2006), *S. platensis* protects against hepatocyte-induced lipid peroxidation and has an inhibitory effect on cytochrome P450-associated monooxygenase activities.

The mean values of liver GSH concentration were considerably lower in the IONPs group compared to the control group. Compared to the control and IONPs groups, treatment with spirulina dramatically improved liver GSH levels. GSH is the most prevalent antioxidant in all cellular compartments (Darenskaya et al., 2018). GSH serves essential functions in an organism, such as

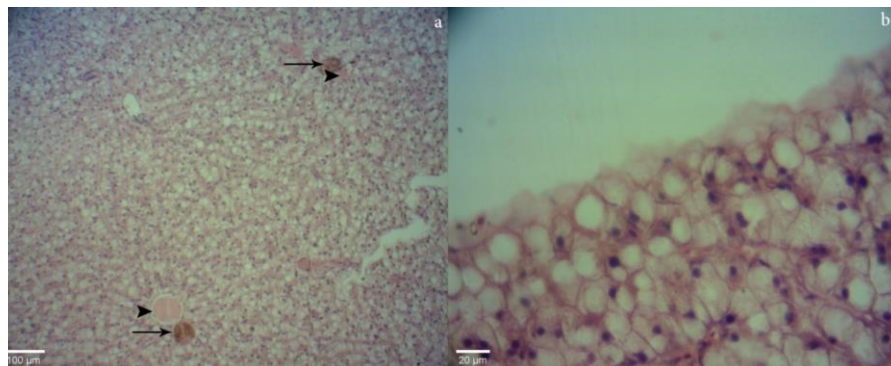


Figure 7. Liver of gray mullet exposed to iron oxide nanoparticles for 60 days

a) severe vacuolation, hyperemia (arrowheads), and melanomacrophage center (arrows) (H&E, 10x); b) vacuolization in the liver of fish exposed to iron oxide nanoparticles (H&E, 40x)

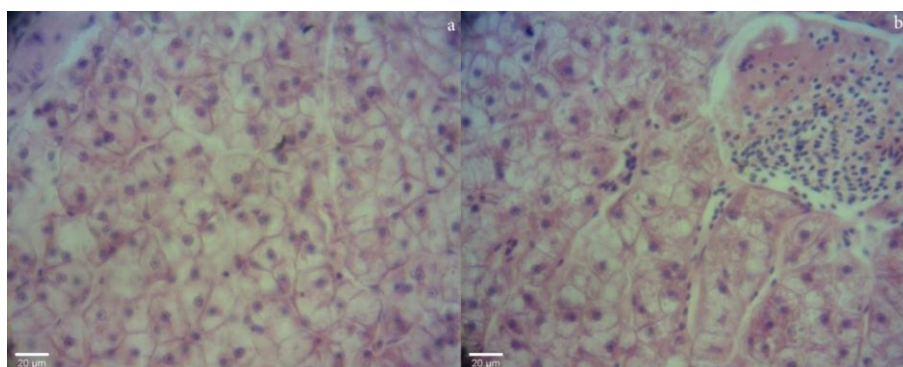


Figure 8. Liver of grey mullet treated with *S. platensis* preventing the iron oxide nanoparticles (IONPs)-induced histopathological changes

a) the lesions noted in the livers of *s. platensis* plus IONPs intoxicated animals greatly reduced and noted regeneration; b) liver with normal structure of hepatocytes but with hyperemia.

eliminating xenobiotics (Karadeniz et al., 2009). According to Nunez et al. (2012), there is a correlation between iron buildup, low GSH levels, and oxidative stress. The buildup of iron decreases GSH levels and induces oxidative stress. The low amount of GSH increases the level of transferrin receptor (TfR), which transports iron into the cell and facilitates iron buildup (Karadeniz et al., 2009). Based on the information presented above, we argue that when iron buildup occurs, low GSH contributes to further iron accumulation and oxidative stress production. The liver GSH level in the IONPs-treated group was considerably lower than in the control group. Pongrac et al. (2016) revealed that the GSH level of cells exposed to IONPs decreased significantly. However, the same parameter for IONPs was elevated in the *S. platensis*-treated groups compared to the other groups. It demonstrates that this scenario is the consequence of the antioxidant properties of *S. platensis*. The *S. platensis* administration contributes to the maintenance of GSH levels. Karadeniz and Cemek (2006) reported the preventive activity of *S. platensis* against lead-induced plasma lipid peroxidation and oxidative damage in rats.

The findings were consistent with those of Hussein et al. (2019), who indicated that oxidative stress and apoptosis might play a role in neurotoxicity, which disrupted GSH production. In this research, a decrease in GSH levels may be attributable to its conjugation with certain metabolites (Wu & Dhanasekaran, 2020). Hassan et al. (2012), who investigated spirulina's efficacy in combating oxidative stress in rats, found a comparable rise in GSH levels. Supplementation with spirulina significantly decreased aflatoxin-induced oxidative stress, as shown by an increase in GSH content. Abd El-Baky et al. (2009) noted that under oxidative stress, *S. platensis* maintained the activity of cellular antioxidant enzymes and raised the quantity of reduced glutathione in these cells.

In addition, these biochemical findings are complemented by the histological study of fish livers. IONPs brought about vacuolar degeneration, increased melanomacrophage centers (MMCs), and hyperemia in liver tissue. *S. platensis* demonstrated liver cell protection and regeneration. The synergistic impact of hepatoprotective action and antioxidant activity reduces the beginning and progression of hepatocellular disorders. Because of IONPs, membrane function abnormalities that result in a huge inflow of water and Na⁺ may cause the swelling of sinusoids (Abdelhalim and Jarrar, 2012). Degeneration is caused by ion and fluid homeostasis that increase intracellular water volume (Schrand et al., 2010). The vacuolated cytoplasm of the

hepatocytes of fish treated with IONPs may indicate acute and subacute liver damage caused by these NPs. Some investigations show that hepatic dysplasia and carcinomatous lesions exhibit nuclear polymorphism (Abdelhalim and Jarrar, 2012). These findings imply that IONPs may interact with proteins and enzymes of the hepatic interstitial tissue, interfering with the antioxidant defense system and leading to ROS production, which may mimic an inflammatory response (Abdelhalim and Jarrar, 2012).

Some swollen hepatocytes that were exposed to IONPs had a fatty alteration. The fatty change in hepatocytes may be related to lipid peroxidation, which causes endoplasmic damage and lipoprotein separation and indicates improper fat metabolism (Abdelhalim and Jarrar, 2012). Changes caused by IONPs in our study may suggest liver toxicity. Some hepatocytes of fish treated with IONPs displayed relative necrosis. Apoptotic modification may be accompanied by organelle swelling, particularly mitochondria, endoplasmic reticulum, and rupture of lysosomes, which may result in amorphous eosinophilic cytoplasm as the initial sign in the sequence of hepatocytes necrosis preceding the shrinking and dissolution of nuclei (Abdelhalim and Jarrar, 2012). Changes seen in hepatocytes may indicate the oxidative stress caused by glutathione deficiency.

5. Conclusions

According to the data, IONPs are rather hazardous, but spirulina improved all parameters and protected liver damage and oxidative stress after exposure to IONPs in grey mullet. The protective effect of spirulina may be mediated by increasing antioxidants. Therefore, spirulina can be a therapeutic agent in liver damage induced by IONPs and other diseases related to oxidative stress.

Ethical Considerations

Compliance with ethical guidelines

All ethical principles are considered in this article. The participants were informed of the purpose of the research and its implementation stages. They were also assured about the confidentiality of their information and were free to leave the study whenever they wished, and if desired, the research results would be available to them. A written consent has been obtained from the subjects. principles of the Helsinki Convention was also observed.

Funding

The paper was extracted from the PhD dissertation of the first author, Department of Basic Sciences, Faculty of Veterinary Medicine [University of Tehran](#).

Authors' contributions

All authors equally contributed to preparing this article.

Conflict of interest

The authors declared no conflict of interest.

Acknowledgments

This research was supported by [University of Tehran](#). We thank Chabahar Maritime University and the Department of Marine Biology for their help and support.

References

- Abd El-Baky, H. H., El Baz, F. K., & El-Baroty, G. S. (2009). Enhancement of antioxidant production in *Spirulina platensis* under oxidative stress. *Acta Physiologiae Plantarum*, 31, 623-631. [\[Link\]](#)
- Abdelhalim, M. A., & Jarrar, B. M. (2012). Histological alterations in the liver of rats induced by different gold nanoparticle sizes, doses and exposure duration. *Journal of nanobiotechnology*, 10, 5. [\[PMID\]](#) [\[PMCID\]](#)
- Amin, A., Hamza, A. A., Daoud, S., & Hamza, W. (2006). Spirulina protects against cadmium-induced hepatotoxicity in rats. *American Journal of Pharmacology and Toxicology*, 1(2), 21-25. [\[DOI:10.3844/ajptsp.2006.21.25\]](#)
- Badi, N., Fazelipour, S., Naji, T., Babaei, M., & Kalantari Hesar, A. (2022). Histomorphometric and biochemical study of liver and thyroid hormones following administration of MoO₃ nanoparticles in female rats. *Iranian Journal of Veterinary Medicine*, 16(2), 188-201. [\[Link\]](#)
- Cornell, R. M., & Schwertmann, U. (2003). *The iron oxides: Structure, properties, reactions, occurrences, and uses*. Weinheim: Wiley-VCH. [\[Link\]](#)
- Darenskaya, M. A., Kolesnikov, S. I., Rychkova, L. V., Grebenkina, L. A., & Kolesnikova, L. I. (2018). Oxidative stress and antioxidant defense parameters in different diseases: Ethnic aspects. *Free Radical Biology and Medicine*, 120(Supplement 1), S60. [\[DOI:10.1016/j.freeradbiomed.2018.04.199\]](#)
- Dashtipour, K., Liu, M., Kani, C., Dalaie, P., Obenaus, A., & Simmons, D., et al. (2015). Iron accumulation is not homogeneous among patients with Parkinson's disease. *Parkinson's Disease*, 2015, 324843. [\[PMID\]](#) [\[PMCID\]](#)
- El-Baky, A., Hanaa, H., El Baz, F. K., & El-Baroty, G. S. (2009). Enhancement of antioxidant production in *Spirulina platensis* under oxidative stress. *Acta physiologiae plantarum*, 31(3), 623-631. [\[Link\]](#)
- Elmallah, M., Elkhadragey, M. F., Al-Olayan, E. M., & Abdel-Moneim, A. E. (2017). Protective effect of fragaria ananassa crude extract on cadmium-induced lipid peroxidation, antioxidant enzymes suppression, and apoptosis in rat testes. *International Journal of Molecular Sciences*, 18(5), 957. [\[PMID\]](#) [\[PMCID\]](#)
- Estelrich, J., Escribano, E., Queralt, J., & Busquets, M. A. (2015). Iron oxide nanoparticles for magnetically-guided and magnetically-responsive drug delivery. *International Journal of Molecular Sciences*, 16(4), 8070-101. [\[PMID\]](#) [\[PMCID\]](#)
- Farag, M. R., Alagawany, M., El-Hack, M. E. A., & Dhama, K. (2016). Nutritional and healthical aspects of Spirulina (Arthrospira) for poultry, animals and human. *International Journal of Pharmacology*, 12(1), 36-51. [\[DOI:10.3923/ijp.2016.36.51\]](#)
- Garner, K. L., & Keller, A. A. (2014). Emerging patterns for engineered nanomaterials in the environment: A review of fate and toxicity studies. *Journal of Nanoparticle Research*, 16, 2503. [\[Link\]](#)
- Gokduman, K., Bestepe, F., Li, L., Yarmush, M. L., & Usta, O. B. (2018). Dose-, treatment-and time-dependent toxicity of superparamagnetic iron oxide nanoparticles on primary rat hepatocytes. *Nanomedicine*, 13(11), 1267-1284. [\[PMID\]](#) [\[PMCID\]](#)
- Grover, V. A., Hu, J., Engates, K. E., & Shipley, H. J. (2012). Adsorption and desorption of bivalent metals to hematite nanoparticles. *Environmental Toxicology and Chemistry*, 31(1), 86-92. [\[DOI:10.1002/etc.712\]](#) [\[PMID\]](#)
- Hassan, A. M., Abdel-Aziem, S. H., & Abdel-Wahhab, M. A. (2012). Modulation of DNA damage and alteration of gene expression during aflatoxicosis via dietary supplementation of Spirulina (Arthrospira) and Whey protein concentrate. *Ecotoxicology and Environmental Safety*, 79, 294-300. [\[PMID\]](#)
- Hussein, S. A., Abd el-hamid, O. M., El-tawil, O. S., Laz, E. S., & Taha, W. M. (2019). Attenuating effect of *Spirulina platensis* against mycotoxin induced oxidative stress and liver damage in male albino rats. *International Journal of Pharma Sciences*, 9(2), 2039-2044. [\[Link\]](#)
- Jarockyte, G., Daugelaite, E., Stasys, M., Statkute, U., Poderys, V., & Tseng, T. C., et al. (2016). Accumulation and toxicity of superparamagnetic iron oxide nanoparticles in cells and experimental animals. *International Journal of Molecular Sciences*, 17(8), 1193. [\[PMID\]](#) [\[PMCID\]](#)
- Karadeniz, A., & Cemek, M. (2006). Protective effect of *Spirulina platensis* against lead toxication in rats. *Journal of Animal and Veterinary Advances*, 5(12), 1113-1116. [\[Link\]](#)
- Karadeniz, A., Cemek, M., & Simsek, N. (2009). The effects of Panax ginseng and *Spirulina platensis* on hepatotoxicity induced by cadmium in rats. *Ecotoxicology and Environmental Safety*, 72(1), 231-235. [\[PMID\]](#)
- Keerthika, V., Ramesh, R., & Rajan, M. R. (2017). Toxicity assessment of iron oxide nanoparticles in *Labeo rohita*. *International Journal of Fisheries and Aquatic Studies*, 5(4), 01-06. [\[Link\]](#)
- Kim, J. H., & Kang, J. C. (2015). The lead accumulation and hematological findings in juvenile rock fish *Sebastes schlegelii* exposed to the dietary lead (II) concentrations. *Ecotoxicology and Environmental Safety*, 115, 33-39. [\[DOI:10.1016/j.ecoenv.2015.02.009\]](#) [\[PMID\]](#)

- Kim, J. H., Oh, C. W., & Kang, J. C. (2017). Antioxidant responses, neurotoxicity, and metallothionein gene expression in juvenile Korean rockfish *Sebastes schlegelii* under dietary lead exposure. *Journal of Aquatic Animal Health*, 29(2), 112-119. [PMID]
- Malvindi, M. A., De Matteis, V., Galeone, A., Brunetti, V., Anyfantis, G. C., & Athanassiou, A., et al. (2014). Toxicity assessment of silica coated iron oxide nanoparticles and biocompatibility improvement by surface engineering. *PLoS one*, 9(1), e85835. [PMID] [PMCID]
- Mody, V. V., Cox, A., Shah, S., Singh, A., Bevins, W., & Parihar, H. (2014). Magnetic nanoparticle drug delivery systems for targeting tumor. *Applied Nanoscience*, 4, 385-392. [DOI:10.1007/s13204-013-0216-y]
- Núñez, M. T., Urrutia, P., Mena, N., Aguirre, P., Tapia, V., & Salazar, J. (2012). Iron toxicity in neurodegeneration. *Biomaterials*, 25(4), 761-776. [PMID]
- Pongrac, I. M., Pavičić, I., Milić, M., Brkić Ahmed, L., & Babić, M., et al. (2016). Oxidative stress response in neural stem cells exposed to different superparamagnetic iron oxide nanoparticles. *International Journal of Nanomedicine*, 11, 1701-1715. [PMID] [PMCID]
- Rahmati, M., Morovvati, H., & Abdi, R. (2022). Histomorphometric Analysis of Skin and Stress Indices of Nile Tilapia (*Oreochromis niloticus*) Exposed to Different Concentrations of Ammonia. *Iranian Journal of Veterinary Medicine*, 16(3), 288-297. [DOI:10.22059/IJVM.2022.337549.1005230]
- Schrand, A. M., Rahman, M. F., Hussain, S. M., Schlager, J. J., Smith, D. A., & Syed, A. F. (2010). Metal-based nanoparticles and their toxicity assessment. *Wiley Interdisciplinary Reviews: Nanomedicine and Nanobiotechnology*, 2(5), 544-568. [PMID]
- Vidya, P. V., & Chitra, K. C. (2019). Irreversible histopathological modifications induced by iron oxide nanoparticles in the fish, *Oreochromis mossambicus* (Peters, 1852). *Biological Forum - An International Journal*, 11(1), 01-06. [Link]
- Wu, X., & Dhanasekaran, S. (2020). Protective effect of leaf extract of *Abutilon indicum* on DNA damage and peripheral blood lymphocytes in combating the oxidative stress. *Saudi Pharmaceutical Journal : SPJ : The Official Publication of The Saudi Pharmaceutical Society*, 28(8), 943-950. [PMID] [PMCID]
- Yarjanli, Z., Ghaedi, K., Esmaili, A., Rahgozar, S., & Zarrabi, A. (2017). Iron oxide nanoparticles may damage to the neural tissue through iron accumulation, oxidative stress, and protein aggregation. *BMC Neuroscience*, 18(1), 51. [PMID] [PMCID]
- Zhu, X., Tian, S., & Cai, Z. (2012). Toxicity assessment of iron oxide nanoparticles in zebrafish (*Danio rerio*) early life stages. *PLoS One*, 7(9), 46286. [PMID]

مقاله پژوهشی

اثر اسپیرولینا پلاتنسیس بر استرس اکسیداتیو و آسیب کبدی ناشی از نانوذرات اکسید آهن در کفال خاکستری (*Mugil cephalus*)امید کوهکن^۱، *حسن مروتی^۲، علی طاهری میرقائد^۳

۱. گروه علوم پایه، دانشکده دامپزشکی، دانشگاه تهران، تهران، ایران.

۲. گروه بهداشت و بیماری‌های آبزیان، دانشکده دامپزشکی، دانشگاه تهران، تهران، ایران.

Use your device to scan and read the article online

**How to Cite This Article** Koohkan, O., Morovvati, H., Taheri Mirghaed, A. (2023). Effects of *Spirulina platensis* on Iron Oxide Nanoparticles Induced-oxidative Stress and Liver Damage in Grey Mullet (*Mugil cephalus*). *Iranian Journal of Veterinary Medicine*, 17(1): 75-86. <http://dx.doi.org/10.32598/ijvm.17.1.1005284>**doi** <http://dx.doi.org/10.32598/ijvm.17.1.1005284>

چکیده



زمینه مطالعه: به واسطه تولید و کاربرد فراوان نانوذرات، مواجهه انسان و اکوسیستم‌ها با آن افزایش یافته است. افزایش استفاده از نانوذرات منجر به بالا رفتن میزان ورود این مواد به محیط‌های آبی شده است.

هدف: مطالعه حاضر به منظور بررسی اثر محافظتی اسپیرولینا پلاتنسیس (*Spirulina platensis*) بر آسیب کبدی و استرس اکسیداتیو ناشی از نانوذرات اکسید آهن در کفال خاکستری (*Mugil cephalus*) انجام شد.

روش کار: ماهیان جوان کفال خاکستری به طور تصادفی در ۱۲ گروه مساوی تقسیم شدند: گروه ۰: کنترل ۹۶ ساعت، گروه ۱: کنترل ۶۰ روز، گروه ۲: ۱۵ میلی‌گرم به کیلوگرم وزن نانوذرات اکسید آهن به مدت ۹۶ ساعت، گروه ۳: ۱۵ میلی‌گرم به کیلوگرم وزن نانوذرات اکسید آهن به مدت ۶۰ روز، گروه ۴: ۳۰۰ میلی‌گرم به کیلوگرم وزن جلبک اسپیرولینا به مدت ۹۶ ساعت، گروه ۵: ۳۰۰ میلی‌گرم به کیلوگرم وزن جلبک اسپیرولینا به مدت ۶۰ روز، گروه ۶: ۱۵ میلی‌گرم به کیلوگرم وزن نانوذرات اکسید آهن به همراه ۳۰۰ میلی‌گرم به کیلوگرم وزن جلبک اسپیرولینا به صورت همزمان به مدت ۹۶ ساعت، گروه ۷: ۱۵ میلی‌گرم به کیلوگرم وزن نانوذرات اکسید آهن به همراه ۳۰۰ میلی‌گرم به کیلوگرم وزن جلبک اسپیرولینا به صورت همزمان به مدت ۶۰ روز، گروه ۸: ۱۵ میلی‌گرم به کیلوگرم وزن نانوذرات اکسید آهن به مدت ۲ هفته و سپس آغاز دریافت روزانه ۳۰۰ میلی‌گرم به کیلوگرم وزن جلبک اسپیرولینا به مدت ۹۶ ساعت، گروه ۹: ۱۵ میلی‌گرم به کیلوگرم وزن نانوذرات اکسید آهن به مدت ۲ هفته و سپس آغاز دریافت روزانه ۳۰۰ میلی‌گرم به کیلوگرم وزن جلبک اسپیرولینا به مدت ۶۰ روز، گروه ۱۰: ۳۰۰ میلی‌گرم به کیلوگرم وزن جلبک اسپیرولینا به مدت ۲ هفته و سپس آغاز دریافت ۱۵ میلی‌گرم به کیلوگرم وزن نانوذرات اکسید آهن به مدت ۹۶ ساعت، گروه ۱۱: ۳۰۰ میلی‌گرم به کیلوگرم وزن جلبک اسپیرولینا به مدت ۲ هفته و سپس آغاز دریافت ۱۵ میلی‌گرم به کیلوگرم وزن نانوذرات اکسید آهن به مدت ۶۰ روز، در پایان آزمایش، نمونه‌های بافت کبد جدا و برای تعیین گلوکوتائون احیا شده (GSH)، سوپراکسید دیسموتاز (SOD)، کاتالاز (CAT) و مالون دی‌الدهید (MDA) تجزیه و تحلیل شدند.

نتایج: در مطالعه حاضر، سطوح MDA در کبد به طور معنی داری افزایش یافت در حالی که فعالیت آنتی اکسیداتی SOD و GSH در کبد در گروه مواجهه شده با IONPs در مقایسه با گروه کنترل به طور معنی داری کاهش یافت. درمان با اسپیرولینا پلاتنسیس به طور معنی دار باعث کاهش فعالیت‌های MDA و CAT و افزایش SOD و GSH کبدی در مقایسه با ماهی‌های تحت درمان با IONPs شد.

نتیجه‌گیری نهایی: این نتایج به وضوح نشان داد که SOD و GSH در مهار تشکیل رادیکال‌های آزاد اکسیژن در بافت کبد نقش دارند. آسیب کبدی ناشی از IONPs در ماهیان محافظت شده با اسپیرولینا باعث بهبود معنادار در تمام پارامترهای قبلی شد. درمان با اسپیرولینا پلاتنسیس از طریق مهار رادیکال‌های آزاد و فعالیت‌های ضد التهابی و همچنین بازسازی مکانیسم‌های سیستم دفاعی آنتی اکسیدان‌های درون زه، اثر محافظتی در برابر صدمات کبدی و استرس اکسیداتیو در کبد ماهی‌های مسموم با IONPs نشان می‌دهد.

کلیدواژه‌ها: آنتی اکسیدان، نانوذرات اکسید آهن، کبد، کفال خاکستری، اسپیرولینا پلاتنسیس

تاریخ دریافت: ۰۲ مرداد ۱۴۰۱

تاریخ پذیرش: ۲۳ شهریور ۱۴۰۱

تاریخ انتشار: ۱۱ دی ۱۴۰۱

* نویسنده مسئول:

حسن مروتی

نشانی: گروه علوم پایه، دانشکده دامپزشکی، دانشگاه تهران، تهران، ایران،

تلفن: +۹۸ (۹۸) ۶۱۱۷۰۰۹

رایانامه: hmorovvati@ut.ac.ir

This Page Intentionally Left Blank