

Research Paper

Macro-anatomical Investigations on the Plexus Lumbosacralis of the Aksaray Malakli Dog



Muhammet Alperen Fidan^{1*}, Zekeriya Özüdoğru², Ramazan İlgün¹

1. Department of Veterinary Anatomy, Faculty of Veterinary Medicine, Aksaray University Aksaray, Turkey.

2. Department of Veterinary Anatomy, Faculty of Veterinary Medicine, Balıkesir University, Balıkesir, Turkey.



How to Cite This Article Fidan, M. A., Özüdoğru, Z., & İlgün, R. (2024). Macro-anatomical Investigations on the Plexus Lumbosacralis of the Aksaray Malakli Dog. *Iranian Journal of Veterinary Medicine*, 18(1), 43-50. <http://dx.doi.org/10.32598/ijvm.18.1.10045433>

doi <http://dx.doi.org/10.32598/ijvm.18.1.10045433>



ABSTRACT

Background: In this study, cadavers of 5 adult Aksaray Malakli breed dogs were used to examine the structure of the lumbosacral plexus, which provides innervation of the hindlimb and pelvic region.

Objectives: This study aimed to determine the nerve root composition of the lumbosacral plexus, determine the branching patterns, map the nerve directions macro-anatomically, and collect data for future comparisons with similar breeds.

Methods: The corpses were kept in a formaldehyde pool (10%) for 14 days. After this period, the anatomical area was dissected using appropriate techniques to identify the lumbosacral plexus nerves and roots. The course and origin of the nerves forming the plexus were identified and photographed.

Results: In all 5 cadavers, the lumbosacral plexus originated from the L4-S3 nerves. The plexus comprised n. ischiadicus, n. tibialis, n. obturatorius, n. femoralis, n. saphenous, n. pelvini, n. pudendus, n. cutaneus femoris caudalis, n. peroneus communis, and n. gluteus caudalis.

Conclusion: It was determined that n. femoralis was formed from the ventral branches of the L4 and L5 nerves and the cranial branch of the L6 nerve. N. obturatorius originated from the caudal branch of L5 and the ventral branch of L6. It was determined that n. ischiadicus originated from the L6 caudal, L7 and ventral branch of S1 nerves. The femur branched into n. tibialis and n. peroneus communis (n. fibularis) at the level of extremitas distalis.

Keywords: Carnivor, Nerve, Breed, Dog, Anatomy

Article info:

Received: 18 Aug 2023

Accepted: 13 Oct 2023

Publish: 01 Jan 2024

* Corresponding Author:

Muhammet Alperen Fidan

Address: Department of Veterinary Anatomy, Faculty of Veterinary Medicine, Aksaray University Aksaray, Turkey.

Phone: +90 (538) 7291370

E-mail: alperenfidan1071@gmail.com

Introduction

Aksaray Malakli dog is the most recognized dog breed among the Karabaş and the Sivas Kangal breeds. It is frequently bred in Aksaray, Nevşehir, and Şereflikoçhisar regions of Central Anatolia (Atasoy et al., 2014; İlgün et al., 2022; İlgün & Özüdoğru, 2020). Structurally, it is distinguished from Sivas Kangal dogs by its larger body size, shorter coat, and straighter tail. Malakli dogs have black spots on the head (Karabaş), taupe-colored hair, and a huge lip and muzzle. It is known by the word “malakli,” which means “cheeky,” especially because of its large and drooping cheeks. It has been reported that the plexus lumbosacralis consists of L5-S3 nerves in dogs (El-Gendy et al., 2021; Dursun, 2000), L4-S1 in cats (Ghoshal, 1972), L4-S3 in Van cat (Nur et al., 2021), L5-S2 in Pampas fox and Crabby fox (Lorenzão et al., 2016), and L5-S3 in Brazilian fighting fox (De Carvalho Barros et al., 2019). de Oliveira Lacerda et al. (2006) stated a difference of opinion in the literature about the nerves originating from the plexus lumbosacralis. Sisson et al. (1975) considered the plexus lumbalis and plexus sacralis structures differently and stated they were not together. Lahunta and Habel (1986) reported that the plexus lumbosacralis consists of n. femoralis, n. obturatorius, and n. ischiadicus in domestic animals (Lahunta & Habel, 1986). Dyce et al. (2009) argued that n. femoralis, n. obturatorius, n. cutaneus femoris caudalis, n. ischiadicus, n. gluteus cranialis, and n. gluteus caudalis nerves in the pelvis originate from the plexus lumbosacralis.

In recent years, studies on dogs have been conducted on sperm cells (Yousef et al., 2022), vaccines (Esmacili et al., 2021), intestinal parasites (Ola-Fadunsin et al., 2023), serum concentrations of hormones (Mosallanejad et al., 2021), and canine distemper virus (Mohtahedzade et al., 2023). In previous studies, it was observed that the plexus lumbosacralis was studied in species such as Van cat (Nur et al., 2021), fox (De Carvalho Barros et al., 2019), Baladi breed dog (El-Gendy et al., 2021), sparrowhawk (Balkaya & Ozudogru, 2016), merlin (Akan et al., 2019), puma (Londoño-Osorio et al., 2020), and helmeted guineafowl (Nilgun & Ismail, 2021). However, no study has been done on plexus lumbosacralis in Aksaray Malakli breed dogs.

The macro-anatomical findings obtained in this study will be helpful in terms of anatomical visualization of the operation area in surgical interventions as well as creating a literature covering all species in the field of basic sciences (Izturov et al., 2022; Abed et al., 2022).

For this reason, it is essential to examine the plexus lumbosacralis in the Aksaray Malakli breed to contribute to the comparative anatomy literature. This research aimed to determine the roots of the nerves in forming the plexus lumbosacralis, determine the course of branching the nerve course macro-anatomically, and obtain data that can be used compared with similar breeds.

Materials and Methods

The study used cadavers of 5 adult Aksaray Malakli dogs, 3 males and 2 females. They were brought to Aksaray University, Faculty of Veterinary Medicine Animal Hospital between 2019 and 2022 by Aksaray Malakli dog breeders in the Aksaray region. They died due to various reasons. Male Aksaray Malakli dog cadavers were aged between 2.5 and 3.5 years and weighed 58.40 kg, 64.75 kg, and 67.20 kg. Female dog cadavers were aged between 2.5 and 4 years and weighed 52.60 kg, 55.50 kg, and 56.70 kg. The cadavers were kept in a formaldehyde pool (10%) for 14 days. After this period, they were dissected. To reveal the structure of the plexus lumbosacralis on both sides, all muscles and the fatty tissue covering the nerve network were removed. An electric saw, 14, 15, and 22 numbered scalpels, homeostatic, and forceps were used during dissection. The area was washed with distilled water to clean it and obtain a clearer image. The os coxae bone was then divided into two parts on the right and left through the symphysis pelvina. The muscles over the coxae joint were dissected, and the course and origin of the nerves forming the plexus lumbosacralis were visualized.

After revealing the source of the nerves, dissection was performed in the proximodistal direction. Following the dissection of the thickest and main nerve groups originating from the nerve roots, the course of the nerves distributed from these branches and their distribution to the points were shown. *Nomina Anatomica Veterinaria* (2017) was based on the software of terminological expressions.

Results

In all of the cadavers used in the study, it was determined that the plexus lumbosacralis originated from L4-S3 (Figures 1 and 4). Plexus lumbosacralis comprised n. ischiadicus, n. tibialis, n. obturatorius, n. femoralis, n. saphenous, n. pelvini, n. pudendus, n. cutaneus femoris caudalis, n. peroneus communis, and n. gluteus caudalis (Figures 1, 2, 3 and 4). N. cutaneus femoris lateralis was seen to originate from the ventral extension of L4. It continued caudally parallel to the medulla spinalis. N.

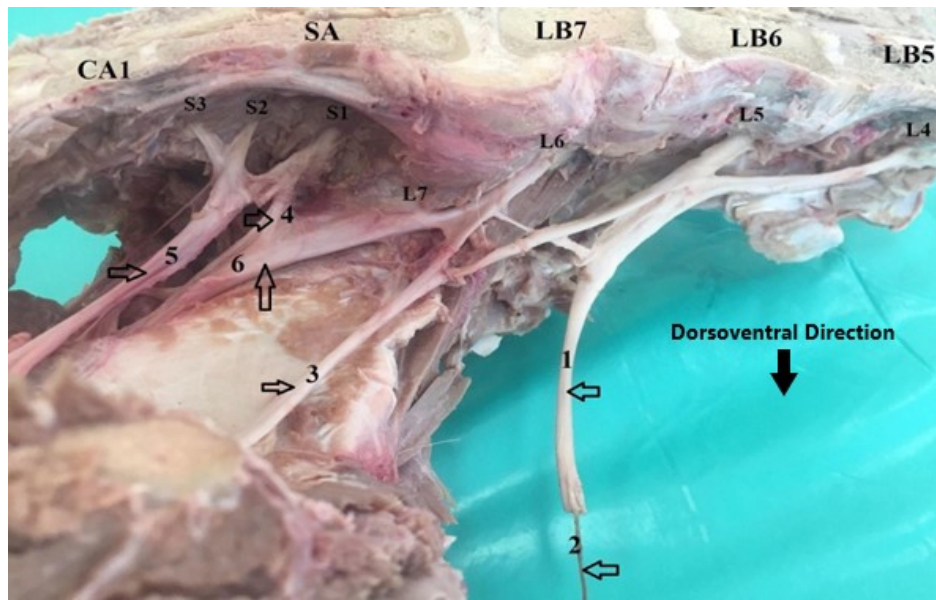


Figure 1. Mediolateral view from the dissected plexus lumbosacralis in an Aksaray Malakli dog

Notes: L4, L5, and L6 form n. femoralis (1) and n. saphenous (2), L5 and L6 branches form n. obturatorius (3), S1 and S2 form n. pelvini (4). N. pudendus (5) originated from S1, S2, and S3. N. ischiadicus (6) originated from L6, L7, and S1 branches.

CA1: The first caudal vertebra; SA: Sacrum; LB7: The seventh lumbar vertebra; LB6: The sixth lumbar vertebra; LB5: The fifth lumbar vertebra.

cutaneous femoris lateralis nerve innervates the skin and fascia around the femur bone (Figure 4). It was observed that the n. femoralis was formed by the branches of L4, L5, and L6. The ventral branches of L4 and L5 and the cranial branch of L6 formed the n. femoralis, which provides innervation of the m. quadriceps femoris and mm. iliopsoas muscles (Figures 1 and 4). It was determined that n. saphenous originated from L4, L5, and L6. Also, it is located as an extension of n. femoralis after the pelvic level. N. saphenous innervates the m. sartorius muscle (Figure 1). It was determined that n. obturatorius originated from the caudal branch of L5 and the ventral branch of L6. It continued its caudomedial course by passing through the foramen obturatum. After exiting the foramen obturatum, it terminated by expanding into the muscles in the region. N. obturatorius innervates the muscles medial to the femur: M. pectineus, m. gracilis, m. adductor, m. obturatorius externus and m. obturatorius internus (Figure 1 and 5). N. pelvini originated from the sacral nerves S1 and S2. The ventral branch of S1 and the cranial branch of S2 participated in the formation of the n. pelvini. Its course from the sacrum ventrally terminated at the level of the ala ossis ilii (Figure 1). N. pudendus originated from the caudal branch of S1 and ventral branches of S2 and S3. It started from the sacrum and traveled caudally, dividing into small branches at the level of the n. cutaneus femoris caudalis and terminating after giving extensions to the muscles. It provides

innervation of m. levator ani, m. bulbospongiosus, m. Ischiocavernosus, and m. sphincter urethrae muscles (Figure 1). N. ischiadicus originated from the caudal branch of the sixth lumbar nerve, the ventral branches of the seventh lumbar nerve, and the first sacral nerve. It started ventral of the sacrum at the level of ala ossis ilii and traveled distally from the ventral aspect of the first caudal vertebra over the facies glutea of the os ilium. At the level of the extremitas distalis of the femur, this nerve gave branches as the n. tibialis and n. peroneus communis (n. fibularis). N. ischiadicus innervates the muscles of m. biceps femoris and m. semitendinosus, which have an essential function in the movement of the hind leg (Figures 1, 2 and 3). It was observed that n. cutaneus femoris caudalis consists of L6 caudal and L7-S1 ventral branches. It traveled caudal to n. ischiadicus and terminated at the level of m. biceps femoris and m. semitendinosus muscles. The skin of the tuber ischiadicum is supplied by the n. cutaneus femoris caudalis (Figure 2). It was observed that n. gluteus caudalis was a nerve originating from the plexus sacralis. It was determined to comprise a caudal branch of S1 and the ventral branches of S2 and S3. After separating from the plexus sacralis, it was directed towards the caudodorsal aspect of the hind leg and terminated by adhering to the muscles in this region. This nerve innervates m. gluteus superficialis, cranial part of m. biceps femoris and m. glutofemoralis muscles (Figure 2). N. tibialis was formed from the cau-

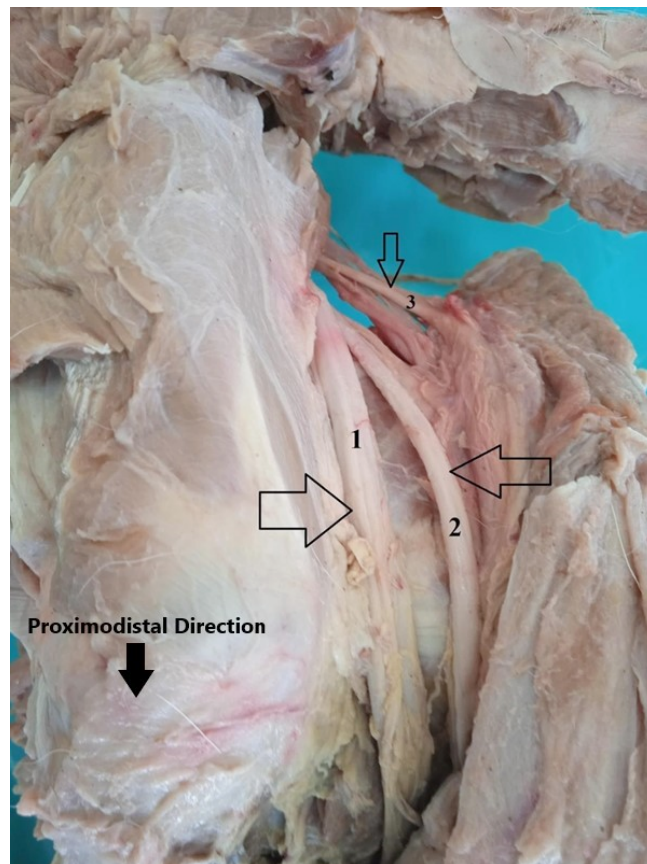


Figure 2. Lateromedial view from the dissected plexus sacralis and n. ischiadicus in an Aksaray Malaklı dog

N. ischiadicus (1) runs distally. N. cutaneus femoris caudalis (2) runs parallel to the ischiatic nerve (1). N. gluteus caudalis (3) goes caudally.

dal branch of L6 and ventral branches of L7-S1. It was observed that n. tibialis was formed by the branching of n. ischiadicus around the distal end of the extremitas distalis of the femur. It ran parallel to the n. peroneus communis. This nerve innervates the m. gastrocnemius, m. flexor digitorum superficialis and profundus, m. tibialis caudalis, m. soleus, m. digitorum brevis muscles, m. digitorum longus, and tarsal joint (Figure 3). N. peroneus communis (n. fibularis) was formed from the caudal branch of L6 and ventral branches of L7-S1. N. peroneus communis ran parallel to the n. tibialis, cranial to this nerve. N. peroneus communis is divided into 2 branches as superficialis and profundus. The branches of this nerve innervate the m. fibularis longus and m. fibularis brevis muscles (Figure 3).

Discussion

This study explored the structure and course of the plexus lumbosacralis of the Aksaray Malaklı dog. According to the literature, the plexus lumbosacralis originates from the last 4 lumbar nerves and S1 nerve roots

(Ghoshal, 1972), L4-S3 (Hudson & Hamilton, 2017), or L3-S3 (Bennett, 1976). This study observed that the plexus lumbosacralis was formed by branches originating from L4-S3 roots. The nerve roots forming the plexus lumbosacralis are in the same direction as those mentioned by Dursun (2000). However, in this study, the nerve roots forming the plexus lumbosacralis were determined to be in the form of L4-S3 nerve roots, different from the L5-S3 nerve roots in the research article of El-Gendy et al. (2021) on Baladi breed dogs. In previous studies, it was reported that the n. cutaneus femoris lateralis nerve is formed by the ventral branch of L4 and branches to the lumbar muscles (Konig & Liebich, 2004). In addition, in a study on the Van cat, it was reported that the n. cutaneus femoris lateralis is formed by the ventral branches of the L4 or L4-L5 and does not branch to the lumbar muscles (Nur et al., 2021). In all of the cadavers examined in this study, it was observed that the n. cutaneus femoris lateralis nerve originated from L4 but did not branch to the lumbar muscles.




Figure 3. Lateromedial view from the dissected n. ischiadicus (1), n. tibialis (2), and n. peroneus communis (n. fibularis) (3) in an Aksaray Malaklı dog

Note: N. tibialis (2) and n. peroneus communis (3) originated from n. ischiadicus (1), both nerves run in parallel and distally.

In the literature, it has been reported that the n. gluteus caudalis nerve consists of L6-S1 or S1-S2 nerves (Barone & Bortolami, 2004; Crouch, 1969; Nur et al., 2021). In the cadavers used in this study, it was determined that the n. gluteus caudalis nerve originated from S1-S2 and S3 nerve roots. In cats, n. pudendus originates from S2-S3 (Reighard & Jennings, 1951) or ventral branches of S1, S2, and S3 (Dyce et al., 2009; Nur et al., 2021).

In this study, as reported by Nur et al. (2021), the n. pudendus was found to be formed from the ventral branches of the S1, S2 and S3 nerves. In the literature, it has been reported that the n. femoralis originates from L5-L6 (Ghoshal, 1972) or L4-L6 (Dursun, 2000). This study determined that L4-L5 and L6 branches were involved in the structure of the n. femoralis, which continued its course distally by giving the n. saphenous branch.

Müller stated that n. obturatorius originates from the ventral branches of L5 and L6, and L4 also participates in the structure of n. obturatorius. Müller (1987) also stated that the n. obturatorius divides after passing through the foramen obturatum. In this study, it was ob-

served that the n. obturatorius originated from L5 and L6 and branched at the level of the foramen obturatum.

In most studies, the n. femoralis is reported to originate from L5-L6 (Crouch, 1969) or L4-L6 (Nur et al., 2021; Dursun, 2000). The findings in this study showed that the n. femoralis originated from the L4-L6, in line with the authors. In addition, the n. femoralis continues its distal course by giving the n. saphenous branch.

According to the literature, the n. ischiadicus consists of L6-S1 (Kumar, 2015), L5-S1 (De Risio & Platt, 2010), L6-S2 (Bennett & Vaughan, 1976), or L7-S2 (Dursun, 2000). In this study, it was determined that the n. ischiadicus nerve is the thickest nerve in the plexus lumbosacralis and consists of L6-L7-S1. In addition, n. ischiadicus divides into two branches as n. tibialis and n. peroneus communis at the extremitas proximalis level of the tibia after the extremitas distalis of the femur.

Conclusion

Studies have reported different information regarding the nerves involved in the structure of the plexus lum-

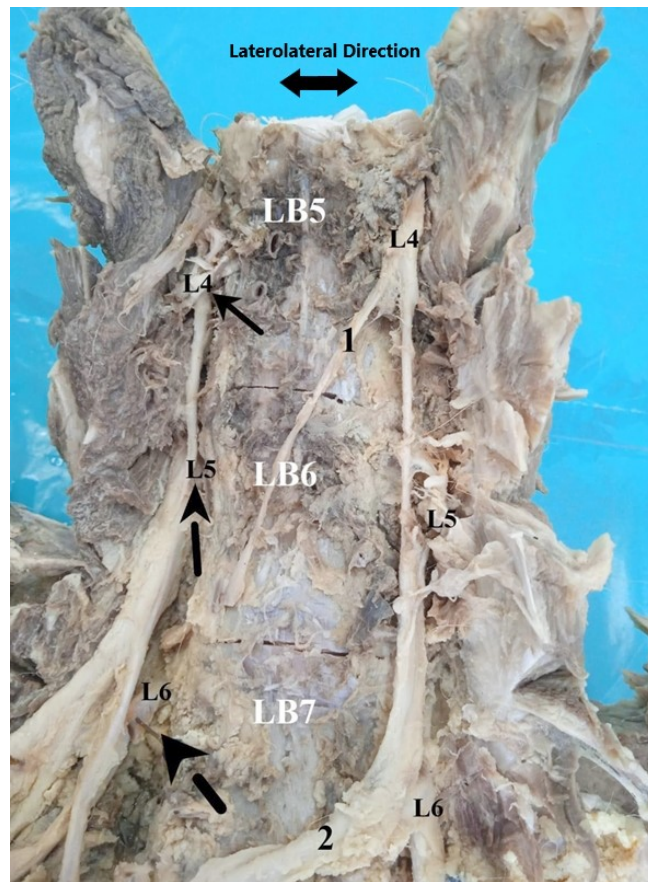


Figure 4. Ventrodorsal view from the columna vertebralis in an Aksaray Malaklı dog
N. cutaneous femoris lateralis (1) runs caudally, N. femoralis goes distally.

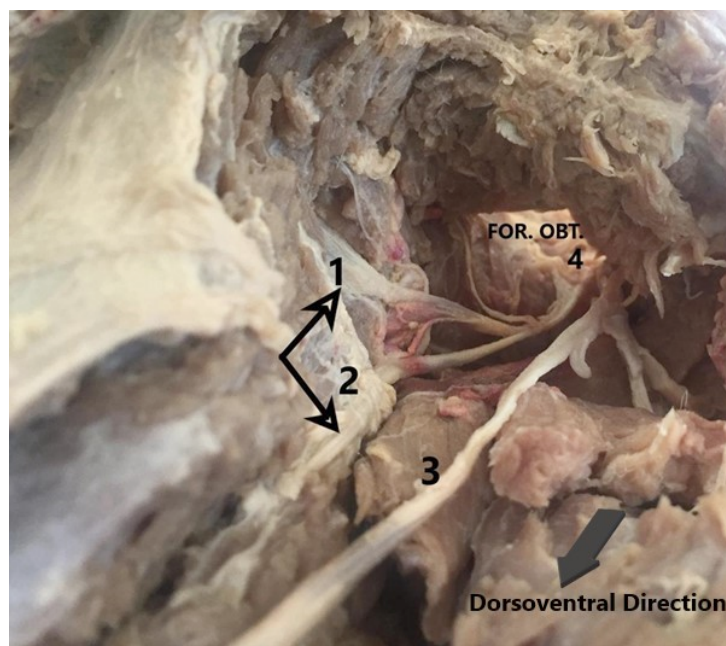


Figure 5. Ventral view from the N. Obturatorius and Foramen Obturatum (4)
Branches from n. obturatorius (1, 2) to the mm. adductor and m. pectineus together branches from n. obturatorius (3) sticks to the m. gracilis.

bosacralis and the nerve extensions formed by the nerve roots in dogs. Nerve injuries due to traumatic, idiopathic, and neuropathic causes are quite common in dogs and cats. These nerve injuries can have serious adverse effects on vital activities, and their damages can be permanent. Especially, n. ischiadicus injuries and damages affect hindlimb innervation severely. For these reasons, it is clinically important to know the nerve locations and the muscles innervated by the nerves. Accordingly, in this study, a macro-anatomical examination of the plexus lumbosacralis was performed on the Aksaray Malakli dog, and the findings obtained from previous studies were analyzed comparatively. As a result of the findings, it was determined that the plexus lumbosacralis consists of L4-S3 nerve roots. In addition, the muscles innervated by the nerve extensions and their course were examined, and data that will form the basis for future studies were provided.

Ethical Considerations

Compliance with ethical guidelines

The study was carried out by [Aksaray University Animal Experiments Local Ethics Committee](#) (No.: 50, dated 05.12.2022).

Funding

This research did not receive any grant from funding agencies in the public, commercial, or non-profit sectors.

Authors' contributions

Conceptualization, methodology, software, verification, formal analysis: Ramazan İlgin; Research, sources, data curation, writing, manuscript preparation, visualization: Muhammet Alperen Fidan. Review and regulation, audit, project management: Zekeriya Özüdoğru;

Conflict of interest

The authors declared no conflict of interest.

References

- Abed, R. A., Nazht, H. H., & Omar, R. A. (2022). Limb gait score of femur fracture fixated by intramedullary pinning in dogs. *Archives of Razi Institute*, 77(3), 1027-1032. [DOI:10.22092/ARI.2022.357386.2026]
- Akalan, M. A., Demirkan, A. C., Türkmenoğlu, İ., & Demirkan, I. (2019). Macroanatomic structure of spinal nerves forming the plexus lumbosacralis in the Merlin (*Falco columbarius*). *Veterinary Sciences and Practices*, 14(1), 15-22. [DOI:10.17094/ataunivbd.390820]
- Atasoy, F., Erdoğan, M., Özarslan, B., Yüceer, B., Kocakaya, A., & Akçapınar, H. (2014). Some morphological and genetic characteristics of Malaklı Karabash dogs. *Ankara Üniversitesi Veteriner Fakültesi Dergisi*, 61(2), 125-132. [DOI:10.1501/Vet-fak_0000002616]
- Balkaya, H., & Ozudogru, Z. (2016). Macroanatomical aspects of the lumbar plexus and its branches in the sparrowhawk. *Anatomia, Histologia, Embryologia*, 45(1), 67-72. [DOI:10.1111/ah.12172] [PMID]
- Barone, R., & Bortolami, R. (2004). [Comparative anatomy of domestic mammals: central nervous system. Neurology I. (French). Vigot, Paris. [Link]
- Bennett, D., & Vaughan, L. C. (1976). The use of muscle relocation techniques in the treatment of peripheral nerve injuries in dogs and cats. *Journal of Small Animal Practice*, 17(2), 99-108. [DOI:10.1111/j.1748-5827.1976.tb06579.x]
- Bennett, D. (1976). An anatomical and histological study of the sciatic nerve, relating to peripheral nerve injuries in the dog and cat. *The Journal of Small Animal Practice*, 17(6), 379-386. [DOI:10.1111/j.1748-5827.1976.tb06974.x] [PMID]
- Bennett, D., & Vaughan, L. C. (1976). The use of muscle relocation techniques in the treatment of peripheral nerve injuries in dogs and cats. *The Journal of Small Animal Practice*, 17(2), 99-108. [DOI:10.1111/j.1748-5827.1976.tb06579.x] [PMID]
- Crouch, J. E. (1969). "Text-atlas of cat anatomy." Philadelphia: Lea & Febiger. [Link]
- David Ola-Fadunsin, S., Bisola Abdulrauf, A., Ganiyu, I., Hus-sain, K., Motunrayo Ambali, H., & Elelu, N. (2023). The intensity of infection and public health perception of potentially zoonotic intestinal parasites of dogs in Kwara Central, Nigeria. *Iranian Journal of Veterinary Medicine*, 17(2), 119-128. [DOI:10.32598/IJVM.17.2.1005295]
- de Carvalho Barros, R. A., Leonel, L. C. P. C., de Carvalho Souza, C. E., de Oliveira, L. P., de Oliveira, T. S., & de Oliveira Silva, D. C., et al. (2019). Anatomy of lumbosacral plexus in hoary fox (*Lycalopex vetulus*-LUND, 1842). *International Journal of Advanced Engineering Research and Science*, 6(3), 197-201. [DOI:10.22161/ijaers.6.3.25]
- de Oliveira Lacerda, P. M., de Moura, C. E. B., Miglino, M. A., de OLIVEIRA, M. F., & de Albuquerque, J. F. G. (2006). Origem do plexo lombossacral de mocó (*Kerondo rupestris*). *Brazilian Journal of Veterinary Research and Animal Science*, 43(5), 620-628. [DOI:10.11606/issn.1678-4456.bjvras.2006.26570]
- De Risio, L., & Platt, S. R. (2010). Fibrocartilaginous embolic myelopathy in small animals. *The Veterinary Clinics of North America. Small Animal Practice*, 40(5), 859-869. [DOI:10.1016/j.cvs.2010.05.003] [PMID]
- Dursun, N. (2000). Veterinary anatomy III. Ankara: Medisan Yayınevi.
- Dyce, K. M., Sack, W. O., & Wensing, C. J. G. (2009). *Textbook of veterinary anatomy-E- Book*. Amsterdam: Elsevier Health Sciences. [Link]

- El-Gendy, S., Alsafy, M., Hanafy, B., Karkoura, A., & Enany, E. S. (2021). Morphology, ultrasonographic and computed tomography configuration of the dog pelvis and perineum. *Anatomia, Histologia, Embryologia*, 50(1), 114-127. [DOI:10.1111/ahe.12608] [PMID]
- Esmaili, H., Mahdavi, A. S., & Hamed, M. (2021). Efficacy of Rev-1 Vaccine against brucella melitensis infection in dog. *Iranian Journal of Veterinary Medicine*, 15(4), 387-394. [DOI:10.22059/IJVM.2021.309899.1005126]
- Ghoshal, N. (1972). The lumbosacral plexus (plexus lumbosacralis) of the cat (*Felis domestica*). *Anatomischer Anzeiger*, 131(3), 272-279. [PMID]
- Hudson, L., & Hamilton, W. (2017). *Atlas of feline anatomy for veterinarians*. New York: CRC Press. [DOI:10.1201/9781315137865]
- Izturov, B. Z., Abilmazhinov, M. T., & Tsoi, O. G. (2022). Acquired Hallux Varus. etiology, pathology, classification, and treatment algorithm. Literature review. *Archives of Razi Institute*, 77(6), 2037-2048. [DOI:10.22092/ARI.2022.360055.2537]
- İlgün, R., & Özüdoğru, Z. (2020). "Macroanatomical and morphometric investigation of mandibula in aksaray malaklı dogs." *Van Veterinary Journal*, 31(1), 7-11. [DOI:10.36483/vanvetj.540404]
- İlgün, R., Özüdoğru, Z., Karabulut, O., & Can, M. (2022). Macroanatomical and morphometric study on the skull bones of Aksaray Malaklı dogs. *Folia Morphologica*, 81(1), 157-163. [DOI:10.5603/FM.a2021.0011] [PMID]
- Konig, H., & Liebich, H. (2004). *Veterinary anatomy of domestic animals. Textbook and color atlas*. Schattauer Verlag, Stuttgart: 495-497. [Link]
- Kumar, M. A. (2015). *Clinically oriented anatomy of the dog and cat*. New York: Linus Learning. [Link]
- Lahunta, A. D., & Habel, R. E. (1986). *Applied veterinary anatomy*. Philadelphia: WB Saunders. [Link]
- Londoño-Osorio, A., Ceballos, C. P., & Tamayo-Arango, L. J. (2020). Anatomical description of the origin and distribution of the lumbosacral plexus in one puma (*Puma concolor*). *Anatomia, Histologia, Embryologia*, 49(4), 575-580. [DOI:10.1111/ahe.12571] [PMID]
- Lorenzão, C. J., Zimpel, A. V., Novakoski, E., da Silva, A. A., & Martinez-Pereira, M. A. (2016). Comparison of the lumbosacral plexus nerves formation in pampas fox (*pseudalopex gymnocercus*) and crab-eating fox (*cerdocyon thous*) in relationship to plexus model in dogs. *Anatomical Record (Hoboken, N.J. : 2007)*, 299(3), 361-369. [DOI:10.1002/ar.23304] [PMID]
- Mojtahedzade, S. M., Jamshidi, S., Ghalyanchi Langeroudi, A., Vahedi, S. M., Ashrafi tamai, I., & Akbarein, H., et al. (2023). Molecular Detection of Canine Distemper Virus among Dogs Showing Neurologic and Non-Neurologic Forms of Disease. *Iranian Journal of Veterinary Medicine*, 16(2), 166-177. [DOI:10.22059/IJVM.2022.346320.1005294]
- Mosallanejad, B., Gooraninejad, S., Rezaee, A., Fatemi Tabatabaei, S. R., Imani Rastabi, H., & Salmani, S. (2021). The effects of stanozolol and nandrolone decanoate hormones on erythropoietin and testosterone serum concentrations in dogs. *Iranian Journal of Veterinary Medicine*, 15(3), 325-334. [DOI:10.22059/IJVM.2020.307743.1005116]
- Müller, R. S. (1987). [Makroskopisch-Anatomische Untersuchungen zum Plexus lumbosacralis der Katze (German)]' [PhD dissertation]. München: Ludwig Maximilian University of Munich. [Link]
- Nilgun, K., & Ismail, T. (2021). Anatomic investigation of the lumbosacral plexus of the helmeted guinea fowl (*Numida meleagris*). *Anatomia, Histologia, Embryologia*, 50(2), 240-249. [DOI:10.1111/ahe.12621] [PMID]
- Nur, I. H., Pérez, W., König, H. E., & Linton, A. (2021). Origin and distribution of the lumbosacral plexus anatomy in van cats. *International Journal of Morphology*, 39(3), 848- 857. [DOI:10.4067/S0717-95022021000300848]
- Reighard, J., & Jennings, H. S. (1951). *Anatomy of the cat*. New York, Henry Holt and Company.
- Sisson, S., Grossman, G. D., & Getty, R. (1975). *Sisson and grossman's the anatomy of the domestic animals*. Philadelphia: Saunders. [Link]
- World Association of Veterinary Anatomists, International Committee on Veterinary Gross Anatomical Nomenclature., & World Association of Veterinary Anatomists. (2017). *Nomina anatomica veterinaria*. Oslo: Editorial Committee. [Link]
- Yousef, A., Ghasemzadeh-Nava, H., Tajik, P., Akbarinejad, V., & Towhidi, A. (2022). Evaluation of soy lecithin efficacy in comparison with egg yolk on freezing of epididymal sperm in dogs. *Iranian Journal of Veterinary Medicine*, 16(2), 166-177. [DOI:10.22059/IJVM.2021.329603.1005191]