

Research Article

Effect of Oxidative Stress on Histological and Immunohistochemical Changes in Testes of Albino Mice



Liqaa Hussain AlDulaimi*

Department of Biology, College of Education for Girls, University of Mosul, Mosul, Iraq.



How to Cite This Article AlDulaimi LH. (2024). Effect of Oxidative Stress on Histological and Immunohistochemical Changes in Testes of Albino Mice. *Iranian Journal of Veterinary Medicine*, 18(2), 187-194. <http://dx.doi.org/10.32598/ijvm.18.2.1005459>

<http://dx.doi.org/10.32598/ijvm.18.2.1005459>

**ABSTRACT**

Background: Fertility in male animals is an important issue in veterinary medicine. Exposure to severe crowding and fattening may affect the fertility of these animals.

Objectives: This study compares the effect of oxidative stress caused by overcrowding or obesity on testicular tissue in male albino mice.

Methods: A total of 30 male mice were divided into 3 groups. The first was a control group. The second group was subjected to crowding by cramming 20 mice in a small cage. The third group was fattened by eating a high-fat diet. Morphometric cells and histological measurements of the seminiferous tubule diameter, epithelium thickness, and Sertoli and Leydig cell counts were taken.

Results: The crowding group testes showed the presence of necrosis and degeneration of spermatocytes, Sertoli, and Leydig cells. The obese group's spermatocytes, Sertoli, and Leydig cells had shown severe necrosis, degeneration, and giant cell invasion. Histomorphometric measurements of seminiferous tubule diameter, epithelium-thickness, and Sertoli and Leydig cell counts revealed a considerable reduction in the obese group compared to the other groups. Furthermore, in the crowding and fattening groups, measurements of oxidative stress indicators revealed a decrease in glutathione value in the obese group compared to the control, whereas malondialdehyde rose in the overcrowded and obese groups compared to the control. The results of the immunohistochemical expressions for tumor necrosis factor- α (TNF- α) in the testes of mice revealed weak TNF- α positive expression in the control group, moderate expression in the crowding group, and strong expression in the obesity group.

Conclusion: The study suggests that both obesity and crowding can impair testicular function, with obesity having the most significant impact. More research into the mechanisms underlying these effects, as well as potential interventions to improve testicular function in obese or overcrowded animals, is required.

Keywords: Mice, Pathological changes, Stress, Testis, Tumor necrosis factor- α

Article info:

Received: 06 Nov 2023

Accepted: 07 Jan 2024

Publish: 01 Apr 2024

*** Corresponding Author:**

Liqaa Hussain AlDulaimi

Address: Department of Biology, College of Education for Girls, University of Mosul, Mosul, Iraq.

Phone: +96 (47) 709954437

E-mail: liqaaladulaimi@uomosul.edu.iq

Introduction

Oxidative stress occurs when the body's natural balance between the oxidative and antioxidant states is disrupted. In other words, when the percentage of free radicals increases extensively, it damages cellular components, such as membranes, proteins, and nucleic acids (Sies & Jones, 2017; Zhang et al., 2021b; Alnuaimi et al., 2023). The testicle is one of the most vulnerable organs to external and or internal stress. Internal stress happens when the testicular tissue is exposed to free radical attack for any reason. These free radicals affect the seminiferous tubules, Leyden cells, and blood vessels (Agarwal & Sharma, 2021; Wu et al., 2022).

The severity of testicular tissue damage depends on the exposure duration and intensity. The longer the exposure period and the greater the intensity of the influencing factor, the more irreversible the effects, such as testicular fibrosis and inflammation, leading to testicular atrophy, low testosterone production, and infertility (Agarwal & Sharma, 2021; Xu et al., 2022).

If the influencing factor is weak or the exposure time is brief, the effect causes minor injury to the testicular tissue and is frequently treatable. Reduced oxidative stress and improved environmental conditions may prevent a detrimental impact on the testicle (Agarwal & Sharma, 2021).

Crowding or overcrowding refers to a scenario in which many people are crammed into a small space, causing psychological tension, anxiety, discomfort, and instability. These challenging conditions are retroflected in the body's internal system, where natural functions are severely impacted, resulting in oxidative stress and tissue damage (Xu et al., 2022; Decerle, 2018).

Animal studies have revealed that obesity has a significant impact on oxidative stress. Obesity is associated with elevated oxidative stress markers and decreased antioxidant defenses in animals (Lee & Choi, 2012; Zhang et al., 2021a). This study aimed to compare the effect of oxidative stress caused by overcrowding and obesity on testicular tissue in male albino mice.

Materials and Methods

Study animals

A total of 30 male albino mice weighing 25-30 g and 3-4 weeks old were used in this study. We maintained the standard breeding conditions: Good hygiene, ventilation,

food, and a 12-hour light/dark cycle. According to the European Parliament, fattening animals were fed a high-fat diet (Decerle, 2018).

Experiment design

The research lasted 30 days, and the mice were divided into 3 groups. The first group consisted of 5 mice as a control group, and the second group was subjected to crowding by cramming 20 mice into a small cage (Zakareya Al-Etreby et al., 2015). The third group of 5 mice was subjected to fattening using a high-fat diet of 30%. After completing the therapy period, 5 animals from each group were anesthetized by ether to draw their blood from the eye socket. The blood was placed in special blood tubes and left to clot for 20 minutes, followed by washing routines.

The organs were preserved in 10% formalin until tissue cutting, and then slides were made and stained with the routine hematoxylin and eosin stain before being examined under a light microscope.

Biochemical test

According to some studies, glutathione and malondialdehyde concentrations were estimated (James et al., 1982; Buege & Aust, 1978).

Micro-morphometric cell counting

The histomorphometric measurements of seminiferous tubule diameter, epithelium thickness, and Sertoli and Leydig cell counting were taken by averaging 5 measurements/field 60.080 m²/400X as 5 fields for every mouse under microscopic examination and using the camera software (U.S.B. 2.00 Calibration of all microscope lenses, Olympus-Toupview-9.00-Megapixel, China) CX310, which supplied calibration line. The immunobiological study was conducted using a kit for measuring tumor necrosis factor- α (TNF- α).

Statistical analysis

The Mean \pm SE were used to describe the obtained data. Also, a one-way Duncan test was performed to analyze the data at a significant level of 0.05.

Results

The weights of mice exposed to fattening showed a substantial increase at the end of the month compared to the rest of the groups. Also, the crowding group showed significant weight loss compared to other groups (Table 1).

Table 1. Body weight of treated groups (n=5 for each group)

Group	Parameter	Mean±SE	
		Body Weight (g) at the Beginning of the Study	Body Weight (g) at the End of the Study
Control		24.14±2.05 ^A	25.14±2.05 ^B
Crowding		25.51±3.16 ^A	22.51±3.16 ^{C, B}
Obesity		24.51±2.21 ^A	38.51±2.2 ^A

^{A, B & C}Significant difference between groups at P≤0.05.

Histological assessments

The control group testes had typical histological structures of the seminiferous tubules, interstitial tissue with Leydig cells, spermatogonia, spermatocytes, spermatids, and Sertoli cells. Necrosis and degeneration of the spermatocytes, Sertoli cells, and Leydig cells in the interstitial tissue were the histopathological changes of the crowding group. The spermatocytes, Sertoli cells, and Leydig cells in the obese group had severe necrosis, degeneration, and an invasion of giant cells (Figure 1).

Histomorphometric measurements of seminiferous tubule diameter, epithelium thickness, and Sertoli and Leydig cell counting in the obese group showed a substan-

tial drop compared to the control and crowding groups, but only the crowding group showed a significant decrease when compared to the control group (Figures 2, 3, 4, and Table 2). These outcomes indicate that obesity and crowding can have a negative impact on testicular function, with obesity having a more significant impact. More investigation is required. Investigate the mechanisms behind these effects and potential interventions to improve testicular health in obese or crowded animals.

The results of the immunohistochemical expressions for TNF-α in the testes of mice revealed weak TNF-α positive expression in the control group, moderate expression in the crowding group, and strong expression in the obesity group (Figure 2).

Table 2. The mean counts of Sertoli, Leydig cells, and the seminiferous tubule diameter (µm) in the study groups' testes (n=5 for each group)

Group	Histological Standard	Mean±SE			P
		Control	Crowding	Obesity	
	Seminiferous tubules' diameter (µm)	291±14.2 ^A	214.6±12.5 ^B	176±8.2 ^C	<0.001
	Epithelium thickness (µm)	84.2±5.1 ^A	48.4±5.7 ^B	31.2±2.9 ^C	<0.001
	Sertoli cell count	5.2±0.5 ^A	3.2±0.3 ^B	1.8±0.3 ^B	<0.001
	Leydig cell count	18.2±1.4 ^A	14.4±0.9 ^B	9.2±1.1 ^C	<0.001

^{A, B & C}Significant difference between groups at P≤0.05.

Table 3. Glutathione and malondialdehyde concentration in treatment groups (n=5 per group)

Parameter	Group	Mean±SE	
		Glutathione (µmole/mL)	Malondialdehyde (µmole/mL)
	Control	13.16±0.05 ^A	3.16±0.05 ^C
	Crowding	12.91±0.16 ^A	5.51±0.16 ^B
	Obesity	10.51±0.21 ^B	7.1±0.21 ^A

^{A, B & C}Significant difference between groups at P≤0.05.

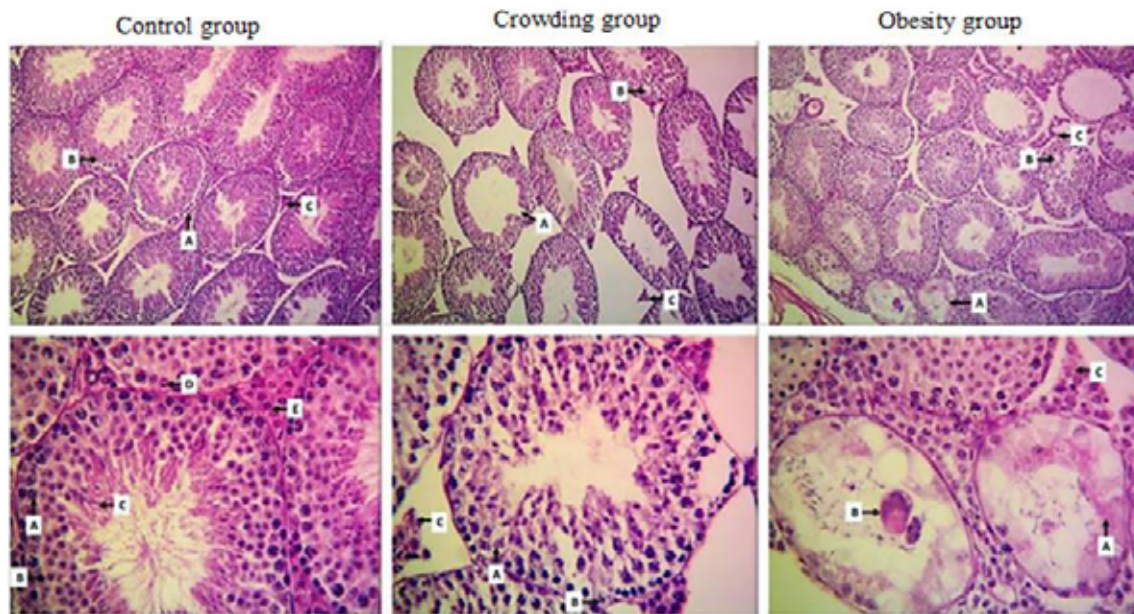


Figure 1. Histology sections taken from a mouse testis

Control group: Seminiferous tubules (A) With spermatogenesis cells (B), and interstitial tissue (C) making up spermatogonia, spermatocytes, spermatids, Sertoli, and Leydig cells make up the lower group (E).

Crowding group (upper): Spermatocytes necrosis and degeneration (A), Sertoli (B), and Leydig cells; (lower): Necrosis and degeneration of spermatocytes (A), degeneration (B), and necrosis of the interstitial tissue (C).

Obesity group (upper): Severe spermatocyte necrosis, degeneration, and necrosis of interstitial tissue; Lower: Severe spermatocyte necrosis, giant cell infiltration, and necrosis of Leydig cells (C).

Note: H&E bleed (upper panel: x100, Lower panel: 400x).

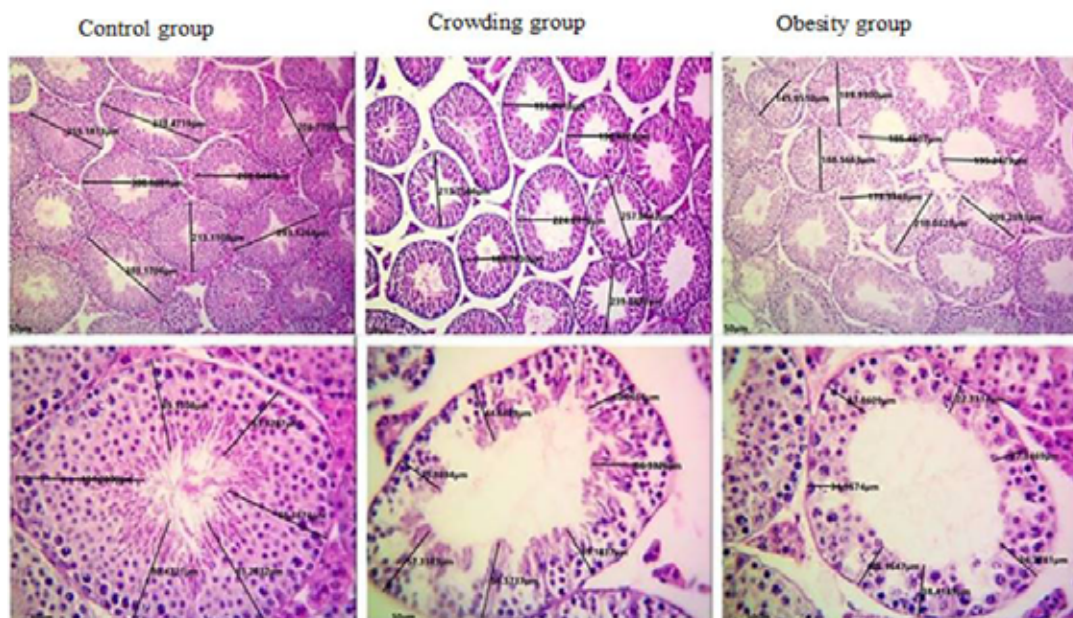


Figure 2. Histological sections of the testes of mice from the control, crowding, and obese groups

Displaying the histomorphometric measurements of the thickness of the epithelium, the number of Sertoli and Leydig cells, the diameter of the seminiferous tubules (upper panel), and the thickness of seminiferous tubules (lower panel).

Toupview application from OMAX; H&E staining (upper panel: 100X, lower panel: x400).

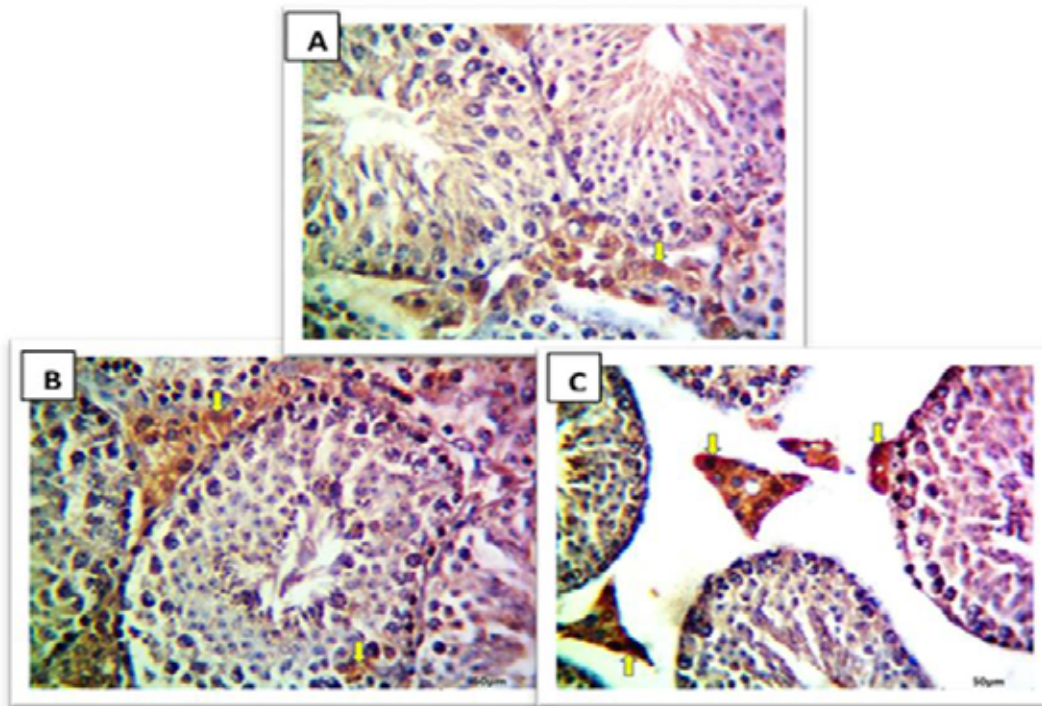


Figure 3. Immunohistochemical expressions for TNF-α in the testes of mice

A) Control group, TNF-α has a weak positive expression (arrow), B) Crowding group, TNF-α has a moderate positive expression (arrow), C) Obesity group, TNF-α has a strong expression (magnification x400)

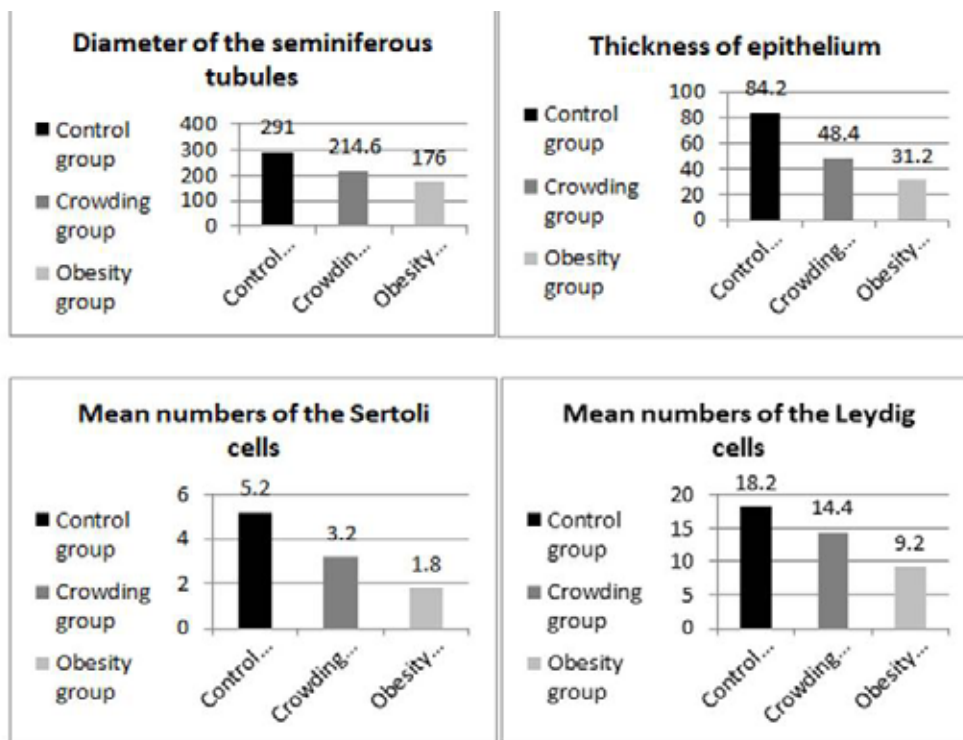


Figure 4. The mean counts of Sertoli and Leydig cells, epithelium thickness (µm), and seminiferous tubule diameters (µm) in the mice testes of the study groups

The results of [Table 3](#) show that the glutathione value decreased significantly in the obesity group compared to the control. In contrast, malondialdehyde rose considerably in the crowding and obesity groups compared to the control group.

Discussion

Oxidative stress has been shown to impact testicular tissue in animal studies significantly. Because of the testes' high metabolic activity, high levels of unsaturated fatty acids in sperm membranes, and relatively low levels of antioxidant defenses, testes are particularly vulnerable to oxidative stress. The mechanisms by which oxidative stress can damage testicular tissue include lipid peroxidation. Oxidative stress can lead to the peroxidation of lipids in sperm cell membranes. This oxidation can damage the sperm cells and decrease their viability. Oxidative stress can also damage sperm DNA, leading to infertility, birth defects, and disruption of spermatogenesis. Finally, oxidative stress can disrupt the process of spermatogenesis, which is the production of sperm. This can lead to a decrease in sperm count and motility ([Agarwal & Sharma, 2021](#)).

Histopathological examination revealed that mice exposed to obesity showed more severe histopathological effects than mice exposed to crowding. According to research, oxidative stress can impair testicular function by harming testicular cells in specific ways. Oxidative stress can damage Leydig cells, which are responsible for producing testosterone. This effect can lead to a decrease in testosterone production and male infertility. Oxidative stress can damage Sertoli cells, which support and nourish sperm cells. This can lead to a reduction in sperm production and quality. Oxidative stress damages germ cells, the precursors of sperm cells. This can lead to a decrease in sperm count and quality and an increase in sperm DNA damage ([Wu et al., 2022](#); [Xu et al., 2022](#)). Oxidative stress can impair testicular function by causing cell damage, resulting in animal testicular dysfunction and infertility ([Alhamdani & Al-Maliki, 2021](#); [Wu et al., 2022](#)).

The results of our study show that exposing rats to stress by crowding caused oxidative stress in the exposed rats, as malondialdehyde increased in their serum. This result is consistent with previous studies that showed crowding can also cause oxidative stress. It can make the body generate reactive oxygen species (ROS), which are extremely reactive chemicals. They can damage cellular structures such as proteins, lipids, and DNA ([Zakareya Al-Etreby et al., 2015](#); [Zhang et al., 2021a](#)).

Furthermore, crowding can lead to increased stress, which has been demonstrated to increase oxidative stress in the body. Psychological stress can stimulate the hypothalamic-pituitary-adrenal axis, adrenal systems, and sympathetic nervous systems, resulting in increased ROS production ([Oka et al., 2021](#)).

It should be noted that the link between oxidative stress and crowding is not a direct relationship and can be altered by personal characteristics such as age, gender, genetics, and pre-existing health issues ([Dutta et al., 2021](#)). It was also discovered that obese mice in our study affected glutathione levels with high malondialdehyde levels. Animal obesity is linked to increased oxidative stress and lowered antioxidant defenses, which may contribute to various health complications ([Khan et al., 2022](#)). According to one published study, obese pigs had higher oxidative stress markers, such as malondialdehyde, and lower levels of antioxidant enzymes, such as superoxide dismutase and catalase, than control pigs. Several hypotheses have been proposed to explain the link between animal obesity and oxidative stress. One process is linked to increased reactive oxygen species ROS formation in obese animals' adipose tissue ([Agarwal & Sharma, 2021](#)).

Obese animals' adipose tissue produces more reactive oxygen species because of enhanced nicotinamide adenine dinucleotide phosphate (NADPH) oxidase activity, mitochondrial dysfunction, and inflammation. Overproduction of ROS can overwhelm antioxidant defenses, resulting in oxidative stress ([Agarwal & Sharma, 2021](#)). Another mechanism associated with obesity is the renin-angiotensin-aldosterone system. It is a complex hormonal system that controls blood pressure and fluid balance. Obesity causes an increase in angiotensin II, a potent vasoconstrictor that can cause oxidative stress by increasing NADPH oxidase activity and decreasing antioxidant enzymes ([Singh & Singh, 2019](#)).

Obesity-induced oxidative stress can also cause genetic changes in animals. Genetic modifications are changes in gene expression unrelated to changes in the DNA sequence. Oxidative stress can trigger epigenetic alterations, such as DNA methylation, histone modifications, and microRNA expression, all of which can alter gene expression patterns and contribute to the development of obesity-related health issues ([Li et al., 2021](#); [Shahsavari et al., 2023](#)). To confirm this effect in our study, we measured tumor necrosis factor, which showed moderate to weak expression in mice exposed to crowding but was stronger in the obese group than in the other groups.

In studies, TNF- α expression in testicular tissue is induced by oxidative stress. Various variables, including environmental pollutants, can produce oxidative stress, smoking, obesity, and certain diseases (Zhang et al., 2021a). TNF- α overexpression caused by oxidative stress can result in testicular injury and decreased sperm function. Therefore, reducing exposure to these factors may benefit male reproductive health. When stressed, testicular tissue produces more ROS, which can stimulate the NF- κ B signaling pathway (nuclear factor kappa-light-chain-enhancer of activated B cells). The TNF- α expression can then be increased because of this pathway (Li et al., 2022; Zigam et al., 2023).

TNF- α expression can set off a chain of events that aggravate oxidative stress in testicular tissue. TNF- α induces a rise in free radical generation and a deficit and depletion of antioxidants, causing an imbalance in the body's natural balance. This issue was demonstrated in this work, where elevated TNF- α expression exacerbates the situation of oxidative stress in the testicles. TNF- α is a pro-inflammatory cytokine released in testicular tissue in response to tissue injury. This release is accomplished by activating NADPH oxidase, the primary cause of testicular oxidative stress. TNF- α also inhibits several antioxidant enzymes, including superoxide dismutase and catalase, increasing the testicular state of oxidative stress (Alnuaimi & Alabdaly, 2023; Al-Abdaly et al., 2023).

Interventions targeting oxidative stress or TNF- α expression may help reduce damage to testicular cells and improve testicular function.

Conclusion

Testicular tissue is susceptible to oxidative stress. It turns out that obesity has a more influential role than overcrowding in causing an increase in oxidants and causing damage and destruction in the testicular tissue. Infertility and other reproductive issues can result from oxidative stress. Maintaining a healthy weight and lifestyle is critical for male reproductive health.

Ethical Considerations

Compliance with ethical guidelines

There were no ethical considerations to be considered in this research.

Funding

This research did not receive any grant from funding agencies in the public, commercial, or non-profit sectors.

Conflict of interest

The author declared no conflict of interest.

Acknowledgments

The author thanks [University of Mosul](#) for its support.

References

- Agarwal, A., & Sharma, R. K. (2021). Oxidative stress and testicular function. *Reprodu Biolo and Endocry*, 19(1), 1-15.
- Al-Abdaly, Y., Younis Alfathi, M., & Al-mahmood, S. S. (2023). Comparison of azithromycin toxicity in chickens and quails. *Iranian Journal of Veterinary Medicine*, 17(4), 321-332. [DOI:10.32598/IJVM.17.4.1005354]
- Alhamdani, M. S., and Al-Maliki, A. S. (2021). Antioxidant supplementation improves testicular function in rats exposed to oxidative stress. *Baghdad Science Journal*, 18(4), 670-677.
- Alnuaimi, S. I., & Alabdaly, Y. Z. (2023). Neurobehavioral toxicity of copper sulfate accompanied by oxidative stress and histopathological alterations in chicks' brain. *Iraqi Journal of Veterinary Sciences*, 37(1), 53-60. [DOI:10.33899/ijvs.2022.133416.2224]
- Sies, H., & Jones, D. P. (2017). Nucleotide excision repair of oxidised genomic DNA is not a source of urinary 8-oxo-7,8-dihydro-2'-deoxyguanosine. *Free Radical Biology & Medicine*, 99, 385-391. [PMID]
- Buege, J. A., & Aust, S. D. (1978). Microsomal lipid peroxidation. *Methods in enzymology*, 52, 302-310. [PMID]
- Chukwu, O. O., Emelike, C. U., Konyefom, N. G., Ibekailo, S. N., Ekakitie, O., & Ghasi, S., et al. (2023). Histological studies of the heart and biochemical changes due to the perinatal consumption of hibiscus sabdariffa (flavonoid-rich extract) to feed-restricted rats on offspring. *Iranian Journal of Veterinary Medicine*, 17(1), 37-46. [DOI:10.22059/IJVM.17.1.1005272]
- Dutta, S., Sengupta, P., Slama, P., & Roychoudhury, S. (2021). Oxidative Stress, Testicular Inflammatory Pathways, and Male Reproduction. *International Journal of Molecular Sciences*, 22(18), 10043. [PMID]
- Decerle, J. (2018). *Report implementation report on on-farm animal welfare*. Strasbourg: European Parliament. [Link]
- James, R. C., Goodman, D. R., & Harbison, R. D. (1982). Hepatic glutathione and hepatotoxicity: Changes induced by selected narcotics. *Journal of Pharmacology and Experimental Therapeutics*, 221(3), 708-714. [Link]
- Khan, N., Liu, Y., Zhang, J., & Zhang, Y. (2022). Oxidative stress and obesity in animals: A review. *Fronti in Vet Scie*, 9, 841028. doi: 10.3389/fvets.2022.841028
- Lee, J., & Choi, J. (2012). Crowding and oxidative stress: A complex relationship. *Current Opinion in Environmental Science & Health*, 1, 1-8.

- Li, J., Liu, Y., Zhang, J., & Zhang, Y. (2022). Person-environment fit and oxidative stress: A systematic review. *Frontiers in Public Health*, *10*, 871975.
- Li, Y., Liu, Y., Zhang, J., & Zhang, Y. (2021). Epigenetic effects of oxidative stress in obesity and obesity-related diseases. *Frontiers in Genetics*, *12*, 680867.
- National Research Council. (2020). *Guide for the care and use of laboratory animals*. Washington: National Academies Press. [\[Link\]](#)
- Oka, S. I., Tang, F., Chin, A., Ralda, G., Xu, X., & Hu, C., et al. (2021). β -Hydroxybutyrate, a ketone body, potentiates the antioxidant defense via thioredoxin 1 upregulation in cardiomyocytes. *Antioxidants*, *10*(7), 1153. [\[DOI:10.3390/antiox10071153\]](#)
- Seyednejad, S. F., Shirani, D., Bokai, S., & Nasiri, S. M. (2023). Evaluation of iron status in cats with hypertrophic cardiomyopathy with and without congestive heart failure. *Iranian Journal of Veterinary Medicine*, *17*(3), 209-216. [\[DOI:10.32598/IJVM.17.3.1005245\]](#)
- Shahsavari, M., Norouzi, P., Kalalianmoghaddam, H., & Teimouri, M. (2023). Effects of Kudzu Root on Oxidative Stress and Inflammation in Streptozotocin-induced Diabetic Rats. *Iranian Journal of Veterinary Medicine*, *17*(4), 401-408. [\[DOI:10.32598/IJVM.17.4.1005281\]](#)
- Singh, U., & Singh, D. (2019). The role of the renin-angiotensin-aldosterone system in obesity-induced oxidative stress and inflammation. *Frontiers in Endocrinology*, *10*, 41.
- Soltani, M., Shafiei, S., Mirzargar, S. S., & Asadi, S. (2023). Probiotic, paraprobiotic, and postbiotic as an alternative to antibiotic therapy for lactococcosis in aquaculture. *Iranian Journal of Veterinary Medicine*, *17*(4), 287-300. [\[DOI:10.32598/IJVM.17.4.1005342\]](#)
- Wu, X., Chen, H., Huang, Y., & Liu, S. (2022). Oxidative stress-induced testicular damage and male infertility: Mechanisms and therapeutic strategies. *AJA*, *24*(6), 567-582.
- Wu, X., Chen, H., Huang, Y., & Liu, S. (2022). Oxidative stress and testicular dysfunction. *Frontiers in Endocrinology*, *13*, 916626.
- Xu, X., Wang, Y., Chen, Z., & Chen, J. (2022). Oxidative stress and testicular cancer. *Frontiers in Oncology*, *12*, 926920.
- Zakareya Al-Etreby, M., Ramadan Samaha, S., Mohamed Mohamed, A., & Shaaban Abdel-Monsef, A. (2015). Effects of crowding and loneliness on liver functions in adult male albino rats. *Al-Azhar Medical Journal*, *44*(3), 225-236. [\[Link\]](#)
- Zhang, Y., Liu, Y., Liu, S., & Zhang, J. (2021). Crowding and oxidative stress: A systematic review. *Frontiers in Public Health*, *9*, 681400.
- Zhang, Y., Liu, Y., Zhang, J., & Zhang, Y. (2021). Oxidative stress and testicular inflammation. *Frontiers in Endocrinology*, *12*, 646763.
- Zigam, Q. A., Al-Zubaidy, A. A., Abbas, W. J., & Al-Mudhafar, R. H. (2023). Cardioprotective Effects of Octreotide against Sepsis-Induced Cardiotoxicity in Mice. *Archives of Razi Institute*, *78*(1), 53-61. [\[DOI:10.22092/ARI.2022.358339.2201\]](#)